

# Reactivated *Moraxella* osteitis presenting as granulomatous disease

P. Sendi<sup>1\*</sup>, R. Meier<sup>2</sup>, B. Sonderegger<sup>1</sup>, H.M. Bonel<sup>3</sup>, S.C. Schäfer<sup>4</sup>, E. Vögelin<sup>2</sup>

Departments of <sup>1</sup>Infectious Diseases, <sup>2</sup>Plastic and Hand Surgery, <sup>3</sup>Diagnostic, Interventional and Paediatric Radiology, University Hospital of Bern and University of Bern, Bern, Switzerland, <sup>4</sup>Institute of Pathology, University of Bern, Bern, Switzerland, \*corresponding author: tel.: +41 31 632 32 99, fax: +41 31 632 87 66, email: parham.sendi@ifik.unibe.ch

## ABSTRACT

Granulomatous infections are commonly associated with mycobacteria, brucellosis, actinomycosis, nocardiosis, spirochetes, and fungi. Rarely, granuloma formation is a host response to other bacterial infection. Osteomyelitis and osteitis that reactivate many years after the primary episode is a known phenomenon. A reactivation that presents as a granulomatous disease is rare. We present a case of reactivated osteitis due to *Moraxella osloensis* with consecutive granuloma formation.

## KEYWORDS

Osteomyelitis, granulomatous disease, *Moraxella osloensis*

## INTRODUCTION

The differential diagnosis for granulomatous disorders is broad.<sup>1</sup> It includes infections, vasculitis, immunological aberrations, leukocyte oxidase defects, hypersensitivity reactions, host response to chemicals, or neoplasia. Granulomatous infections are commonly associated with mycobacteria, brucellosis, actinomycosis, nocardiosis, spirochetes, and fungi.<sup>2</sup> Rarely, granuloma formation is a host response to other bacterial infection. Granuloma formation can also be triggered by osteomyelitis and osteitis. Here, we present a case of reactivated osteitis due to *Moraxella osloensis* that presented as granulomatous disease.

## CASE REPORT

A 51-year-old woman presented with a progressive and slightly painful swelling arising in the soft tissue of her left forearm. She reported neither fever, nor weight loss,

### What was known on this topic?

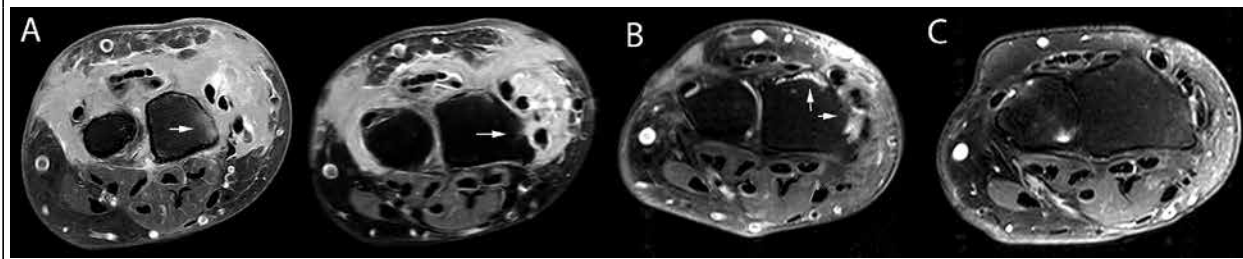
Osteomyelitis that reactivates many years after the primary episode is a known phenomenon. Most reported cases are of *Staphylococcus aureus* as the causative pathogen.

### What does this add?

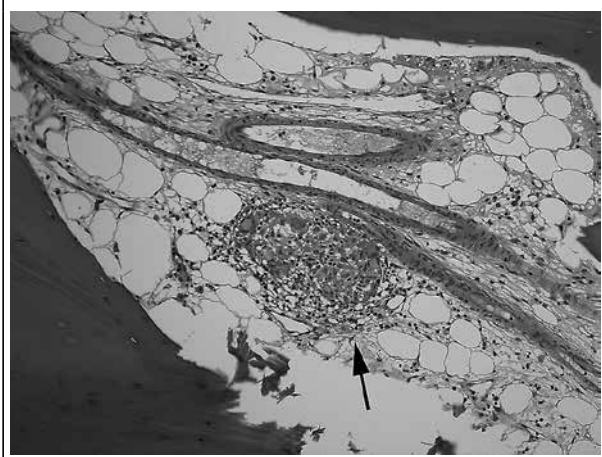
This case is the first description of a reactivated osteitis due to *M. osloensis* triggering extensive granuloma formation. The clinical constellation may be misdiagnosed as musculoskeletal tumour or autoimmune disease. Molecular analyses may be required to identify difficult-to-detect microorganism.

nor other systemic symptoms. Her history included a forearm fracture at the site of the current swelling, 46 years ago (i.e. in her early childhood). She recalled a surgical intervention, but did not remember the type of intervention, hospitalisations, medications, or follow-ups. Magnetic resonance imaging (MRI) showed a tumour surrounding the extensor tendon group, communicating with the cortical bone of the radius (*figure 1A*). Under suspicion of a malignant or myofibroblastic tumour, an incision biopsy was performed. The histopathological analysis did not reveal any signs of malignancy but the presence of granulomas. Culture for bacteria, *Nocardia*, mycobacteria, and fungi were negative. Thus, the 8 x 2 x 1.5 cm tumour was radically excised. The histopathological analysis again showed chronic granulomatous inflammation consisting of epithelioid histiocytes and giant cells surrounded by fibrosis, but without necrosis.

**Figure 1.** Fat-saturated contrast-enhanced T1-weighted magnetic resonance imaging of the left forearm. (A) Soft-tissue tumour mass surrounding the extensor tendon group and communicating with the cortical bone of the radius (arrow), shown at two different levels. (B) Contrast enhancement dorsal and ventral to the radius (arrows), indicating persistent bone inflammation. (C) Follow-up image one year after treatment, showing normal findings



**Figure 2.** Haematoxylin and eosin stain of a bone biopsy (10 x magnification) showing a granuloma in the bone marrow of the radius (arrow)



The granulomas were also found in the cortical bone and adjacent marrow of the radius (figure 2).

Re-evaluation of the findings in view of a possible granulomatous disorder showed neither clinical nor laboratory signs of vasculitis (e.g. no lymphadenopathy, Wegener's, polyarteritis nodosa, systemic lupus erythematosus) or immunological aberrations (e.g. Crohn's diseases, primary biliary cirrhosis, hypogammaglobulinaemia). She denied contact with animals and chemicals. Biopsy sample cultures were negative for bacteria, *Nocardia*, mycobacteria, and fungi, as were multiple molecular analyses for mycobacteria. Serological tests for brucellosis, syphilis and Q fever were negative. The nitroblue tetrazolium dye test was not indicative of a chronic granulomatous disease. Because the finding was histopathologically consistent with an autoimmune disease (e.g. sarcoidosis), treatment with corticosteroids was initiated. After two months, the skin erythema, oedema, and warmth persisted. MRI was repeated and showed periosteal enhancement at the radius, indicative of

persistent bone inflammation (figure 1B). When her history was re-evaluated again, the patient reported a feeling as if the disease was growing from her previous fracture site. Therefore, late reactivation of osteitis with consecutive granuloma formation was a differential diagnosis. Bone samples were reinvestigated with 16S-RNA polymerase chain reaction, revealing *Moraxella osloensis*. Corticosteroid treatment was tapered, and a three-month course with amoxicillin/clavulanate started. The further clinical course was favourable. At the one-year follow-up examination, the patient was symptom-free and MRI showed no evidence of inflammation (figure 1C).

## DISCUSSION

*Moraxella osloensis* is an aerobic, gram-negative coccobacillus. Cases with bacteraemia, catheter-related infections, pneumonia, and meningitis have been reported, mostly in children or in immunocompromised hosts.<sup>3</sup> However, *M. osloensis* can cause osteomyelitis and arthritis.<sup>4</sup> In this patient, it was unclear whether the soft-tissue tumour caused bone erosions or the infection started primarily from the bone. Initially, the bone involvement was overlooked because of the impressive host reaction in the soft tissue. Also, whether or not posttraumatic bone infection occurred in her childhood remains unknown, because no disease documentation from that period was available. However, the patient's history, the sum of all radiological findings, the lack of response to corticosteroids, the identification of a pathogen from a biopsy sample and the favourable course after antimicrobial treatment suggest late reactivation of posttraumatic osteomyelitis due to *M. osloensis*.

Osteomyelitis that reactivates many years after the primary episode is a known phenomenon. Most reported cases are of *Staphylococcus aureus* as the causative pathogen. However, virtually all microorganisms can cause osteomyelitis, and conceivably, reactivate at a later stage

**Table 1.** Reported cases of reactivated osteomyelitis after a long asymptomatic interval

Reference	Gender	Location	Pathogen	Age (years)	
				1 <sup>st</sup> Episode	Reactivation
5	Female	Distal femur	<i>S. aureus</i>	12	62
6	Male	Distal tibia	<i>Salmonella virchow</i>	14	26
7	Male	Distal fibula	<i>S. aureus</i>	11 and 17 <sup>1</sup>	82
8	Male	Lumbar spondylodiscitis	MR <i>S. aureus</i>	28	40
9	Female	Calvarium	<i>P. acnes</i>	49 <sup>2</sup>	72
10	Female	Mid-femur	<i>S. aureus</i>	10	85

This table is not exhaustive; MR = methicillin resistant; *P. acnes* = *Propionibacterium acnes*. <sup>1</sup>The patient had recurrent osteomyelitis in this limb as a child from the age of 11. At the age of 17, he underwent resection of the distal right fibula. Reactivated osteomyelitis occurred in the regenerated fibula. <sup>2</sup>Twenty-three years before presentation, the patient had undergone a craniotomy because of oligodendroglioma. No postoperative complications are described.

(table 1).<sup>5-10</sup> To the best of our knowledge, this is the first case of reactivation due to *M. osloensis*. Similar to previous cases, we were only able to identify the microorganism with 16S-RNA gene sequence analysis.<sup>11</sup>

Chronic granulomatous inflammation is a rare but possible host reaction to osteitis. Skouby and Knudsen presented an osteomyelitis in a 3-year-old girl caused by *Kingella kingae*, formerly called *Moraxella kingie*.<sup>12</sup> The histopathological finding in that case was consistent with eosinophilic granuloma. In our case, the patient was 5 years old at the time of the forearm fracture, and the reactivation of osteitis occurred 46 years later.

In conclusion, this case illustrates that the extent of granuloma formation can be significantly larger than the bone infection triggering it. The patient's history pointed towards the diagnosis of reactivated osteitis. Finally, it shows that an otherwise unexplained histopathological finding of a chronic granulomatous inflammation should encourage the search for a causative pathogen, including those that are not typically associated with granulomatous infections, by all possible means.

#### ACKNOWLEDGEMENTS

We thank the Paediatric Haematology Laboratory of the University Children's Hospital, Bern, Switzerland, for performing the nitroblue tetrazolium dye test.

#### DISCLOSURES

##### Consent

Written informed consent was obtained from the patient for publication of this case report and accompanying images.

#### Competing interests

The authors declare that they have no competing interest. There was no funding for this case report.

#### REFERENCES

- James DG. A clinicopathological classification of granulomatous disorders. *Postgrad Med J.* 2000;76:457-65.
- Zumla A, James DG. Granulomatous infections: etiology and classification. *Clin Infect Dis.* 1996;23:146-58.
- Han XY, Tarrand JJ. *Moraxella osloensis* blood and catheter infections during anticancer chemotherapy: clinical and microbiologic studies of 10 cases. *Am J Clin Pathol.* 2004;121:581-7.
- Shah SS, Ruth A, Coffin SE. Infection due to *Moraxella osloensis*: case report and review of the literature. *Clin Infect Dis.* 2000;30:179-81.
- Korovessis P, Fortis AP, Spastris P, Droutsas P. Acute osteomyelitis of the patella 50 years after a knee fusion for septic arthritis. A case report. *Clin Orthop Relat Res.* 1991;272:205-7.
- Banky JP, Ostergaard L, Spelman D. Chronic relapsing salmonella osteomyelitis in an immunocompetent patient: case report and literature review. *J Infect.* 2002;44:44-7.
- Al-Maiyah M, Hemmady MV, Shoaib A, Morgan-Jones RL. Recurrence of chronic osteomyelitis in a regenerated fibula after 65 years. *Orthopedics.* 2007;30:403-4.
- Stevens QE, Seibly JM, Chen YH, Dickerman RD, Noel J, Kattner KA. Reactivation of dormant lumbar methicillin-resistant *Staphylococcus aureus* osteomyelitis after 12 years. *J Clin Neurosci.* 2007;14:585-9.
- Levitt MR, Gabikian P, Pottinger PS, Silbergeld DL. *Propionibacterium acnes* osteomyelitis occurring 23 years after craniotomy: case report and review of literature. *Neurosurgery.* 2011;69:E773-9.
- Libraty DH, Patkar C, Torres B. *Staphylococcus aureus* reactivation osteomyelitis after 75 years. *N Engl J Med.* 2012;366:481-2.
- Roh KH, Kim CK, Koh E, et al. Three cases of *Moraxella osloensis* meningitis: a difficult experience in species identification and determination of clinical significance. *J Korean Med Sci.* 2010;25:501-4.
- Skouby SO, Knudsen FU. *Kingella kingae* osteomyelitis mimicking an eosinophilic granuloma. *Acta Paediatr Scand.* 1982;71:511-2.