

# Laryngeal manifestations of haemochromatosis

D. Foster<sup>1</sup>, K. Pitaro<sup>1</sup>, D. Ben-Dor<sup>2</sup>, M. Englender<sup>1\*</sup>

Departments of <sup>1</sup>Ear, Nose and Throat, Head and Neck Surgery and <sup>2</sup>Pathology, Barzilai Medical Centre, 78306 Ashkelon, Israel, \*corresponding author: tel.: +972 8674-59 39, fax: +972 8674-52 13, e-mail: moshee@barzi.health.gov.il

## ABSTRACT

We present a case with sudden onset of throat pain, dysphagia and hoarseness. On endoscopic examination, supraglottic swelling and a brown covering of the mucous membranes were seen. The diagnosis of haemochromatosis was made on laryngeal biopsy. The patient admitted to long-term iron treatment for anaemia. Haemochromatosis can affect many different organs. If the larynx is involved, the airway may be endangered.

## KEYWORDS

Anaemia, airway obstruction, haemochromatosis, laryngeal

## INTRODUCTION

Primary haemochromatosis results from a genetic defect causing iron overload in various organs,<sup>2,7</sup> by increasing absorption of iron from the upper gastrointestinal tract.<sup>2,5,8</sup> The condition remains asymptomatic for several decades, until signs of end-organ disease develop. Symptoms are often non-specific in nature, and reflect the organs which are affected by iron deposition. Secondary haemochromatosis results from iron build-up in the organs from excessive intestinal iron absorption.<sup>8</sup> Haemochromatosis is sometimes discovered as an incidental finding, on a routine blood test. Symptoms of haemochromatosis usually reflect the end organ involved. We describe the first case of haemochromatosis manifesting with laryngeal symptoms.

## CASE REPORT

Mr A., a 73-year-old man, was admitted to our department with a history of a sudden onset of throat pain, difficulty

### *What is known on this topic?*

Haemochromatosis can be primary (genetic) or secondary to excessive iron intake. Different organs may be affected. When symptoms occur, they are often non-specific, and result from iron overload in the organs. The disease is often discovered as an incidental finding. Screening tests are transferrin saturation and serum ferritin. Standard treatment is repeated phlebotomy or iron-chelating agents.

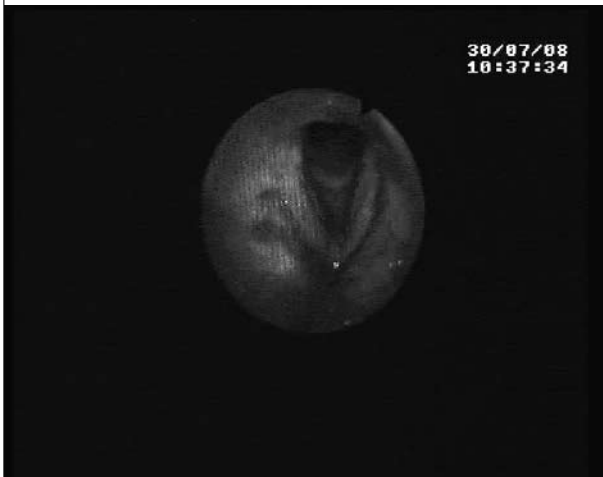### *What does this add?*

Involvement of the larynx by haemochromatosis has not been previously described. It is unclear in this case whether it was an incidental finding, or whether it contributed to the acute respiratory distress. If the former is true, this implies that routine laryngeal examination may be necessary in patients with haemochromatosis to avoid the airway becoming endangered.

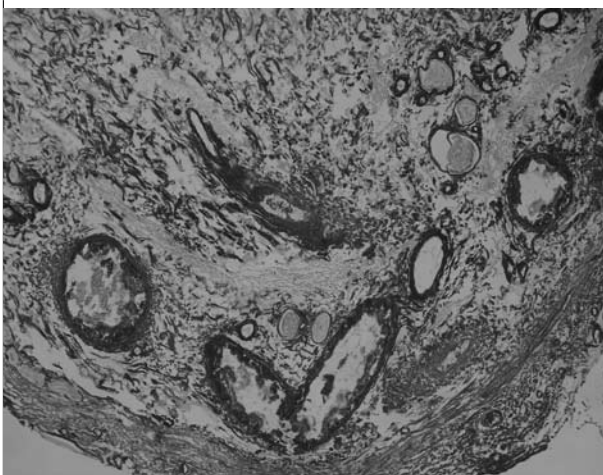
swallowing and hoarseness. He had not previously suffered from hoarseness, any other throat symptoms or heartburn, was a non-smoker and did not drink alcohol regularly. He had a history of hypertension, ischaemic heart disease, chronic renal failure and type II diabetes mellitus. His regular drug treatment included antihypertensive drugs, diuretics, and iron, which he had taken for many years. On examination, he was afebrile, did not have increased skin pigmentation, had a hoarse voice, but showed no breathing difficulties. Endoscopic examination of the larynx revealed supraglottic oedema, which did not allow examination of the vocal cords. Blood tests were within normal limits, except for haemoglobin 11.43 g/dl (13.5 to 17.5), mean cell volume 88.4 (80 to 100), urea 39.6 mmol/l (2.5 to 7.5), creatinine 262.5 µmol/l (71 to 127), and ferritin 1107.8

$\mu\text{mol/l}$  (40 to 562). Transferrin saturation was 19.9% (17.7 to 31.5). A provisional diagnosis of supraglottitis was made, and intravenous antibiotics and corticosteroids, and corticosteroid inhalations were started. After a few days of treatment, when the oedema had subsided, a dark brownish discolouration of the glottic and supraglottic mucous membranes was noted (*figure 1*). On direct laryngoscopy under general anaesthesia, dark brown patches were seen to be covering the supraglottis and vocal cords. Laryngeal biopsies were taken. Histology showed extensive perivascular iron deposits and iron incrustations (*figure 2*). To our knowledge, this is the first report in the literature of haemochromatosis presenting in the larynx.

**Figure 1.** Brown deposits around the larynx and vocal cords, seen on direct laryngoscopy (254 x 203 mm)



**Figure 2.** Histology (iron stain x 100) showing extensive perivascular iron deposits and iron incrustations, on the connective tissue fibres



The iron pigment deposits are stained blue with the iron stain (903 x 677 mm).

## DISCUSSION

Our patient presented with an unusual manifestation of haemochromatosis in the larynx.

Chronic iron overload can be classified as primary or secondary haemochromatosis.<sup>8</sup> Primary haemochromatosis is an autosomal recessive genetic defect of the iron metabolism, causing increased absorption of iron from the duodenum and upper intestine.<sup>2,5,7,8</sup> It is a common genetic disease in Caucasians, and is caused by homozygous inheritance of an abnormality on the short arm of chromosome 6.<sup>2,4,5,7</sup> In most cases, the patients are homozygous for the C282Y mutation on the HFE gene.<sup>2,3,6</sup> Symptoms from haemochromatosis usually begin between 30 and 60 years of age. In secondary haemochromatosis, excess iron builds up from increased gastrointestinal absorption resulting from a defect of erythropoiesis, iron tablets, diet, or multiple blood transfusions.<sup>8</sup> Since the body cannot excrete it, excess iron is deposited in various parenchymal organs.<sup>2,5</sup> Laryngeal deposits have so far never been described. If the diagnosis is not made early enough, irreversible end-organ damage is caused. Common screening blood tests are transferrin saturation and serum ferritin.<sup>6,7</sup> Liver biopsy used to be considered the gold standard for diagnosing this condition, but its use has been reduced recently by a combination of magnetic resonance imaging and genetic testing.<sup>1,7</sup> The disease may be asymptomatic. Clinical features are often non-specific, but when organ damage occurs, abnormal liver function tests, cirrhosis, diabetes mellitus, arthropathy, pancreatitis, cardiomyopathy, adrenal insufficiency, skin pigmentation, or testicular or ovarian atrophy can occur.<sup>2,5,7</sup> If the condition is recognised early and treated by regular phlebotomy or by iron chelating agents, irreversible complications can be prevented. Early detection and treatment before the onset of cirrhosis or diabetes mellitus, reduce morbidity, and a normal life-span can be expected.<sup>2,5,7</sup>

One of the first descriptions of haemochromatosis was of 'bronze diabetes',<sup>4</sup> describing the skin pigmentation. This is similar to the pigmented layer that we found on the larynx in our patient.

Care should be taken only to give iron treatment if it is indicated for iron deficiency anaemia, and only for the time necessary to correct the deficiency. Some patients also take over-the-counter vitamin preparations containing iron, and fail to mention them when asked about their drug treatment.

In our patient, the diagnosis of haemochromatosis was made histologically from laryngeal biopsies. It is unclear in this case if laryngeal haemochromatosis was just an incidental finding, or the cause of the episode of acute supraglottitis. Since the latter cannot be ruled out, the possibility of acute laryngeal inflammation should always

be borne in mind in patients with haemochromatosis, especially when discoloured brown or dark mucosal patches are present, in view of the risk of endangering the airway.

## CONCLUSION

This is the first report of a laryngeal presentation of haemochromatosis. This condition is often asymptomatic, but if it is not diagnosed in time, end-organ disease may occur. Iron therapy should only be prescribed to patients with genuine iron deficiency, and only continued for the time required to correct the deficit. In patients with haemochromatosis, the possibility of laryngeal manifestations should be borne in mind, since these may include laryngeal oedema, which can endanger the airway.

## REFERENCES

1. Brissot P, Troadec MB, Bardou-Jacquet E, et al. Current approach to Hemochromatosis. *Blood Rev.* 2008;22(4):195-210.
2. Fowler C. Hereditary Hemochromatosis: pathophysiology, diagnosis and management. *Crit Care Nurs Clin North Am.* 2008;20(2):191-201.
3. Ombiga J, Adams LA, Tang K, Trinder D, Olynyk JK. Screening for HFE and iron overload. *Semin Liver Dis.* 2005;25(4):402-10.
4. Yen AW, Fancher TL, Bowlus CL. Revisiting Hereditary Hemochromatosis: current concepts and progress. *Am J Med.* 2006;119(5):391-9.
5. Limdi JK, Crampton JR. Hereditary Haemochromatosis. *QJM.* 2004;97(6):315-24.
6. Brissot P, Guyader D, Loréal O, et al. Clinical aspects of hemochromatosis. *Transfus Sci.* 2000;23(3):193-200.
7. Barisani D, Green RM, Gollan JL. Genetic Hemochromatosis: pathogenesis, diagnosis, and therapy. *Dig Dis.* 1996;14(5):304-15.
8. Kirking MH. Treatment of chronic iron overload. *Clin Pharm.* 1991;10(10):775-83.