Netherlands
The Journal of Medicine

ORIGINAL ARTICLE

Ewing's sarcoma and primitive neuroectodermal tumours in adults: single-centre experience in the Netherlands

C.H. Smorenburg[1], C.J. van Groeningen[1], O.W.M. Meijer[2], M. Visser[3], E. Boven[1*]

[1]Departments of Medical Oncology, [2]Radiotherapy, [3]Pathology, VU University Medical Center, Amsterdam, the Netherlands, [1]Present address: Department of Internal Medicine, Medical Centre Alkmaar, PO Box 501, 1800 AM Alkmaar, the Netherlands, [*]corresponding author: tel.: +31 (0)20-444 43 36, fax: +31 (0)20-444 40 79.

ABSTRACT

Background: Ewing's sarcoma and peripheral primitive neuroectodermal tumours (PNET) are rare tumours and closely related. They occur most often in children and adolescents. Few studies have been published on treatment outcome in adult patients.
Methods: We performed a retrospective analysis of patients aged >16 years who were primarily treated at our university hospital for Ewing's sarcoma or PNET. In general, treatment consisted of long-term multiagent chemotherapy, interrupted by individualised local treatment consisting of surgery and/or radiotherapy. We reviewed clinical features and outcomes to present our experience with Ewing's sarcoma and PNET in adults.
Results: From 1979 to 2002, 27 patients with Ewing's sarcoma (20) or PNET (7) were treated. There were 22 men and 5 women, with a median age of 25 years (range 17-49). Ten patients presented with metastases predominantly in lungs (4) or bones (6). Combination therapy consisted of chemotherapy (27), surgery (16) and radiotherapy (16). After a median follow-up of ten years, 14 patients have died (toxicity = 2, progressive disease = 12) and 13 patients are alive and free of disease. Five-year overall survival was 58%. All four patients with bone metastases died, while all five patients presenting with lung metastases are disease-free.
Conclusion: The five-year overall survival of 58% in this small series on adult patients is in line with paediatric study outcomes. Patients with lung metastases may even be cured by multimodality therapy. We therefore strongly advocate referral of patients with this rare disease to a specialised oncology centre.

KEYWORDS

Adults, Ewing's sarcoma, PNET

INTRODUCTION

The family of Ewing's sarcoma forms a distinct entity within the group of malignant mesenchymal tumours which includes Ewing's sarcoma of bone and soft tissue, peripheral primitive neuroectodermal tumour (PNET) and Askin tumour (PNET of the thoracic wall).[1,2] The tumour was named after James Ewing, an American pathologist, who was the first to describe this disease in 1921. Morphologically, Ewing's sarcoma and PNET are small round-cell tumours consisting of undifferentiated cells with uniform nuclei and scanty cytoplasm.[3] The tumours are characterised by the expression of O13, a cell-surface antigen encoded by *mic2*.[4] Approximately 95% of patients with Ewing's sarcoma have a characteristic t(11;22)(q24;q12) or t(21;22)(q22;q12) chromosomal translocation, which results in fusion of the *EWS* gene on chromosome 22 and the *FLI 1* gene on chromosome 11 or the *ERG* gene on chromosome 21.[5,6] This translocation results in a chimeric transcription factor containing a DNA-binding domain. *In vitro*, the EWS/ETS fusion protein blocks the differentiation of pluripotent marrow stromal cells, which suggests a critical function in tumorigenesis of Ewing's sarcoma.[7]
The majority of patients with Ewing's sarcoma and PNET are younger than 30 years of age, with a peak incidence at the age of 15 years. Ewing's sarcoma is the second most common primary malignancy of bone, with an annual incidence in all ages of 0.6 per million in the United Kingdom. The overall male to female ratio is approximately 1.5:1, bone being the primary site in 60% of cases. Although Ewing's sarcoma is a rare tumour, every physician should realise that adequate therapy of Ewing's sarcoma requires a multidisciplinary approach right at the time of diagnosis. Treatment consists of multiagent chemotherapy for a prolonged period of time, even in apparently nonmetastatic disease, because of the high risk of early haematogenous metastases.[1] If

© 2007 Van Zuiden Communications B.V. All rights reserved.

feasible, chemotherapy is interrupted by aggressive local therapy of the primary tumour consisting of surgery and/or radiotherapy. This multimodality treatment has resulted in a remarkable improvement in overall five-year survival of only 20% in the 1960s to approximately 50% nowadays.[2] The optimal drug combination and duration of multiagent chemotherapy is being investigated by international study groups, such as the (European Intergroup) Cooperative Ewing's Sarcoma Study ((EI)CESS) and the American Paediatric Oncology Group (POG). Of notice, the vast majority of patients included in these studies are children and adolescents. Although almost half of all patients are being treated by medical oncologists in the adult setting, only few studies have reported treatment outcomes for adult patients.[8-14] To investigate the outcome of multimodality treatment in adult patients in the VU University Medical Center, we performed a retrospective analysis of patients treated at our university hospital.

METHODS

Patients

Using the registration of diagnosis of the Departments of Medical Encoding and Pathology, we collected the names of patients aged >16 years who were primarily treated at our hospital for Ewing's sarcoma or PNET between 1979 and 2002. The following characteristics were registered from the patient charts: age, gender, size and localisation of the primary tumour, presence and localisation of metastases. In addition, treatment modalities (cytotoxic agents, number of cycles of chemotherapy, surgery, radiotherapy), treatment outcome (response, progression, pathological response), time to progression, time to death or end of follow-up were recorded. This analysis used data obtained until January 2006.

Diagnosis of all cases was based on biopsy specimens, which were reviewed by an experienced pathologist at our centre. The diagnosis of PNET is based on markers of neuroepithelial differentiation and has been used internationally since 1988. The method of detection of characteristic chromosomal translocations using reverse transcriptase polymerase chain reaction (RT-PCR) became available in 1993, and was not routinely performed in this series.

Staging

Staging was based on physical examination, computed tomography (CT) scan or MRI scan of the primary tumour, CT scan of the chest and bone scan. In addition, a bone marrow aspiration was taken as part of the initial staging procedure. During treatment, the response of tumour lesions was evaluated every three months using similar radiographic techniques. Responses to chemotherapy were defined as progressive disease (any new lesion or increase in tumour size), stable disease (<50% decrease in tumour size), partial response (>50% tumour size reduction) and complete response (no viable tumour cells in resected pathology specimen).

Treatment

The standard regimen of chemotherapy has only slightly changed throughout time. Until 1992, chemotherapy consisted of 12 cycles of three weeks of vincristine, actinomycin D, cyclophosphamide and adriamycin (VACA) or (for patients with a high risk of recurrence) vincristine, actinomycin D, ifosfamide and adriamycin (VAIA), according to the schedule used in the CESS 86 study.[15] After 1992, patients received 14 cycles of etoposide, vincristine, actinomycin D, ifosfamide and adriamycin (EVAIA), as given in the EICESS 92 protocol for high-risk patients.[16] According to this protocol, chemotherapy was repeated every three weeks (= 1 cycle), while adriamycin was alternated with actinomycin D. In case of insufficient bone marrow recovery (white blood cell count <2.0 x 10^9/l and/or platelets <80 x 10^9/l), the next cycle of chemotherapy was postponed and granulocyte-colony stimulating factor (G-CSF) was added to subsequent cycles. Chemotherapy was interrupted for local therapy of the primary tumour after four to six cycles. Local treatment was individualised and consisted of surgery, surgery followed by radiotherapy, or radiotherapy only. Preferably, a wide excision of the tumour was preformed. Otherwise, a marginal resection was followed by radiotherapy or, in the case of (functional) irresectability, only radiotherapy was given. If histological examination of a radically resected tumour revealed more than 10% of vital tumour cells, radiotherapy was also administered postoperatively. Radiotherapy was given at a dose of 45 to 55 Gy in 25 to 30 fractions, depending on the individual indication. During radiotherapy, chemotherapy was continued in which actinomycin D and adriamycin were temporarily omitted. Adjuvant radiotherapy of lung metastases was scheduled after completing chemotherapy.

Statistics

Event-free and overall survival were estimated by the Kaplan-Meier method, using the computer programme SPSS version 9.0. Group comparisons were made using the log-rank test.

RESULTS

Patient characteristics

From 1979 to 2002, 27 patients with Ewing's sarcoma (20) or PNET (7) were primarily treated in our hospital. Another seven patients with Ewing's sarcoma or PNET were referred because of recurrent disease and were not included in this

series. Patient characteristics are depicted in *table 1*. Twenty-two men (81%) and five women (19%) were diagnosed with a median age of 25 years (range 17 to 49). The primary tumour originated in the bone in 14 patients (56%) (humerus = 3, pelvis = 3, femur = 2, , tibia = 2, spine = 1, fibula = 1, metatarsal = 1, ethmoid = 1) and had an extraosseous origin in 13 patients (chest wall = 5, soft tissue = 4, upper limb =1, lower limb = 2, leptomeningeal = 1). The median tumour size was 8 cm (range 3.3 to 25 cm). At presentation, 10 out of 27 patients (37%) had metastatic disease, predominantly in the lungs (6) and bones (4). A bone marrow aspiration was performed in 14 patients, being normal in 12 patients. In two patients with tumour cells in bone marrow aspirate the diagnosis of bone metastases had already been made. RT-PCR analysis of characteristic chromosomal translocations was not routinely performed; analysis in three out of three patients revealed a t (11;22) translocation.

Treatment

An overview of treatment modalities is given in *table 2*. Chemotherapy was given to all patients, three of whom were treated with the VAIA regimen, five with the VACA regimen and 19 (70%) with the EVAIA regimen. The median number of cycles was nine (range 1 to 14). Response to first-line chemotherapy in 22 patients was partial or complete response (13), stable disease (3), progressive disease (4) and toxic death (2). Nine out of 13 patients with a response to chemotherapy are alive and disease-free. Three patients with stable disease and four patients with progressive disease finally died of the disease despite second-line chemotherapy in two of them. Two patients with bone metastases died of neutropenic sepsis after the first cycle. Of notice, bone marrow aspirates of both of them showed tumour cells. Four patients received chemotherapy (4 to 14 courses) after complete resection of the primary tumour, and are still alive. Second-line chemotherapy was used for progressive (2) or recurrent (2) disease in four patients and consisted of VAI, cisplatin/etoposide or carboplatin/etoposide. All of them died of progressive disease due to lack of treatment response.

In four patients, complete resection was the initial treatment due to an undefined diagnosis of the incisional biopsy. Chemotherapy was given postoperatively due to a final diagnosis of Ewing's sarcoma or PNET. After a follow-up of 3.1 to 18.3 years, these four patients are alive and disease-free. Resection of the primary tumour was performed after three to five cycles of chemotherapy in 12 patients. Data on resection margins of one patient could not be retrieved. Resection margins were free of tumour in seven patients and irradical in four patients, respectively. Data on viability of tumour cells were lacking in five patients. All three patients whose tumour did not contain any vital cells at histological examination are alive. Three out of four patients with vital tumour cells died of progressive disease.

Radiotherapy was given on the site of the primary tumour in 15 patients, in nine of them after preceding surgery. One patient with leptomeningeal disease started with radiotherapy on the neuraxis, followed by chemotherapy. This patient died of progressive disease.

After completing chemotherapy, five patients received radiotherapy for lung metastases (whole lung irradiation = 3, partial lung irradiation = 2). At present, these five patients are disease-free and may be considered as being cured after a follow-up of 6.8 to 26.5 year.

Table 1. *Patient characteristics*

Variable	No. of patients (n=27)
Gender	
Female	5
Male	22
Age	
Median (years)	25
Range (years)	17-49
16-20 years	11
>20 years	16
Site of primary tumour	
Lower limb	8
Pelvis	3
Spine	1
Soft tissue	4
Chest wall	5
Upper limb	4
Head and neck	2
Size of primary tumour	
<5 cm	6
5-10 cm	8
>10 cm	11
Unknown	2
Site of metastasis	
Lung only	5
Lung + bone + bone marrow	1
Bone only	2
Bone + bone marrow	1
Liver + peritoneum	1

Survival

After a median follow-up of 10.0 years (range 3.2 to 26.5 years), a total of 14 patients have died and 13 patients are alive and disease-free (*table 2*). *Figure 1* depicts the survival probability according to Kaplan-Meier. In our series, five-year overall survival was 58%, with a median overall survival of 120 months (95% CI 107 to 227). The five-year overall survival was 52 and 60% for patients with nonmetastatic and metastatic disease, respectively (not significant). Of notice, all four patients with bone metastases died of either progressive disease (2) or neutropenic sepsis (2), while five out of six patients with lung metastases were cured ($p<0.005$, log rank). In this study, no other significant correlations were observed between patient characteristics and survival.

Table 2. *Primary treatment modalities and treatment outcome*

Treatment	No. of patients (n=27)	No. of patients alive (n=13)
Chemotherapy alone	4	0
CT → Surgery → CT	3	2
CT → Radiotherapy → CT	6	3
CT → Surgery + Radiotherapy → CT	9	4
Surgery → Chemotherapy	4	4
Radiotherapy → Chemotherapy	1	0

CT = chemotherapy.

Figure 1. *Kaplan-Meier curve of overall survival of 27 adult patients with Ewing's sarcoma or PNET treated at the VU University Medical Center between 1979 and 2002.*

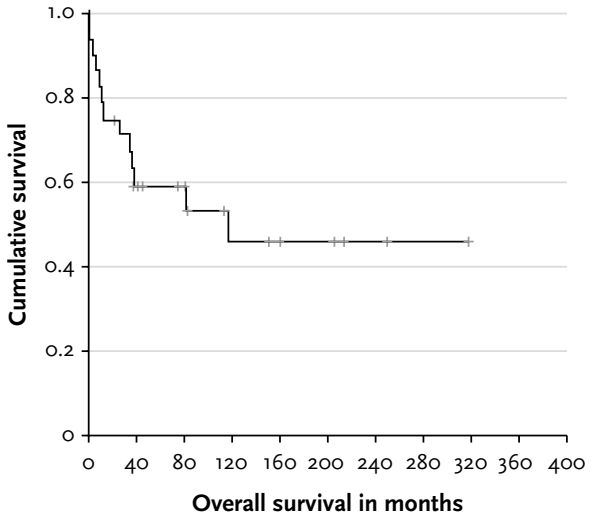

DISCUSSION

This is the first Dutch series of adult patients with Ewing's sarcoma and PNET. The five-year overall survival of 58% in our patients with nonmetastatic disease is quite similar to the reported series on adult patients that range from 35 to 60% (*table 3*).[8-14] In our series, five-year overall survival was not worse in patients with metastatic disease as compared with nonmetastastic disease, which is likely due to the small number of patients with metastasis (n=10) in our series. Larger series report an overall survival of 20 to 30% for patients with metastatic disease.[17] This modest outcome, however, still contrasts favourably with low five-year overall survival rates of the majority of solid malignant tumours with distant metastases.

Poor prognostic factors for Ewing's sarcoma and PNET in adult patients are large tumours,[9,10] primary tumour of the pelvis,[8,10] metastases at presentation[11,12] and advanced age.[11] Similar prognostic factors were observed in two large studies including mainly paediatric patients.[17,18]

Advanced age as a poor prognostic factor may either be related to biological aspects of more aggressive disease or a lower dose intensity of chemotherapy to be delivered. Preliminary data of a large retrospective German analysis of 1426 patients reported both age >15 years at diagnosis and treatment outside paediatric oncology units as significantly poor prognostic factors.[19] A large study in children has reported a five-year overall survival of 61 to 72%,[18] which is higher than that observed in adult patients.[8-14] In two other studies in adult patients, however, age >30 years did not appear to be related to a dismal outcome.[10,13]

Metastases at presentation are correlated with a poor prognosis.[11,12] The localisation of metastases, however, is of importance. We observed a long-term disease-free survival in five out of six patients with lung metastases. In contrast,

Table 3. *Survival data in adult patients with Ewing's sarcoma or PNET*

Author	Ref.	Chemotherapy	No. of patients	No. of patients with M1	5-year overall survival (%)	5-year overall survival in M0 (%)	5-year overall survival in M1 (%)
Sincovics	8	VACA	50	16		35	19
Verrill	9	IVAD	59	17		52	10
Fizazi	10	VACA, IVAD, VAD	182	53		54	9
Baldini	11	VAD or VACA	37	11		49	0
Bacci	12	VACA, EVAIA	23	n.k.	53	n.k.	n.k.
Martin	13	Combination n.k.	59	9		60	33
Laurence	14	High dose + PSCT	46	10	63	71	34
This study		VACA, VAIA or EVAIA	27	10	58	52	60

M0 = no metastases; M1 = metastatic disease; PSCT = peripheral stem cell transplantation; n.k.= not known; n.s.= not significant.
VACA = vincristine, actinomycin D, cyclophosphamide, adriamycin; IVAD = ifosfamide, vincristine, adriamycin, actinomycin D; EVAIA = etoposide, vincristine, actinomycin D, ifosfamide, adriamycin.

all four patients with bone metastases, including a patient with simultaneous lung metastases, died of progressive disease. Likewise, paediatric studies have also reported a better prognosis for patients with lung metastases as compared with those with bone metastases.[19,21-23] Although two out of five patients with lung metastases received successful partial irradiation, whole lung irradiation in such patients is being advised in EICESS protocols.

According to EICESS protocols,[16] two separate bone marrow biopsies should be performed as part of the initial staging procedure to define the intensity of treatment. In our series in which patients did not participate in a clinical trial, a bone marrow aspiration was only taken in half of the patients. Histopathological examination revealed bone marrow metastases in two patients, who also had bone metastases visualised on a bone scan. Both patients died of neutropenic sepsis. In addition to immunohistochemistry, Schleiermacher *et al.*[24] used a PCR technique targeting *EWS*-specific transcripts and detected micrometastases in bone marrow in 18 out of 92 patients (20%) with Ewing's sarcoma. This subgroup of patients indeed had an impaired prognosis and an increased risk of systemic relapse. Detection of micrometastases in bone marrow, however, lacks therapeutic consequences and PCR on bone marrow is therefore not routinely recommended.

None of the four patients with progressive or recurrent disease in our study responded to second-line chemotherapy. Progressive or recurrent disease still has a poor outcome, despite aggressive therapy including high-dose chemotherapy and peripheral stem cell transplantation (PSCT).[23,24] Thus far, no standard chemotherapy can be recommended in this setting and identification of novel agents is warranted.

Despite improvement in the treatment outcome of Ewing's sarcoma and PNET during the past decades, almost half of all patients ultimately die of this disease. It is clear that for optimal efficacy of combined modality therapy with a curative intention, a multidisciplinary approach by experienced medical oncologists, surgeons and radiotherapists is essential. With regard to the low incidence of this tumour, we therefore strongly advocate referral of these patients to a specialised oncology centre and participation in international trials.

REFERENCES

1. Rodriquez-Galindo C, Spunt SL, Pappo AS. Treatment of Ewing sarcoma family of tumors: current status and outlook for the future. Med Pediatr Oncol 2003;40:276-87.
2. Arndt CAS, Crist WM. Common muskuloskeletal tumors of childhood and adolescence. N Engl J Med 1999;341:342-52.
3. Delattre O, Zucman J, Melot T, et al. The Ewing-family of tumors – a subgroup of small-round-cell tumors defined by specific chimeric transcripts. N Engl J Med 1994;331:294-9.
4. Fellinger EJ, Garin-Chesa P, Triche TJ, Huvos AG, Rettig WJ. Immunohistochemical analysis of Ewing's sarcoma cell surface antigen p30/32^{mic2}. Am J Pathol 1991;139:317-25.
5. Downing JR, Head DR, Parham DM, et al. Detection of the (11;22)(q24;q12) translocation of Ewing's sarcoma and peripheral neuroectodermal tumor by reverse transcription polymerase chain reaction. Am J Pathol 1993;143:1294-300.
6. Sorensen PH, Lessnick SL, Lopez-Terrada D, Liu XF, Triche TJ, Denny CT. A second Ewing's sarcoma translocation, t(21;22), fuses the EWS gene to another ETS-family transciption factor, ERG. Nat Genet 1994;6:146-51.
7. Torchia EC, Jaishankar S, Baker SJ. Ewing tumor fusion proteins block the differentiation of pluripotent marrow stromal cells. Cancer Res 2003;63:3464-8.
8. Sinkovics JG, Plager C, Ayala AG, Lindberg RD, Samuels ML. Ewing sarcoma: its course and treatment in 50 adult patients. Oncology 1980;37:114-9.
9. Verrill MW, Judson IR, Harmer CL, Fisher C, Thomas JM, Wiltshaw E. Ewing's sarcoma and primitive neuroectodermal tumor in adults: are they different from Ewing's sarcoma and primitive neuroectodermal tumor in children? J Clin Oncol 1997;15:2611-21.
10. Fizazi K, Dohollou N, Blay JY, et al. Ewing's family of tumors in adults : multivariate analysis of survival and long-term results of multimodality therapy in 182 patients. J Clin Oncol 1998;16:3736-43.
11. Baldini EH, Demetri GD, Fletcher CDM, Foran J, Marcus KC, Singer S. Adults with Ewing's sarcoma/primitive neuroectodermal tumor. Ann Surgery 1999;230:79-86.
12. Bacci G, Ferrari S, Comandone A, et al. Neoadjuvant chemotherapy for Ewing's sarcoma of bone in patients older than thirty-nine years. Acta Oncol 2000;39:111-6.
13. Martin RCG, Brennan MF. Adult soft tissue Ewing Sarcoma or primitive neuroectodermal tumors: predictors of survival? Arch Surg 2003;138:281-5.
14. Laurence V, Pierga JY, Barthier S, et al. Long-term follow up of high-dose chemotherapy with autologous stem cell rescue in adults with Ewing sarcoma. Am J Clin Oncol 2005;28:301-9
15. Paulussen M, Ahrens S, Dunst J, et al. Localized Ewing tumor of bone: final results of the Cooperative Ewing's Sarcoma Study CESS-86. J Clin Oncol 2001;19:1818-29.
16. Schuck A, Ahrens S, Paulussen M, et al. Local therapy in localized Ewing tumors: results of 1058 patients treated in the CESS 81, CESS 86 and EICESS 92 trials. Int J Radiat Oncol Biol Phys 2003;55:168-77.
17. Grier HE, Krailo MD, Tarbell NJ, et al. Addition of ifosfamide and etoposide to standard chemotherapy for Ewing's sarcoma and primitive neuroectodermal tumor of bone. N Engl J Med 2003;348:694-701.
18. Paulussen M, Ahrens S, Burdach S, et al. Primary metastatic (stage IV) Ewing tumor : survival analysis of 171 patients from the EICESS studies. Ann Oncol 1998;9:275-81.
19. Paulussen M, Ahrens S, Juergens HF. Cure rates in Ewing tumor patients aged over 15 years are better in pediatric oncology units. Proc Am Soc Clin Oncol 2003;22:816 (abstract 3279).
20. Cotterill SJ, Ahrens S, Paulussen M, et al. Prognostic factors in Ewing's tumor of bone: analysis of 975 patients from the European Intergroup Cooperative Ewing's Sarcoma Study Group. J Clin Oncol 2000;18:3108-14.
21. Miser JS, Krailo MD, Tarbell NJ, et al. Treatment of metastatic Ewing's sarcoma or primitive neuroectodermal tumor of bone: evaluation of combination ifosfamide and etoposide-a Children's Cancer Group and Pediatric Oncology Group Study. J Clin Oncol 2004;22:2873-6.
22. Pinkerton CR. Bataillard A, Guilo S, Oberlin O, Fervers B, Philip T. Treatment strategies for metastatic Ewing's sarcoma. Eur J Cancer 2001;37:1338-44.
23. Burdach S, Meyer-Bahlburg A, Laws HJ, et al. High-dose therapy for patients with primary multifocal and early relapsed Ewing's tumors: results of two consecutive regimens assessing the role of total-body irradiation. J Clin Oncol 2003;21:3072-8.
24. Schleiermacher G, Peter M, Oberlin O, et al. Increased risk of systemic relapses associated with bone marrow micrometastases and circulating tumor cells in localized Ewing tumor. J Clin Oncol 2003;21:85-91.