

# Mirizzi's syndrome

M.J.B. Aarts\*, L.G.J.B. Engels

Department of Gastroenterology, Maasland Hospital, Walramstraat 23, 6131 BK Sittard, the Netherlands, \*corresponding author

## ABSTRACT

A case is described emphasising rare complication of gallstone disease: the Mirizzi syndrome in which an impacted gallstone in the Hartmann's pouch or cystic duct causes common hepatic duct obstruction and by eroding a fistula. Diagnosis is made by endoscopic retrograde cholangio-pancreatography and treatment includes cholecystectomy.

## KEYWORDS

Endoscopic retrograde cholangio-pancreatography, gallstones, Mirizzi's syndrome

## INTRODUCTION

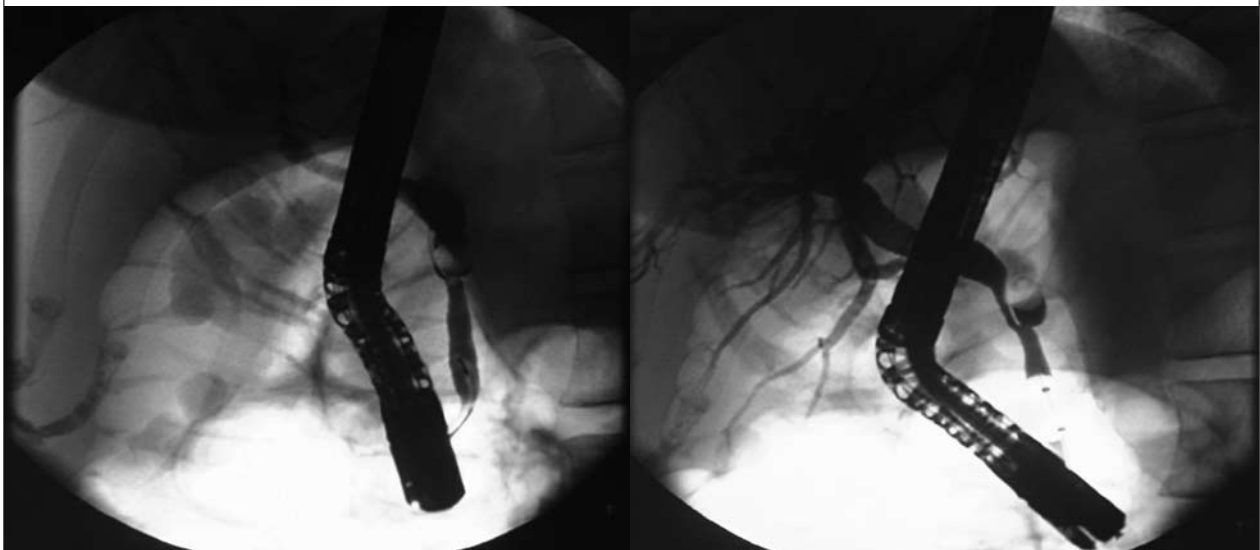
In Western Europe, the prevalence of gallstones is high. The standard treatment of symptomatic gallstones is laparoscopic cholecystectomy and bile duct stones are treated endoscopically. Unfortunately, it is sometimes difficult to extract bile duct stones, for example in patients

with Mirizzi's syndrome.<sup>1,2</sup> In this case report, we present a patient with this syndrome.

## CASE REPORT

A 43-year-old woman visited our outpatient clinic in March 2004 with a six-month history of colic pain, nausea and vomiting. She had a past history of hyperthyroidism. Physical examination revealed a tender right upper abdomen and jaundice. The laboratory blood tests showed increased levels of bilirubin 67.9  $\mu\text{mol/l}$  (normal 3-22  $\mu\text{mol/l}$ ), alkaline phosphatase 145 U/l (<140 U/l),  $\gamma$ -glutamyl-transferase 161 U/l (<40 U/l), alanine transaminase 1240 U/l (<40 U/l), aspartate transaminase 688 U/l (<35 U/l) and lactate dehydrogenase 888 U/l (<480 U/l), while the serum amylase was normal. Ultrasonography showed slightly dilated intrahepatic ducts, an extended gallbladder with multiple stones and a stone in the choledochal duct. Moreover, on endoscopic retrograde cholangio-pancreatography (ERCP) we found a stone located in the cystic duct distal to the orifice of the choledochal duct and with compression of the before common hepatic duct (*figure 1*).

Figure 1. Retrograde cholangiography



## DISCUSSION

Mirizzi's syndrome is named after Doctor Pablo Mirizzi, who described a peculiar bile duct obstruction due to gallstones in 1948.<sup>1</sup> However, this condition had been reported as early as in 1905. This syndrome refers to common hepatic duct obstruction caused by an extrinsic compression of an impacted stone in the Hartmann's pouch or cystic duct (type I). Predispositions are a low-lying cystic-choledochal duct juncture, contiguity of a large cystic duct with the common hepatic duct or a short cystic duct. Also inflammation contributes to the bile duct obstruction. If the obstruction persists the stone may erode into the common bile duct producing a cholecystocholedochal fistula (type II).<sup>2,3</sup>

Patients generally present with clinical and biochemical signs of biliary obstruction, sometimes in the setting of an acute cholecystitis, acute cholangitis or pancreatitis. There is usually a longstanding history of biliary symptoms. Approximately 50 to 77% of all patients reported are women. ERCP is the method of choice for diagnosing these patients. The radiological appearance of this condition may be misinterpreted as a tumour of the gallbladder or cystic duct, a cholangiocarcinoma, metastatic disease of the hilum or acute cholecystitis. These diseases should be excluded by a CT or an ultrasound.<sup>4,5</sup>

ERCP is not the therapy of choice because stone extraction fails due to inability to access or capture the impacted stone. The standard treatment of Mirizzi's syndrome is a cholecystectomy and stone retrieval followed by temporary T-tube insertion.<sup>6,7</sup> Normally, this should be performed by a laparoscopy, but the presence of acquired biliary abnormalities sometimes makes it difficult to interpret the anatomy, especially with extensive adhesions, and gives more risk for bile duct injury. If there is any suspicion of abnormalities, an open cholecystectomy should be

performed, if necessary in combination with a peroperative cholangiography. In patients who are not fit for surgery, endoscopic treatment, endoscopic papillotomy, and/or stent placement with or without electrohydraulic lithotripsy should be preferred.

## CONCLUSION

In our patient, the diagnosis was made on ERCP. In accordance with the guidelines, our patient underwent surgery, which confirmed the diagnosis: a stone eroding from the cystic duct into the choledochal duct (type II). Subsequently, a cholecystectomy was performed with extraction of the stone and a temporary T-drain was left *in situ*. The patient recovered completely without any complications within a few days.

## REFERENCES

1. Mirizzi PL. Sindrome del conducto hepatico. J Int Chir 1948;8:731-7.
2. Abou-Saif A, Al-Kawas FH. Complications of gallstone disease; Mirizzi syndrome, cholecystocholedochal fistula, and gallstone ileus. Am J Gastroenterol 2002;97(2):249-54.
3. Dorrance HR, Krishna Lingam M, Hair A, Oien K, O'Dwyer PJ. Acquired Abnormalities of the Biliary Tract from Chronic Gallstone Disease. J Am Coll Surg 1999;94(9):2546-50.
4. Meng WC, Kwok SP, Kelly SB, Lau WY, Li AK Management of Mirizzi syndrome by laparoscopic cholecystectomy and laparoscopic ultrasonography. Br J Surgery 1995;82(3):396.
5. Becker CD, Hassler H, Terrier F. Preoperative diagnosis of the Mirizzi syndrome: limitations of sonography and computed tomography. Am J Roentgenol 1984;143(3):591-6.
6. Binmoeller KF, Thonke F, Soehendra N. Endoscopic treatment of Mirizzi's syndrome. Gastrointest Endosc 1993;39(4):532-6.
7. England RE, Martin DF. Endoscopic management of Mirizzi's syndrome. Gut 1997;40:272-6.

