

# Atypical Cushing's syndrome caused by ectopic ACTH secretion of an oesophageal adenocarcinoma

J.M. Baas<sup>1\*</sup>, E. Kapiteijn<sup>1</sup>, A.M. Pereira<sup>2</sup>, J.W.R. Nortier<sup>1</sup>

Departments of <sup>1</sup>Clinical Oncology, <sup>2</sup>Endocrinology and Metabolic Diseases, Leiden University Medical Centre, Leiden, the Netherlands, \*corresponding author: tel.: +31 (0)71-526 34 86, fax: +31 (0)71-526 6760, e-mail: j.m.baas@lumc.nl

## ABSTRACT

We present an atypical case of Cushing's syndrome caused by ectopic adrenocorticotrophic hormone (ACTH) secretion in a patient with a metastasised adenocarcinoma of the oesophagus. After chemotherapy and surgery the patient developed generalised oedema, hyperpigmentation and dysphagia. Laboratory tests showed hypokalaemia, normal urinary potassium, increased 24-hour urinary free cortisol excretion and serum ACTH within the normal reference range. The diagnosis of ACTH-dependent Cushing's syndrome was made, most probably caused by ectopic production of ACTH. In addition to combined chemotherapy, treatment with ketoconazole sufficiently reduced urinary cortisol excretion and relieved the symptoms.

## KEYWORDS

Cushing's syndrome, ectopic ACTH secretion, oesophagus carcinoma

## CASE REPORT

A 61-year-old man was referred to our centre for further treatment with chemotherapy of an adenocarcinoma of the distal oesophagus metastasised to the liver and regional lymph nodes. He had previously been treated with six cycles of combination chemotherapy (cisplatin, epirubicin and capecitabine; ECC), radiofrequency ablation (RFA) of nine of 27 liver metastases, and resection and re-excision of a lymph node at the truncus coeliacus in two other university medical centres. After the six ECC courses the primary tumour in the oesophagus was no longer visible

at endoscopy; however, a positron emission tomography (PET) scan revealed multiple small liver metastases and a regional lymph node metastasis in the coeliac region. It was decided to treat the largest liver metastases with RFA and to surgically resect the pathological coeliac lymph nodes.

Two months after the last course of chemotherapy and shortly after surgery, the patient noticed generalised oedema, hyperpigmentation of the skin and dysphagia. Laboratory tests revealed marked hypokalaemia (2.3 mmol/l; normal range (N) 3.6 to 4.8 mmol/l), mild hypoalbuminaemia (34 g/l; N 35 to 52 g/l), and metabolic alkalosis. Urine dipstick was negative for protein, urinary potassium excretion was normal: 79 mmol/l (N 5 to 90 mmol/l). A combined PET-CT scan showed signs of local recurrence of the primary tumour (confirmed during endoscopy), and new lesions in the liver. The patient was treated with potassium chloride and potassium-sparing diuretics (spironolactone).

When the patient was re-evaluated to consider second-line chemotherapy, his blood pressure was 140/90 mmHg with persistent hypokalaemia and oedema. Additional tests revealed the following: serum cortisol 4.212 umol/l (N 0.1 to 0.6 umol/l), and 24-hour urinary free cortisol (UFC) excretion 30,682 nmol (N 55 to 220 nmol). ACTH was within the normal reference range: 32 ng/l (N 0 to 75 ng/l). Cortisol was not suppressed by a low dose of dexamethasone (1 mg) overnight. On CT the adrenals appeared normal. The diagnosis of ACTH-dependent Cushing's syndrome was made, most probably caused by ectopic production of ACTH. It was decided not to perform additional biochemical testing but to pragmatically treat the patient with ketoconazole as a cortisol synthesis blocking agent (starting dose 200 mg

thrice daily (tid)) in combination with spironolactone (100 mg tid). Combination chemotherapy was continued with oxaliplatin, epirubicin, and capecitabine (EOX).

Two weeks later his oedema had decreased dramatically, his blood pressure normalised (110/70 mmHg), and the serum potassium was elevated (5.6 mmol/l). Serum cortisol decreased to 0.91 µmol/l, and 24-hour UFC to 1.120 nmol. Both the oral potassium chloride supplementation and spironolactone were stopped. Eventually, 24-hour UFC normalised with a ketoconazole dose of 100 mg twice daily. Revision of the primary tumour and the resected lymph node metastases confirmed the diagnosis of a poorly differentiated non-small-cell adenocarcinoma, with some neuro-endocrine differentiation and expression of ACTH as shown by additional immunohistochemistry (figure 1). After six courses of EOX and ketoconazole, the liver metastases decreased in number and size, the clinical condition of the patient markedly improved, and the symptoms of oedema and muscle weakness disappeared completely. He received additional palliative treatment of the liver metastases with microspheres labelled with Yttrium. After this, the primary tumour was no longer visible at endoscopy, though a PET-CT scan showed two new metastases in the liver. He is currently on low-dose capecitabine.

## DISCUSSION

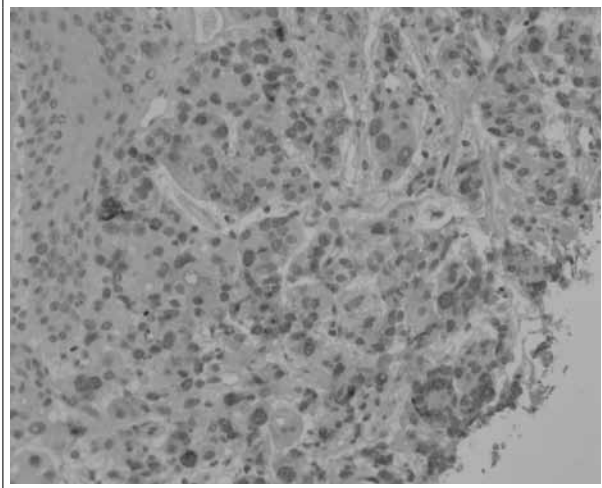
To our knowledge, this is the first case of Cushing's syndrome caused by ectopic ACTH production by an adenocarcinoma of the oesophagus. The diagnosis of Cushing's syndrome caused by ectopic ACTH secretion was considered since laboratory tests showed an inappropriately normal urine potassium excretion in the

presence of marked hypokalaemia. The relatively low level of ACTH in this patient is likely due to the assay sensitive to pituitary ACTH. Additional to the presentation of Cushing's syndrome, this patient had an unusual course of his metastasised oesophagus carcinoma. Though there is currently no international standard first-line therapy for advanced or metastatic oesophageal cancer, a combination of cisplatin or oxaliplatin, an anthracycline and 5FU/capecitabine, as was given to our patient, is considered to be most effective. However, even in patients receiving chemotherapy, median overall survival is reported to be seven to ten months.<sup>1</sup> Our patient has shown to be responsive to several therapies and he is now free of a local recurrence, almost two years after he was first diagnosed. The diagnosis was not otherwise biochemically confirmed because of the clinical condition of the patient, and because the pretest likelihood of an ectopic origin of ACTH secretion was increased based on certain clinical characteristics. Effectiveness-based studies<sup>2,3</sup> indicated that certain clinical characteristics in Cushing's syndrome add more discriminatory power to the pretest probability in the differentiation of pituitary-dependent from an ectopic ACTH-dependent disease than biochemical testing. These characteristics for ectopic ACTH syndrome include male gender, older age, high urinary free cortisol, the presence of hypokalaemia, and ACTH levels. In addition, these studies demonstrated that the accuracy of the high-dose intravenous dexamethasone test and the corticotropin-releasing hormone test as diagnostic tools in the differential diagnosis of ACTH-dependent Cushing's syndrome was insufficient.

This case illustrates that in patients with metastasised malignancies, the clinical presentation of ectopic Cushing's syndrome can be atypical (i.e., without weight gain and truncal obesity) and only manifest with symptoms of mineralocorticoid excess, such as severe hypokalaemia and (mild) hypertension. Cushing's syndrome is caused by ectopic ACTH secretion in approximately 12% of cases. It is most frequently seen in small cell carcinoma, but also in metastasised bronchopulmonary, pancreatic and thymic carcinoids, and metastasised medullary thyroid carcinoma.<sup>4,5</sup> Other sporadic cases of ectopic ACTH syndrome were associated with metastasised tumours of the ovaries, colon, prostate, breast and stomach, with metastasised melanoma and squamous cell carcinoma of the oesophagus.<sup>6-8</sup>

The onset of Cushing's syndrome in malignancies can be either acute, with predominant features such as oedema and hypokalaemia, as seen in small cell carcinoma of the lung and in our patient, or more insidious, with a more gradual onset of classical features of Cushing's syndrome, as in Cushing's disease. The latter more gradual onset of mostly typical Cushing's syndrome is usually seen in metastasised neuroendocrine tumours such as bronchial,

**Figure 1.** Oesophagus biopsy showing atypical epithelial cells with enlarged nuclei and with expression of ACTH, along with normal squamous cell epithelium



thymic or pancreatic carcinoids and medullary thyroid carcinomas. In case of acute onset, hypercortisolism is usually severe and oedema, hypertension, hypokalaemia, metabolic alkalosis, and glucose intolerance are often present.<sup>4</sup> There appears to be a strong association between the presence of hypertension and hypokalaemia with Cushing's syndrome caused by ectopic ACTH secretion.<sup>5</sup> In addition, the presence of hypokalaemia is tightly related to excessively increased 24-hour UC excretion, which reflects a highly increased cortisol production. This is most likely due to the fact that cortisol may act as a mineralocorticoid when in excess, by saturating the 11beta-hydroxysteroid-dehydrogenase (11beta-HSD2 enzyme) that inactivates cortisol at the renal tubule. Thus, as documented in our patient, excessive cortisol levels are the principal cause of hypokalaemic alkalosis in Cushing's syndrome, rather than inhibition of the 11betaHSD2 enzyme by ACTH or the effects of adrenal steroid biosynthetic intermediaries with mineralocorticoid activity.

Resection of the ACTH-producing tumour or bilateral adrenalectomy can resolve hypercortisolism. However, complete resection of tumour mass(es) is often not possible, since most (metastasised) tumours grow invasively and are not resectable. Moreover, due to the limited life-expectancy of (metastasised) cancer patients, patients are often not considered eligible for bilateral adrenalectomy. In these cases, hypercortisolism can be controlled using agents that block adrenal corticosteroid synthesis, such as ketoconazole or metyrapone, in combination with potassium replacement and spironolactone, when necessary. Treatment can be titrated according to changes in 24-hour urinary excretion of cortisol.<sup>8</sup> Other pharmacological agents to treat ectopic ACTH syndrome mentioned in the literature are octreotide, and mitotane (ortho-para DDD).<sup>4</sup>

Although rare in adenocarcinomas, ectopic ATCH syndrome should be considered in cancer patients with

oedema, hypokalaemia and alkalosis, without the presence of other classical features of Cushing's syndrome. In our patient, in addition to combined chemotherapy, treatment with ketoconazole sufficiently reduced urinary cortisol excretion and relieved symptoms of oedema and hypokalaemia.

## ACKNOWLEDGEMENT

We thank Dr J.V.M.G. Bovee for her help with the pathology report and for providing the illustration.

## REFERENCES

1. Wagner AD, Grothe W, Haerting J, Kleber G, Grothey A, Fleig WE. Chemotherapy in advanced gastric cancer: a systematic review and meta-analysis based on aggregate data. *J Clin Oncol*. 2006;24(18):2903-9.
2. Aron DC, Raff H, Findling JW. Effectiveness versus efficacy: the limited value in clinical practice of high dose dexamethasone suppression testing in the differential diagnosis of adrenocorticotropin-dependent Cushing's syndrome. *J Clin Endocrinol Metab*. 1997;82(6):1780-5.
3. Reimondo G, Paccotti P, Minetto M, Termine A, Stura G, Bergui M, et al. The corticotrophin-releasing hormone test is the most reliable noninvasive method to differentiate pituitary from ectopic ACTH secretion in Cushing's syndrome. *Clin Endocrinol. (Oxf)* 2003;58(6):718-24.
4. Orth DN. Cushing's syndrome. *N Engl J Med*. 1995;332(12):791-803.
5. Torpy DJ, Mullen N, Ilias I, Nieman LK. Association of hypertension and hypokalemia with Cushing's syndrome caused by ectopic ACTH secretion: a series of 58 cases. *Ann N Y Acad Sci*. 2002;970:134-44.
6. de Matos LL, Trufelli DC, das Neves-Pereira JC, Danel C, Riquet M. Cushing's syndrome secondary to bronchopulmonary carcinoid tumor: report of two cases and literature review. *Lung Cancer*. 2006;53(3):381-6.
7. Imura H, Matsukura S, Yamamoto H, Hirata Y, Nakai Y. Studies on ectopic ACTH-producing tumors. II. Clinical and biochemical features of 30 cases. *Cancer*. 1975;35(5):1430-7.
8. Rickman T, Garmany R, Doherty T, Benson D, Okusa MD. Hypokalemia, metabolic alkalosis, and hypertension: Cushing's syndrome in a patient with metastatic prostate adenocarcinoma. *Am J Kidney Dis*. 2001;37(4):838-46.