

Coexistence of cystic intra-abdominal lymphangiomas and diffuse venous haemangiomas in adult life

A. Canataroglu¹, Y. Gumurdulu¹, D. Gumurdulu², M. Balal¹, I. Tuncer², Y. Sagliker^{1*}

Departments of ¹Internal Medicine and ²Pathology, Faculty of Medicine, Cukurova University, 01330, Balcali, Adana, Turkey, tel.: +90 322-338 60 60, fax: +90 322-454 21 96, e-mail: sagerya@superonline.com, * corresponding author

ABSTRACT

Diffuse haemangioma and intra-abdominal lymphangioma are rare in adults. In this case report, we present a 33-year-old female with coexisting multiple cutaneous and visceral cavernous haemangiomas and two huge intra-abdominal lymphangiomas of 25 and 35 cm in diameter. The organs involved were the liver, pericardium, renal hilus and bladder. She died due to disseminated intravascular coagulation and multiorgan failure, which resembled Kasabach-Merritt syndrome. The coexistence of generalised haemangiomas and intra-abdominal lymphangiomas and the lack of complaints until the age of 33 years makes her an unusual case in the literature. We also emphasise the other clinical conditions that should be considered in the differential diagnosis.

INTRODUCTION

Haemangioma is one of the most common soft tissue tumours, particularly in infancy and childhood, constituting 7% of benign tumours. The majority of haemangiomas are superficial lesions that have a predilection for head and neck, but may occur internally, notably in organs such as the liver. Lymphangiomas are the lymphatic analogue of the haemangiomas of blood vessels.^{1,2}

In this report, we present a case with coexisting cystic intra-abdominal lymphangiomas and diffuse venous haemangiomas in adult life.

CASE REPORT

A 33-year-old woman was admitted to the intensive care unit with renal failure and severe anaemia. She had widespread blue-coloured lesions, which she had first noticed on her neck at the age of 13. She did not seek medical help for these lesions. She had two uneventful births and her children were healthy. There was no family history of similar lesions. Physical examination revealed a body temperature of 36°C, pulse rate 120 beats/min and regular, respiration rate 24/min and blood pressure 80/50 mmHg, supine. Her general condition was poor; she was pale and had multiple blue-coloured, soft, nodular lesions, ranging from 3 to 80 mm in size throughout her body (*figure 1*). Two soft painless masses

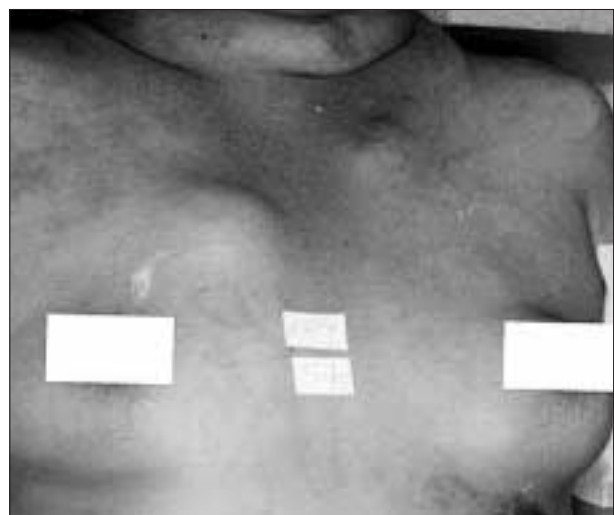

Figure 1
Widespread blue-coloured, soft cutaneous lesions on the trunk and neck

were found during abdominal examination. Laboratory data showed a red blood cell count of 0.73 million/cu mm, haemoglobin 1.8 g/dl, haematocrit 5.6%, mean corpuscular volume 76 fl, mean corpuscular haemoglobin 25 pg/cell, mean corpuscular haemoglobin concentration 32 g/dl, WBC count $4.7 \times 10^9/l$, platelet count $24 \times 10^9/l$, blood urea nitrogen 28 mmol/l, creatinine 415 $\mu\text{mol/l}$, sodium 128 mmol/l, potassium 5.1 mmol/l, chloride 89 mmol/l, alanine amino transferase 129 IU/l, aspartate amino transferase 123 IU/l, lactic dehydrogenase 970 IU/l, total bilirubin 8.5 $\mu\text{mol/l}$, and direct bilirubin 3.4 $\mu\text{mol/l}$. Peripheral blood smear demonstrated polychromasia, anisocytosis, fragmented erythrocytes, normoblasts which were consistent with intravascular haemolysis, and thrombocytopenia. Bone marrow aspiration revealed erythroid hyperplasia. The prothrombin time was 28 sec (n=11-15 sec), partial thromboplastin time 40 sec (n=24-32 sec), fibrinogen 90 mg/dl (n=150-350 mg/dl), fibrin degradation products $>40 \mu\text{g/ml}$ (n $<10 \mu\text{g/ml}$), and disseminated intravascular coagulation (DIC) was considered. She was oliguric with a urinary output of 100 ml a day. Urine sediment revealed few red blood cells and leucocytes. Urine sodium was 17 mmol/l. Repeated occult blood tests of her stools were negative. She had no signs or findings that indicated either a site of occult haemorrhage or haemolytic and aplastic anaemia. Abdominal computerised tomography, which was performed on the first day of hospitalisation, revealed a sharply demarcated hypodense lesion measuring 4 cm in size in the right lobe of the liver, and two large, well-circumscribed rounded cystic masses that filled the abdominal cavity (figure 2).

She received a transfusion of 17 units of whole blood and the haemoglobin level increased to 7 g/dl. Dopamine and furosemide were administered for three days to treat acute renal failure, but she died on the fourth day of hospitalisation because of multiorgan failure due to DIC.

Necropsy was performed and macroscopic evaluation revealed extensive blue-coloured masses on her face, neck, chest, abdominal wall, major and minor labium, and limbs. Similar lesions were also observed on the pericardium, liver, renal hilus and bladder. Microscopically, these lesions were composed of large, blood-filled spaces with a thin endothelial lining and were consistent with cavernous haemangiomas. There were two cystic lesions measuring 25 and 35 cm in diameter in the abdomen, one filled with blood and the other with serous fluid (figure 3). Microscopic examination of these lesions, which were lined by attenuated endothelium, disclosed lymphangioma and there were small lymphoid aggregates in the stroma (figure 4). The gastrointestinal tract was examined carefully but no similar lesions were found. There were no pathological findings in any other organs such as brain, lungs, heart and spleen.

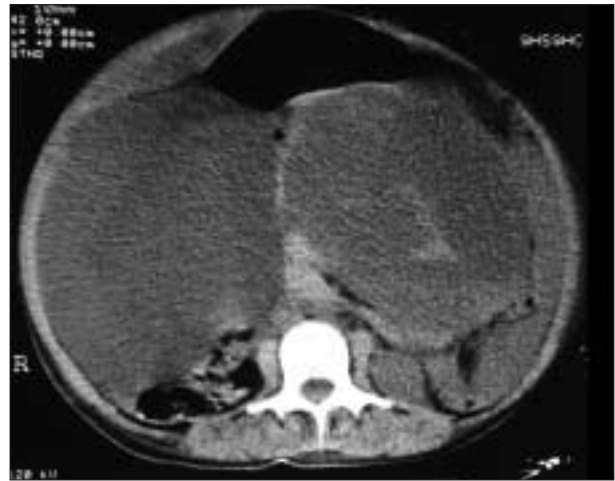

Figure 2
The abdominal CT of the patient, which was performed on the first day of hospitalisation, revealed two large cystic masses in the abdominal cavity

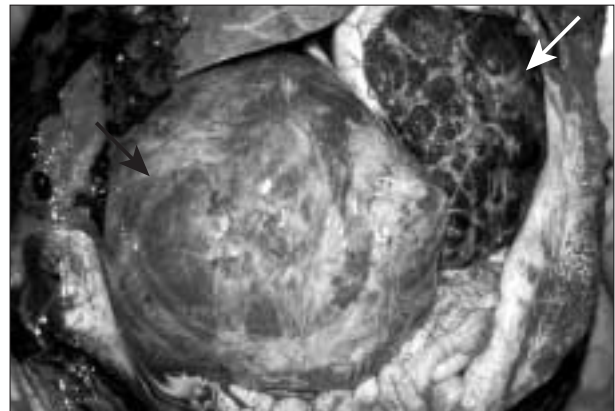


Figure 3
Two huge intra-abdominal lymphangiomas. One was filled with serous fluid (black arrow), the other with blood (white arrow).

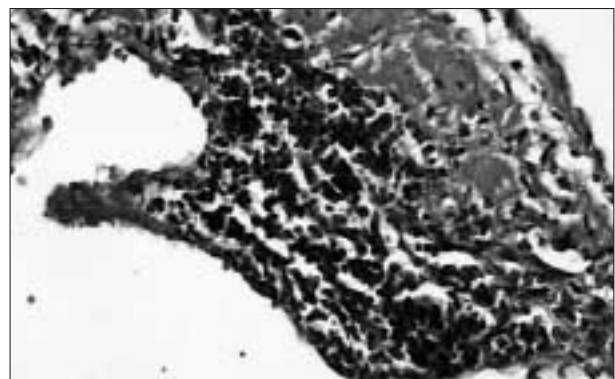


Figure 4
Lymphoid aggregates in the wall of lymphangioma (HE x 200)

DISCUSSION

Cavernous haemangioma is a benign vascular tumour usually found on skin and mucosal surfaces but it may involve any organ system.¹ Cavernous haemangiomas are found in two clinical conditions, namely Maffucci's syndrome and blue rubber bleb nevus syndrome (BRBNS). Maffucci's syndrome is characterised by bone fragility and multiple osteochondromas.³ BRBNS is an uncommon disorder which may demonstrate multiple, large, protruding cutaneous haemangiomas and gastrointestinal bleeding from vascular malformations. It is usually present at birth or early childhood but may also be seen in adulthood.^{3,4} Vascular anomalies are also described in other syndromes, such as Sturge-Weber syndrome (facial, ocular and intracranial vascular anomalies); Klippel-Trenaunay syndrome (capillary-lymphatic-venous malformations and limb gigantism); Parkes-Weber syndrome (capillary-lymphatic-arterial-venous malformations and limb gigantism); Bonnet-Dechaume-Blanc syndrome (visual system arteriovenous malformations); Cobb syndrome (arteriovenous malformations or fistula and spinal cord involvement); Solomon syndrome (capillary-lymphatic-venous malformations, limb gigantism, lipomas and epidermal nevi); and Proteus syndrome (capillary-lymphatic-venous malformations, macrodactyly, limb gigantism, macrocephaly, lipomas and epidermal nevi).⁵

One of the prominent findings in this case is the absence of gastrointestinal tract involvement in her necropsy while widespread haemangioma was observed throughout her body. At first glance the skin lesions together with the anaemia were suggestive of BRBNS in our patient, but lack of gastrointestinal tract involvement in her necropsy evaluation and no sign at all of gastrointestinal tract bleeding ante-mortem made the diagnosis of BRBNS unlikely. Other syndromes in which vascular malformations associated with various organ involvements could be excluded in this patient since she had no findings of accompanying manifestations.

At necropsy, she was found to have two intra-abdominal lymphangiomatous lesions. Coexistence of lymphangioma and haemangioma is another intriguing finding in the present case. It is often difficult to determine whether these lesions are true neoplasm, hamartoma or ectasia/malformation. At birth 50 to 65% of lymphangiomas are present, and nearly 90% of them may be manifest by the end of the second year of life.^{1,2} Intra-abdominal lymphangiomas are uncommon and generally occur in

childhood.⁶ Although most of the lymphangiomas are found in the head and neck area,⁷ intra-abdominal locations such as mesenteric area, omentum and retroperitoneum are also rarely observed.^{7,8} The lymphangiomas in the present case were mesenteric in origin and were diagnosed during post-mortem examination in spite of their huge sizes of 25 and 35 cm in diameter. This patient underestimated the minor signs, so the condition was not recognised early enough to enable surgical treatment of her abdominal cysts. Kasabach-Merritt syndrome may also be considered in this patient since she had multiple cavernous haemangiomas and the presentation of consumption thrombocytopenia and coagulopathy. Bleeding into cavernous haemangioma and lymphangioma probably caused the terminal event in this patient.

In conclusion, vascular malformations are sometimes not symptomatic until later in adulthood, even though they can reach huge sizes, and may lead to serious complications including sudden death. Any vascular malformation should therefore be considered for systemic evaluations at all stages in life. Our case seems to be unusual and rather rare because of its multiple features resembling different syndromes, and it can probably be placed somewhere in between the known syndromes, like an overlapping and as yet undescribed syndrome in the medical literature.

REFERENCES

1. Schoen FJ, Cotran RS. Blood vessels. In: Pathologic Basis of Disease. 6th ed. Cotran RS, Kumar V, Collins T (eds). Philadelphia: W.B Saunders, 1999:493-542.
2. Enzinger FM, Weiss SW. Soft Tissue Tumors. 3rd ed. St Louis: Mosby-Year Book, 1995:579-626.
3. Prieto VG, Shea CR. Selected cutaneous vascular neoplasms. A review. *Dermatol Clin* 1999;17(3):507-20.
4. Ward SK, Roenigk HH, Gordon KB. Dermatologic manifestations of gastrointestinal disorders. *Gastroenterol Clin North Am* 1998;27(3):615-36.
5. Burrows PE, Laor T, Paltiel H, Robertson RL. Diagnostic imaging in the evaluation of vascular birthmarks. *Dermatol Clin* 1998;16(3):455-88.
6. Singh S, Baboo ML, Pathak IC. Cystic lymphangioma in children: report of 32 cases including lesions at rare sites. *Surgery* 1971;69(6):947-51.
7. Yang CS, Wu MS, Wang HP, Shun CT, Lin JT. Disseminated cystic lymphangiomatosis presenting with acute abdomen: report of a case and review of the literature. *Hepatogastroenterology* 1999;46(25):196-8.
8. Hatada T, Ikeda H, Tanigawa A, Fujiwara Y, Hanada Y, Yamamura T. Lymphangioma of the colon: a case report and review of the Japanese literature. *Acta Gastroenterol Belg* 2000;63(2):239-41.