

Undulating blood pressure

I.M. Noppers, J.G. Zijlstra*

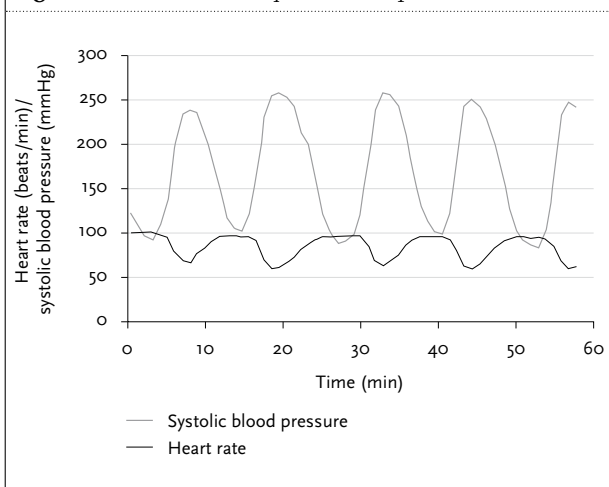
Department of Critical Care, University Medical Center Groningen, PO Box 30.001, 9700 RB Groningen, the Netherlands, *corresponding author: tel.: +31 (0)50-361 61 61, fax: +31 (0)50-361 32 16, e-mail: j.g.zijlstra@int.umcg.nl

CASE REPORT

A 58-year-old woman presented to another hospital with upper gastrointestinal bleeding. Her history was unremarkable except for hypertension, which was considered to be essential. Unexpectedly, upper gastrointestinal endoscopy revealed bleeding oesophageal varices. The patient stabilised but the blood pressure showed marked swings with hypotension and hypertension. After she developed abdominal symptoms, a laparotomy was performed. A small section of the jejunum had to be excised because of vena mesenterica thrombosis. Because of recurrent gastrointestinal bleeding she was referred to our hospital.

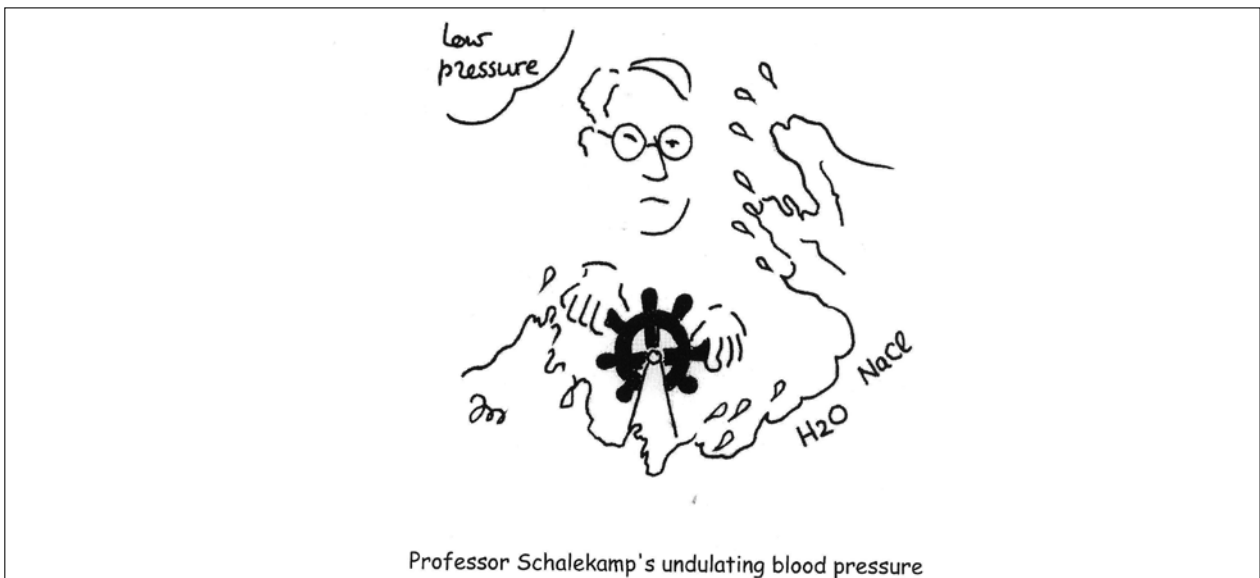
Endovascular volume was kept low to control bleeding. Blood pressure revealed cycles of 13 minutes of alternating hypertension and hypotension with bradycardia during hypertension (*figure 1*).

Figure 1. Heart rate and systolic blood pressure



WHAT IS YOUR DIAGNOSIS?

See page 214 for the answer to this photo quiz.



ANSWER TO PHOTO QUIZ (ON PAGE 212)

UNDULATING BLOOD PRESSURE

DIAGNOSIS

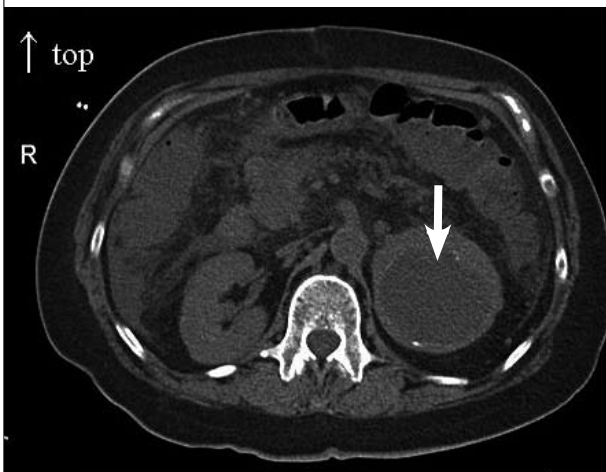
An abdominal computed tomography scan performed in the work-up of the abdominal symptoms revealed a mass cranial to the left kidney (*figure 2*). A pheochromocytoma was considered and treatment with labetalol resulted in a more or less stable blood pressure. After ligation of the varices, the bleeding was controlled and volume was replenished. The cycling disappeared resulting in stable hypertension controlled with labetalol and phenoxybenzamine. Urine and serum analyses showed elevated catecholamines and products of catecholamine metabolism. A metaiodobenzylguanidine (MIBG) scan was compatible with a pheochromocytoma in the left adrenal gland. Left adrenalectomy was performed and the diagnosis pheochromocytoma was confirmed on histology. After surgery, she remained normotensive without medication except for anticoagulation with coumarin. She is without symptoms to date. The varices were due to thrombosis of the portal vein without liver cirrhosis, probably related to a JAK-2

mutation. This also explained the thrombosis of the mesenteric vein.

Hypotension and hypertension alternating with this amplitude and frequency is very rare and is described almost exclusively in patients with pheochromocytoma.^{1,2} The mechanism is not clear.³ Alternating release and changing proportions of adrenaline, noradrenaline and dopamine has been suggested but is hard to prove. A returning phenomenon in all case reports is that patients showing this type of blood pressure cycling are hypovolaemic. All patients with pheochromocytoma tend to be hypovolaemic but the described patients had an additional cause of volume depletion. In our patient it was bleeding and intentional fluid restriction. In all described patients blood pressure could be controlled after administration of fluids. The high vascular tone due to the catecholamines is probably exaggerated by the hypovolaemia resulting in low vascular compliance. This might render the patients extremely sensitive to additional changes in volume and vasoactive substances.

In patients with this type of blood pressure cycling, pheochromocytoma should be considered and treatment is usually unsuccessful unless volume is replenished.

Figure 2. Upper abdominal CT scan with a mass in the left adrenal region (arrow)



REFERENCES

1. Ganguly A, Grim CE, Weinberger MH, Henry DP. Rapid cyclic fluctuations of blood pressure associated with an adrenal pheochromocytoma. *Hypertension* 1984;6(2 Pt 1):281-4.
2. Magnano AR, Bai D, Bloomfield DM. Cyclic Tachycardia and Hypotension. *Circulation* 2002;106:1-2.
3. Wenting CJ, Man in 't Veld AJ, Boomsma F, Schalekamp MA. Cyclic blood pressure changes in a patient with a pheochromocytoma: role of a central oscillator? *J Hypertens Suppl* 1985;3(3):S347-9.