

Measurement of leg blood pressure: the most straightforward way to the diagnosis

R. Gilles^{1*}, B.A.J. Veldman¹, W.R.M. Aengevaeren², L.J. Schultze-Kool³, A. van Oort⁴, J.W.M. Lenders¹

¹Department of Medicine, Division of General Internal Medicine, Departments of ²Cardiology, ³Radiology and ⁴Paediatric Cardiology, Radboud University Nijmegen Medical Centre, PO Box 9101, 6500 HB, Nijmegen, the Netherlands, *corresponding author: tel.: +31 (0)24-361 88 19, fax: +31 (0)24-354 17 34, e-mail: R.Gilles@nucmed.umcn.nl

ABSTRACT

Two adult patients with presumed primary hypertension are presented. In the first patient the diagnosis of coarctation of the aorta was straightforward while in the second patient there was a substantial delay in reaching the correct diagnosis.

A 32-year-old patient was analysed for hypertension in the outpatient clinic. At physical examination a systolic cardiac murmur was present and leg blood pressure was not measurable. Magnetic resonance imaging angiography showed a severe coarctation of the thoracic aorta with extensive distended collateral blood vessels. A second patient was a 31-year-old man referred with longstanding hypertension and an unsatisfactory blood pressure response to treatment. Previously, a diagnosis of primary hypertension was made. Renal computed tomography angiography excluded renal artery stenosis as a cause of hypertension but disclosed many distended collateral blood vessels in the musculus rectus abdominis and in the upper abdominal area. Leg blood pressure was measured and further analysis revealed a coarctation of the aorta.

Both patients illustrate and emphasise the importance of leg blood pressure measurement at a first analysis of adult hypertensive patients and should always be performed when hypertension is accompanied by murmurs or weak femoral pulsations.

KEYWORDS

Aortic coarctation, blood pressure determination, case reports

INTRODUCTION

Coarctation of the aorta is a rare cause of hypertension. It accounts for 5 to 7% of all congenital heart defects.¹ In most cases it is located immediately distal to the origin of the left subclavian artery at the site of the ductus arteriosus. Males are affected twice as often as females. Other cardiac malformations may be present and there is a prominent association with a bicuspid aortic valve in up to 80% of the patients.²

The exact prevalence of coarctation of the aorta in young and adult hypertensive patients is not exactly known. Since children with an isolated coarctation are usually asymptomatic except for hypertension, the diagnosis may be established later in life and can only be made if the femoral pulses are weak or if leg blood pressure is substantially lower than arm blood pressure. We present two adult hypertensive patients with a diagnosis of aortic coarctation. The first patient demonstrates that careful and complete physical examination will lead to a rapid diagnosis of the coarctation. The second patient demonstrates that the repeated omission of blood pressure measurement in the leg during physical examination will inevitably lead to a severely delayed diagnosis of coarctation of the aorta.

CASE REPORTS

Case report 1

The first patient was a 32-year-old male who presented at the outpatient clinic for analysis of untreated hypertension of approximately five-year duration. He was asymptomatic and had no other cardiovascular risk factors. In his family only his mother was known with hypertension. On physical examination, blood pressure was 162/92 mmHg (right arm) and 150/90 (left arm). Pulse rate was 80 beats/min.

A systolic murmur was heard with maximal loudness parasternally in the fourth intercostal space. No other murmurs were present. Arterial pulsations of the femoral artery and in the feet were weak but present. Blood pressure in the legs was so low that the resident in charge was unable to measure a reliable blood pressure value. Laboratory examination was unremarkable. Electrocardiography was normal without any signs of left ventricular hypertrophy. Echocardiography showed a bicuspid aortic valve. Because of the bicuspid aortic and the very low leg blood pressure, an magnetic resonance imaging (MRI) angiography of the thoracic aorta was performed. This examination confirmed the presumed diagnosis of a coarctation of the aorta with extensive distended collateral blood vessels. The patient was scheduled for balloon angioplasty with placement of an intravascular expandable stent.

Case report 2

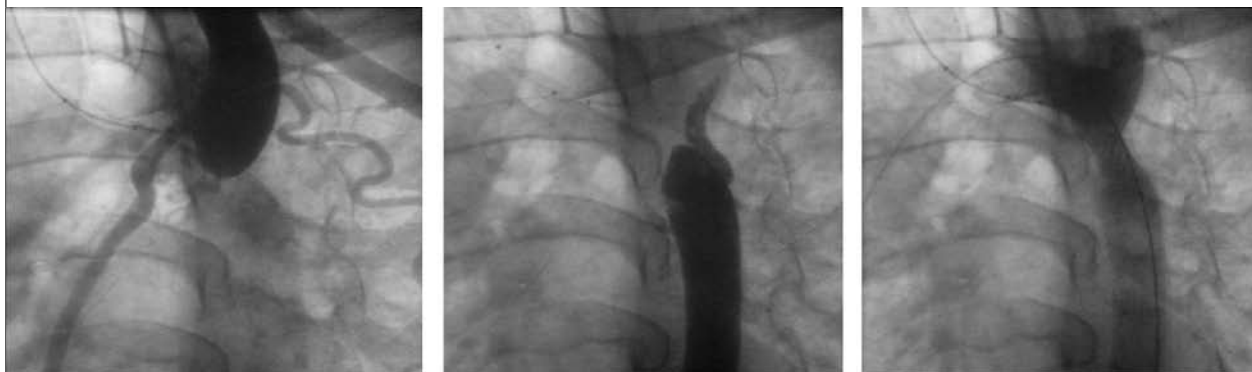The second patient, a 31-year-old man with hypertension, was referred to our department by his family physician in 2003 because of therapy-resistant hypertension. In 1990 he was diagnosed with hypertension and in 1998 a diagnosis of primary hypertension was made by an internist in another hospital. The patient was subsequently treated with captopril and hydrochlorothiazide. Apart from an occasionally occurring pressing sensation in his head he reported no other symptoms. No other risk factors for cardiovascular disease were present. The family history was negative for renal disease, diabetes or cardiovascular disease except for his grandmother who had hypertension. His medical history only revealed a traumatic contusion of the left brachial plexus in 1988. On examination, blood pressure was 160/100 mmHg with a pulse rate of 70 beats/min. A systolic murmur was heard over all cardiac areas with maximal loudness at the second intercostal space on the left and in the neck. No murmurs were present over the abdominal and femoral arteries. The arterial pulsations in the feet were noted as normal but the presence of the femoral pulses was not described on the chart.

The results of the routine laboratory examinations were unremarkable. After stopping his antihypertensive drugs for two weeks, plasma aldosterone and renin concentrations were within normal limits. After administration of 50 mg captopril, plasma renin rose from 32 mE/l to 114 mE/l, which raised the suspicion of renal artery stenosis. An electrocardiogram showed a regular sinus rhythm with negative T waves in leads III and AVF and pathological Q waves in I and AVL. Echocardiography excluded left ventricular hypertrophy but disclosed a bicuspid aortic valve. At renal computed tomography (CT) angiography, the renal arteries were patent without any stenosis but extensive distended collateral blood vessels were observed in the musculus rectus abdominis and in the upper abdominal area. This finding raised the suspicion of a more proximal aortic flow obstruction such as an aortic coarctation. Re-examination of the patient showed that the femoral pulses were weak and that arm systolic blood pressure amounted to 154 mmHg while this was only 104 mmHg in the leg. Additionally, he reported that as a child, he had always had fitness problems with various sport activities such as jogging, soccer and field hockey. In contrast, he could perform in gymnastics very well. This disparity fits with the final diagnosis of coarctation of the aorta which was definitely established by CT angiography of the thoracic aorta. The patient was scheduled for balloon angioplasty with placement of an intravascular expandable stent (*figure 1*).

DISCUSSION

In the general population, only 5% of patients with hypertension have an underlying disorder causing the hypertension. The younger the patient, the higher the chance of secondary hypertension. Of all causes of secondary hypertension, the prevalence of coarctation of the aorta in adult patients in the primary care setting is probably less than 0.2%.³

Figure 1. Antegrade (left panel) and retrograde (middle panel) angiography of the thoracic aorta was necessary due to the pinpoint stenosis of the severe aortic coarctation, right panel shows the aorta after expandable stent placement



Although this might be higher in secondary or tertiary referral centres, it is still an extremely rare cause of hypertension. Yet, an early diagnosis is important because if left undiagnosed and untreated, premature cardiovascular accidents such as heart failure and rupture of the aorta may develop at a young age. Life expectancy is considerably reduced and 70 to 90% of the untreated patients die before the age of 50 years.^{4,5}

The clinical manifestations of coarctation may vary between individuals and are highly dependent on the degree of the aortic obstruction and the presence of associated anomalies such as a bicuspid aortic valve.⁶ Many adult patients may be asymptomatic except for hypertension and its related symptoms such as headache. The principal clinical signs leading to an early diagnosis are weak femoral pulses and a lower systolic blood pressure in a leg as compared with that in the arm (difference >20 mmHg). Since coarctation is frequently associated with extensive collateral circulation, cardiac murmurs originating at the upper sternum with bilateral radiation to the back are often heard. On a chest radiograph, notching of several posterior ribs can be seen, due to the increased collateral flow through the intercostal arteries (*figure 2*).

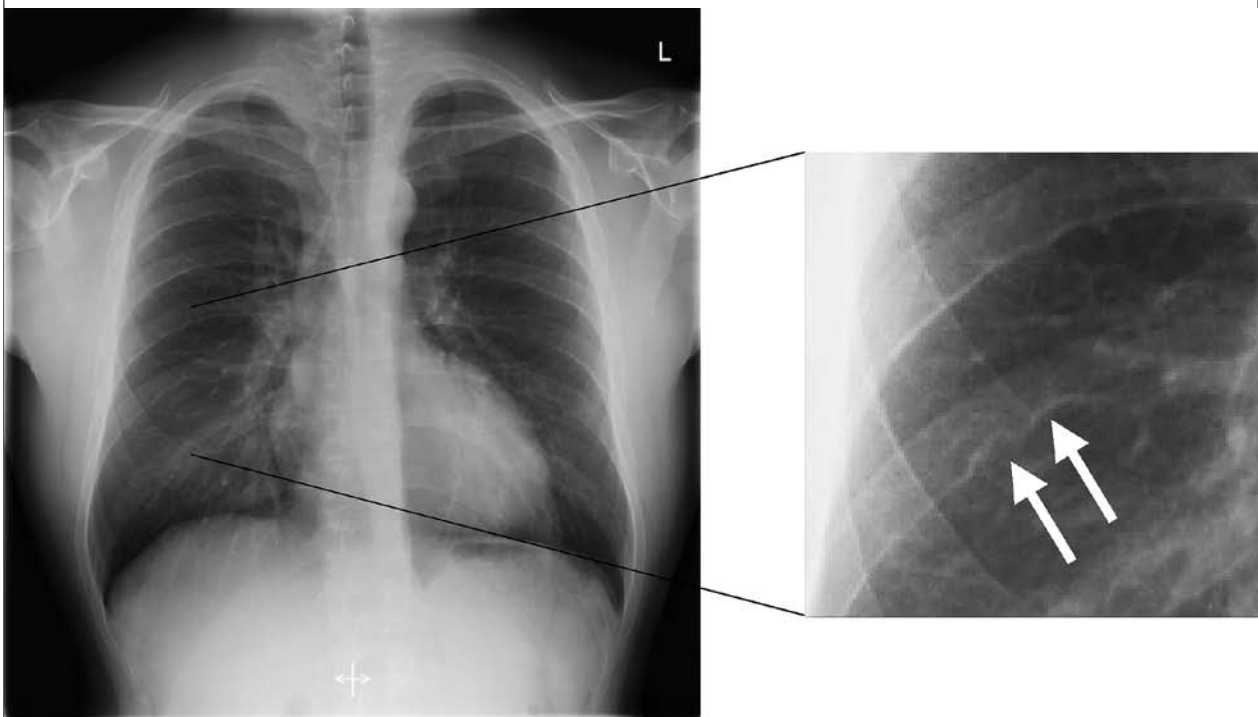
Echocardiography with colour Doppler flow mapping can be used to estimate the degree of stenosis and it facilitates screening for other cardiac anomalies such as a bicuspid aortic valve. To obtain precise anatomical information and to visualise the collateral vessels, CT angiography or magnetic resonance angiography can be used.⁷

Primary treatment of coarctation is repair by either surgery or balloon angioplasty alone or with placement of an expandable intravascular stent. Although surgery and angioplasty are both successful, a higher incidence of aneurysm formation has been reported with angioplasty.⁸ A previous study by Zabal *et al.* suggested a better outcome and lower risk of aneurysm formation when a stent was used during angioplasty.⁹ Carr *et al.* also found a higher incidence of recurrence and reintervention rates after endovascular therapy.¹⁰ Additionally a recent study by Oliver did not find a significant difference in the prevalence of aortic complications with patients treated by surgery or patch graft aortoplasty.¹¹ However, large series of patients treated with angioplasty with or without stent placing are lacking. Therefore the role of primary balloon angioplasty with or without placement of a stent remains unsettled.

Recoarctation, paracoarctation aneurysm, and endocarditis are the major long-term complications of repair.¹² Although after successful repair blood pressure falls in the long term, the prevalence of hypertension remains high (33 to 42%) if surgery is performed after the age of 14 years.^{13,14} Both our patients had a decrease in blood pressure after stent placement. Our first patient is still on 50 mg metoprolol and at his last visit his blood pressure was 140/80 mmHg. Our second patient is still normotensive and off drug treatment two years after stenting of the aorta.

Survival after repair is influenced by the age of the patient at the time of surgery and is independently related to the coexistence of a bicuspid aortic valve. Survival rate decreases

Figure 2. Chest X-ray showing the rib notching on the right side (arrows)



with older age at the time of repair but even in adult patients correction should be carried out as soon as possible.¹⁵

In our patients who presented with hypertension, the total delay until the definite diagnosis amounted to five and 13 years, respectively. More importantly, the essential signs of a coarctation were not disclosed because of repeatedly deficient physical examinations. Unfortunately, this is not at all unusual.¹⁶ In the first case, the patient insisted on specialist referral whereas the family physician wanted to initiate medical treatment for hypertension. Measurement of blood pressure in a leg would have raised the suspicion of a coarctation as a cause of the high blood pressure. Also the presence of the cardiac murmur should have been a compelling reason for specialist referral. This could have prevented the five-year delay of the diagnosis and appropriate treatment. The combined finding of a cardiac murmur and the very low blood pressure in the legs resulted in a fast and correct diagnosis.

The second patient illustrates that even the finding of a cardiac murmur and a bicuspid aortic valve did not lead to the proper diagnostic direction in a third referral centre. Due to nonadherence to our own diagnostic protocol, measurement of leg blood pressure was omitted by the resident who saw the patient initially in our clinic, causing another delay of nine months. Leg blood pressure measurement would certainly have pointed to the correct diagnosis.

Measurement of both leg and brachial systolic blood pressure is a mandatory step in the initial evaluation of every young patient (<50 years) with unexplained hypertension especially when murmurs or weak femoral pulsations are present. Although aortic coarctation is a rare condition, the crucial physical diagnostic step leading to a diagnosis is not only easy and patient-friendly but also cheap. If leg blood pressure is less than 20 mmHg lower than arm blood pressure, a coarctation of the aorta is extremely unlikely. Conversely, if leg blood pressure is more than 20 mmHg lower than brachial blood pressure, a diagnosis of coarctation of the aorta should be considered immediately since early and appropriate treatment of this cause of hypertension does improve life expectancy by reducing premature cardiovascular complications.

However, despite this improved therapy, life expectancy remains less than that of the general population.

REFERENCES

1. Blackfold LM. Coarctation of the aorta. *Arch Intern Med* 1928;41:702-35.
2. Vriend JWJ, Mulder BJM. Aortic coarctation: the need for lifelong surveillance. *Neth Heart J* 2003;11:514-8.
3. Rudnick KV, Sacket DL, Epid MSc, Hirst S, Holmes C. Hypertension in family practice. *Canad Med Ass J* 1977;117:492-7.
4. Bobby JJ, Emani JM, Farmer RD, Newman CG. Operative survival and 40 year follow-up of surgical repair of aortic coarctation. *Br Heart J* 1991;65:271-6.
5. Campbell M. Natural history of coarctation of the aorta. *Br Heart J* 1970;32:633-40.
6. Bashmore T, Lieberman E. Aortic/mitral obstruction and coarctation of the aorta. *Cardiol Clin* 1993;11:617-41.
7. Brickner ME, Hillis LD, Lange RA. Congenital heart disease in adults: first of two parts. *N Engl J Med* 2000;342:256-63.
8. Cowley CG, Orsmond GS, Feola P, McQuillan L, Shaddy RE. Long-term, randomized comparison of balloon angioplasty and surgery for native coarctation of the aorta in childhood. *Circulation* 2005;111:3453-6.
9. Zabal C, Attie F, Rosas M, Buendía-Hernández A, García-Montes JA. The adult patient with native coarctation of the aorta: balloon angioplasty or primary stenting? *Heart* 2003;89:77-83.
10. Carr JA. The results of catheter-based therapy compared with surgical repair of adult aortic coarctation. *J Am Coll Cardiol* 2006;47:1101-7.
11. Oliver JM, Gallego P, Gonzalez A, Aroca A, Bret M, Mesa JM. Risk factors for aortic complications in adults with coarctation of the aorta. *J Am Coll Cardiol* 2004; 44:1641-7.
12. Stewart AB, Ahmed R, Travill CM, Newman CG. Coarctation of the aorta life and health 20-44 years after surgical repair. *Br Heart J* 1993;69:65-70.
13. Cohen M, Fuster V, Steel PM, Driscoll D, McGoon DC. Coarctation of the aorta: Long-term Follow-up and prediction of outcome after surgical correction. *Circulation* 1989; 80:840-5.
14. Ozkokeli M, Sensoz Y, Gunay R, et al. Blood pressure changes after aortic coarctation surgery performed in adulthood. *J Card Surg* 2005;20:319-21.
15. Brouwer RMJ, Erasmus M, Ebels T, Eijgelaar A. Influence of age on survival, late hypertension, and recoarctation in elective aortic coarctation repair with a follow-up from 25 to 44 years. *J Thoracic Cardiovasc Surg* 1994;108:525-31.
16. Hoffman JI, Kaplan S. The incidence of congenital heart disease. *J Am Coll Cardiol* 2002;39:1890-900.