

## *Yersinia enterocolitica* O:3 mesenteric lymphadenopathy in an apparently healthy adult

Dear Sir,

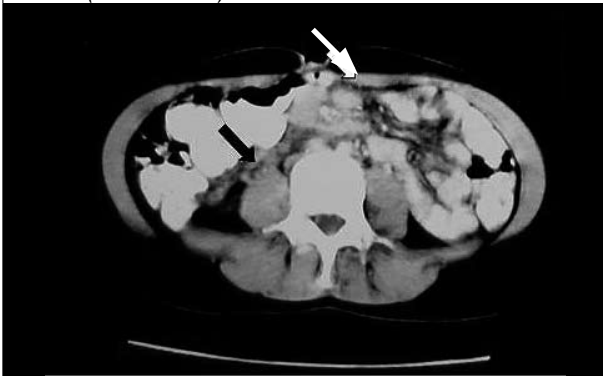
*Yersinia enterocolitica*, a Gram-negative aerobic bacterium, is associated with various clinical manifestations, including acute gastroenteritis, abdominal pain, fever, weight loss, fatigue and, occasionally, mesenteric lymphadenopathy.<sup>1,2</sup> Important serotypes for human pathology are O:3, O:5, O:8, O:9 and O:27. These infections have usually been reported in patients with haematological diseases, such as thalassaemias, sickle cell disease and haemochromatosis.<sup>1,3</sup>

We recently observed a case of *Yersinia enterocolitica* infection, without gastrointestinal symptoms, in an apparently healthy 19-year-old female. The patient suffered from fever for 20 days, usually in the evening, and complained of fatigue, loss of appetite and significant weight loss. History and physical examination were unremarkable; laboratory investigation revealed anaemia, leucocytosis and elevated inflammatory indices. Blood and urine cultures were negative, as was serology for certain pathogens. Computed tomography (CT) of the abdomen revealed liver-spleen enlargement and mesenteric lymphadenopathy with 'sandwich sign', indicative for non-Hodgkin lymphoma (figure 1). Histopathology showed that lymphadenopathy was reactive, possibly due to infection with no signs of malignancy. Twenty days later, under second-generation

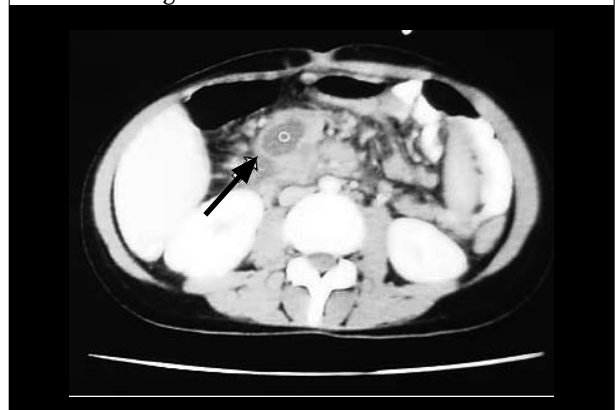cephalosporins, the patient presented with an acute abdomen; CT additionally revealed abscess formation in the right mesenteric region (figure 2). Repeated laparotomy was performed; histopathology showed infiltrates of neutrophils, histiocytes, eosinophils, plasma cells and giant cells indicating reactive lymphadenopathy, due to *Yersinia enterocolitica* or pseudotuberculosis. Serology confirmed *Yersinia enterocolitica* type O:3 infection. The patient was given ciprofloxacin 500 mg/twice daily for 20 days and recovered completely.

*Yersinia enterocolitica* is transmitted via the enteric route or by direct inoculation through blood transfusions.<sup>1</sup> Iron overload diseases and desferrioxamine favour *Yersinia* by providing the necessary iron for bacterial growth; these patients have a higher possibility of septicaemia.<sup>4</sup> Symptomatology may mimic acute appendicitis, Crohn's disease, ileum perforation or lymphoma. Further manifestations include reactive arthritis, especially in HLA-B27 positive individuals. Diagnosis is based on positive cultures of biological specimens. Serology may detect O:3 and O:9 serotypes, responsible for more than 90% of *Yersinia* infections in Europe; these serotypes have been proven resistant to penicillins and second-generation cephalosporins. Fluoroquinolones and third-generation cephalosporins are effective, while combinations with aminoglycosides or trimethoprim-sulfamethoxazole have

**Figure 1.** Computed tomography of the abdomen revealed mesenteric lymphadenopathy with the 'sandwich sign', indicative of non-Hodgkin lymphoma (white arrow) and lymph nodes around the terminal ileum (black arrow)



**Figure 2.** Twenty days later, a block of pathological lymph nodes, hepatosplenomegaly and abscess formation (white arrow) were observed in the right mesenteric region



been successfully used in septicaemia; surgical treatment is required for rare complications.<sup>1,4</sup>

*Yersinia enterocolitica*-related mesenteric lymphadenopathy with no gastrointestinal symptoms in this apparently healthy adult is considered to be extremely unusual. However, *Yersinia enterocolitica* should be included in the differential diagnosis of atypical abdominal symptoms combined with mesenteric lymphadenopathy.

**E. Vlachaki\***, K. Tselios, A. Tsapas, J. Klonizakis

Haematology Unit, 2nd Department of Internal Medicine, Hippokraton General Hospital, Aristotelian University of Thessalonica, Greece, \*corresponding author: tel: +30 2310-89 22 87, fax: +30 2310-99 27 94, e-mail: efvlachaki@yahoo.gr

## REFERENCES

1. Bottone EJ. *Yersinia enterocolitica*: the charisma continues. Clin Microbiol Reviews 1997;10:257-6.
2. Trommer G, Bewer A, Kosling S. Mesenteric lymphadenopathy in *Yersinia enterocolitica* infection. Radiologe 1999;38:37-40.
3. Robins-Browne RM, Prpic JK. Effects of iron and desferrioxamine on infections with *Yersinia enterocolitica*. Infect Immun 1985;47:774-9.
4. Pallister C, Rotstein OD. *Yersinia enterocolitica* as a cause of intra-abdominal abscess: the role of iron. Can J Surg 2001;44:135-6.