

Open biopsy: the ultimate test for pulmonary embolism

C.P. Schönhuth¹, H.G. Bosman², P.H.M. van der Valk³, J.L.M. Krijnen⁴, P.W. Plaisier^{1*}

Departments of ¹Surgery, ²Pulmonology, ³Radiology and ⁴Pathology, Albert Schweitzer Hospital, Dordrecht, the Netherlands, *corresponding author: tel.: +31 (0)78-654 11 11, fax : +31 (0)78-654 22 64, e-mail: p.w.plaisier@asz.nl

KEYWORDS

CT angiography, pulmonary embolism, surgical biopsy

INTRODUCTION

Pulmonary embolism (PE) affects 0.5 to 1 per 1000 people in the general population each year and is one of the most common preventable causes of death among hospital inpatients.¹ The overall mortality rate of PE is high with approximately 15% at three months.² Although anticoagulant therapy is highly effective in preventing death, it is frequently either not administered, or administered too late, because the diagnosis of PE has not been entertained.³

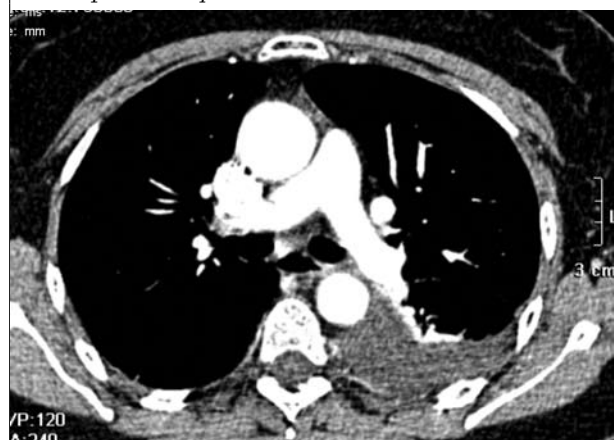
The diagnosis of PE remains difficult because the symptoms are not specific and all the available tests have substantial limitations. Computed tomography angiography (CTA) is readily available at most institutions and is rapidly becoming the first-line imaging test for the assessment of patients with suspected acute PE.⁴ This case illustrates that also CTA has its false-negative results and how the diagnosis PE can be established alternatively.

CASE REPORT

A 58-year-old woman was admitted to our hospital because of severe chest pain and progressive shortness of breath for one week. Her medical history showed hypertension, constipation, diverticulitis, and Raynaud's phenomenon. At presentation, she had no fever and physical examination showed no abnormalities. Routine blood examination revealed high serum levels of C-reactive protein (35; normal < 10 mg/l), a normal leucocyte count and a normal troponin I level. The D-dimer assay (D-dimer Cardiac Reader; Roche Diagnostics GmbH, Germany) was negative. The electrocardiogram was normal and the chest X-ray

showed some left-sided pleural effusion with minor atelectasis. The clinical suspicion of PE was considered moderate (i.e. '3' on the modified score) according to the criteria of Wells *et al.*⁵ and an additional multislice CTA was performed. It confirmed the left-sided pleural effusion and showed no other abnormalities and no direct signs of PE (figure 1).⁶ CTA was performed on a four detector row CT scan (Siemens Volume Zoom, Erlangen, Germany), 1.25 collimation, increment 0.6. The scan was obtained in a caudal to cranial direction during suspended inspiration with an automated bolus triggering technique using a 120 ml bolus of contrast agent (Ultravist 300, Schering, Germany), injected at 4 ml/sec. As there were no direct signs of PE, the heparin (Fragmin) was stopped. The patient was treated for a urinary tract infection (*E. coli*) and was discharged from hospital after being admitted for seven days.

Figure 1. Pulmonary CTA showing no filling defects in the pulmonary vasculature



There is pleural fluid located dorsally on the left side together with partial atelectasis of the left lower lobe.

After being home for only three days, she was readmitted in a very poor condition with progressive dyspnoea. Chest X-rays showed a large amount of pleural effusion, again on the left side. Despite extensive examination (CTA of the chest, bronchoscopy, pleural puncture, rheumatoid arthritis serology, ANA and ENA determination, tuberculosis cultures, serology for *Mycoplasma pneumoniae* and *Chlamydia pneumoniae*) no cause was found for this exudative pleuritis. It was not until after these diagnostic tests that the pleural effusion was drained and flushing of the pleural cavity with streptokinase was started.

Furthermore, intravenous antibiotics (Augmentin) were given. She soon recovered and routine chest X-rays showed further improvement. The drains were removed and the patient could leave the hospital after 19 days in a good clinical condition.

After being back home for 80 days she became ill again, showing the same symptoms that she had had before. She was admitted to hospital for the third time, one week after the start of symptoms. Also this time, extensive examination (including CTA) was performed and the cause of this left-sided pleural effusion could not be found. Because of the repeated character of the disease we decided to perform a thoracotomy for pleural drainage and open biopsy of lung and pleura. Excision biopsies of the left upper and lower lobe both revealed wedge-shaped subpleural infarctions explaining the pleural effusion. Some arteries showed intimal thickening and in one artery signs of an old thromboembolus with organisation and recanalisation was found (figures 2 and 3). The pleural surface of the involved area was covered with fibrin. A biopsy of the parietal pleura showed chronic inflammation and fibrin deposition. The patient received analgesics and oral anticoagulation (acenocoumarol) and could soon leave the hospital. On ambulatory check-ups her recovery was favourable. She had not encountered any further episodes

of chest pain or dyspnoea. Additional blood tests for coagulopathy, including plasma homocysteine levels and lupus anticoagulans, did not reveal any abnormalities. After six months, the anticoagulation therapy was stopped.

DISCUSSION

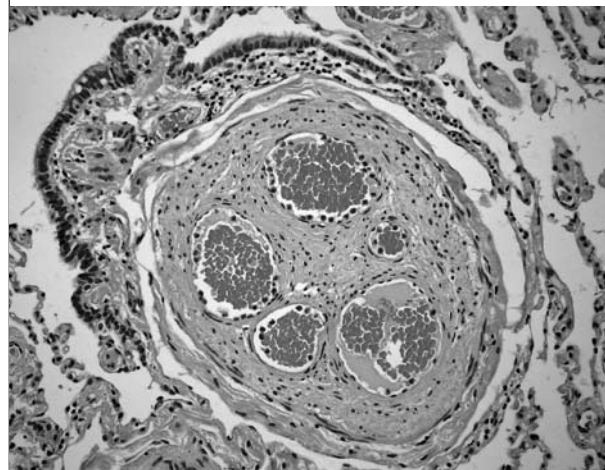
Because there are no specific diagnostic clinical features of PE, the role of the clinical assessment is to formulate the patients presenting symptoms and signs into an estimate of the probability of PE.³ Wells *et al.*⁵ developed a simple clinical model to predict the probability of PE that is implemented in our diagnostic work-up of patients with suspected PE.

Laboratory tests are helpful to establish an alternative diagnosis or to exclude the diagnosis PE. The role of D-dimer testing in patients with suspected PE is to exclude the diagnosis: normal concentrations of D-dimer have a high negative predictive value for PE, particularly in patients with a low clinical probability.^{6,7} If the D-dimer result in that group is negative, diagnostic imaging is not required and it is safe to withhold treatment, as the three-month cumulative incidence of subsequent venous thromboembolism in untreated patients is low (0.5%).³ Contrast pulmonary angiography is the traditional reference test for the diagnosis PE, but is rarely used: it is invasive (thus associated with morbidity and mortality), requires a high level of expertise, and is not widely available.⁸ So, ventilation-perfusion (V-P) scanning or CTA are generally performed instead, for the confirmation or exclusion of PE. Studies have shown that CTA, especially multislice, has greater discriminatory power than V-P scanning.^{6,8} Furthermore, in up to 65% an alternative diagnosis can be made by CTA when PE is not present as other structures such as lung parenchyma and mediastinum are visualised as well.⁶

Figure 2. Lung tissue infarcted on the left side, vital tissue on the right side (H&E staining)

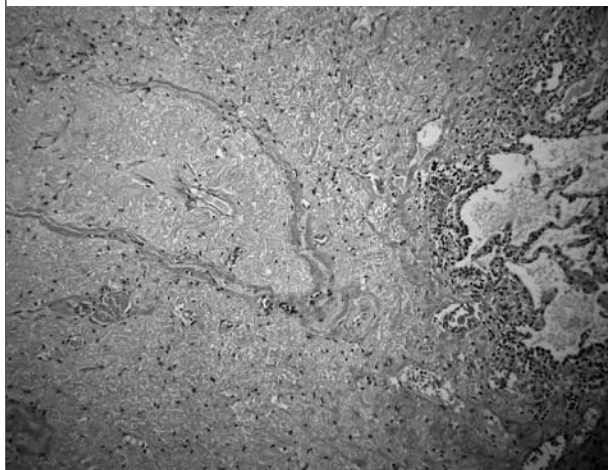

Figure 3. Cross-section of an artery with an old thrombus with recanalisation (H&E staining)



Although the patient in this case had a low probability for PE with a negative D-dimer test, an additional CTA was performed. Because pleural effusion and atelectasis are only indirect and nonspecific signs of PE, the diagnosis of PE could not be confirmed on either of the three CT angiograms. As the patient did not have clinical signs of a deep venous thrombosis and the additional value of serial ultrasonography of the legs is low,⁹ ultrasonography was not performed. Catheter pulmonary angiography was not considered in this patient, since CTA was thought to be conclusive because of the excellent quality of the images. Moreover, catheter angiography is invasive, carries risks and also has its false-negative results: after a negative catheter angiography fewer than 2% of patients develop PE. In fact, these results are in the same range as reported after a negative CTA.^{10,11}

Finally, diagnosis of PE was made by histopathological examination of an open biopsy. As small peripheral PE could have been missed on the first reading, all CT angiograms were reviewed by an experienced radiologist who was aware of the results of the lung biopsy. Nevertheless, all scans were still considered negative for PE.

To our knowledge, no other similar cases have been published to date. We suggest that, as a last resort, biopsy by video assisted thoracoscopy (VATS) or thoracotomy is a viable option for patients with persistent pulmonary illness without a definite diagnosis.

POSTSCRIPT

After writing this manuscript the patient was readmitted to the hospital with the same symptoms as before, two months after she had stopped taking oral anticoagulation. On this occasion, CTA did confirm the diagnosis of PE. Consequently, she is on lifelong anticoagulation therapy.

ACKNOWLEDGEMENT

The authors wish to thank Dr I.J.C. Hartmann, radiologist (Erasmus Medical Centre, Rotterdam, the Netherlands), for her assistance in preparing the manuscript.

REFERENCES

1. Silverstein MD, Heit JA, Mohr DN, Petterson TM, O'Fallon WM, Melton LJ. Trends in the incidence of deep vein thrombosis and pulmonary embolism: a 25-year population-based study. *Arch Intern Med* 1998;158:585-93.
2. Goldhaber SZ, Visani L, De Rosa M. Acute pulmonary embolism: clinical outcomes in the International Cooperative Pulmonary Embolism Registry (ICOPER). *Lancet* 1999;353:1386-9.
3. Lee CH, Hankey GJ, Ho WK, Eikelboom JW. Venous thromboembolism: diagnosis and management of pulmonary embolism. *Med J Aust* 2005;182:569-74.
4. Schoepf UJ, Goldhaber SZ, Costello P. Spiral computed tomography for acute pulmonary embolism. *Circulation* 2004;109:2160-7.
5. Wells PS, Anderson DR, Rodger M, et al. Excluding pulmonary embolism at the bedside without diagnostic imaging: management of patients with suspected pulmonary embolism presenting to the emergency department by using a simple clinical model and D-dimer. *Ann Intern Med* 2001;135:98-107.
6. Remy-Jardin M, Remy J. Spiral CT Angiography of the pulmonary circulation. *Radiology* 1999;212:15-36.
7. Kelly J, Hunt BJ. A clinical probability assessment and D-dimer measurement should be the initial step in the investigation of suspected venous thromboembolism. *Chest* 2003;124:1116-9.
8. Goldhaber S. Pulmonary embolism. *Lancet* 2004;363:1295-305.
9. Mayo JR, Remy-Jardin M, Muller NL, et al. Pulmonary embolism: prospective comparison of spiral CT with ventilation-perfusion scintigraphy. *Radiology* 1997;205:447-52.
10. Van Strijen MJ, de Monye W, Schiereck J, et al. Single-detector helical computed tomography as the primary diagnostic test in suspected pulmonary embolism: a multicenter clinical management study of 510 patients. *Ann Intern Med* 2003;38:307-14.
11. Patel S, Kazerooni EA. Helical CT for the evaluation of acute pulmonary embolism *Am J Roentgenol* 2005;185:135-49.

