

# An itchy holiday

C. van Nispen tot Pannerden<sup>1\*</sup>, F. van Gompel<sup>2</sup>, B.J. Rijnders<sup>1</sup>, E. Caumes<sup>3</sup>, J.G. den Hollander<sup>1,4</sup>

<sup>1</sup>Department of Internal Medicine, Infectious Diseases section, Erasmus Medical Centre, Rotterdam, the Netherlands, <sup>2</sup>Department of Tropical Medicine, Institute for Tropical Medicine, Antwerp, Belgium, <sup>3</sup>Department of Infectious and Tropical Diseases, Hôpital Pitié-Salpêtrière, Paris, France, <sup>4</sup>Department of Internal Medicine, Medical Centre Rijnmond Zuid, Rotterdam, the Netherlands, \*corresponding author: tel.: +31 (0)10-291 23 76, e-mail: cmf@vannispentotpannerden.nl

## ABSTRACT

A 33-year-old Dutch woman developed itchy skin lesions during a beach holiday in Thailand. She was treated for various diagnoses, without success. Finally she was successfully treated for a clinically suspected hookworm-related folliculitis. A brief overview of hookworm-related folliculitis is given.

## KEYWORDS

Cutaneous larva migrans, folliculitis, hookworm, parasitic

## INTRODUCTION

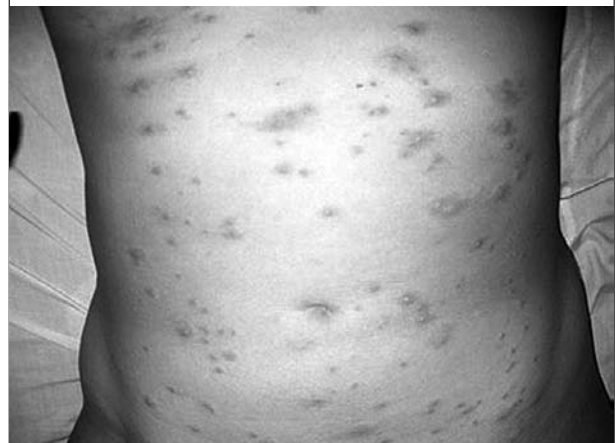The ever-increasing frequency of travel to tropical and subtropical destinations results in an equal rise in imported diseases. Therefore, physicians with little knowledge of 'tropical diseases' will also occasionally encounter these imported diseases. This case illustrates an unusual presentation of an infection frequently acquired on tropical beaches.

## CASE REPORT

A 33-year-old woman from the Netherlands developed an itchy rash on her trunk and upper legs during her stay in Thailand, where she enjoyed a beach holiday in October. On the first day of her holiday she had been lying on a sandy beach without a towel. She did not recall any insect bites or stings. During the following days she developed an increasing number of small papules of  $\pm$  3mm in diameter, which changed colour from bluish to red and became

increasingly itchy. She had no medical or dermatological history and was not taking any medications. Her partner was unaffected. She visited a local medical institution for her symptoms and was treated with antibiotics (amoxicillin/clavulanic acid) and an H1-receptor blocker without effect. Four weeks later, after returning to the Netherlands, she was seen by her general practitioner (GP) because of persisting itchy abdominal and submammary erythematous papules, with purpuric lesions (*figure 1*). As the GP suspected scabies, he treated her with lindane, but without success. The patient was therefore referred to a dermatologist. Laboratory investigations at that time revealed a leucocyte count of  $15.2 \times 10^9/l$  (reference value 4.3-10.0), eosinophils 44% (0-5%), Hb 8.3 mmol/l (7.5-10.0), aspartate transaminase 43 IU/l ( $<31$  IU/l), alanine aminotransferase ( $<31$  IU/l) and IgE titre 169 kU/l ( $<100$  kU/l). Her faeces were tested for parasites, which revealed a hookworm infection.

**Figure 1.** This figure shows the abdomen of our patient approximately two weeks after the infection at the beach



A skin biopsy showed eosinophilic infiltrates with no microorganisms. The follicular canal did not seem to be affected. The results were interpreted at that time as eosinophilic invasion of the skin as the consequence of a hookworm infection and she was treated with mebendazole.

As the skin lesions had not improved after three to four weeks and she continued to complain of severe itching and progressive fatigue, she was referred to the department of infectious diseases. She was seen three months after onset. Physical examination at that time revealed pink to red papular and pustular lesions, mainly localised in the pubic region, trunk and breasts. No creeping dermatitis was seen within these cutaneous lesions. A repeated stool test did not show hookworm.

Clinically she was suspected of hookworm folliculitis and she was treated with albendazole at a daily dose of 1000 mg for five consecutive days. The pruritic lesions disappeared slowly within two weeks.

## DISCUSSION

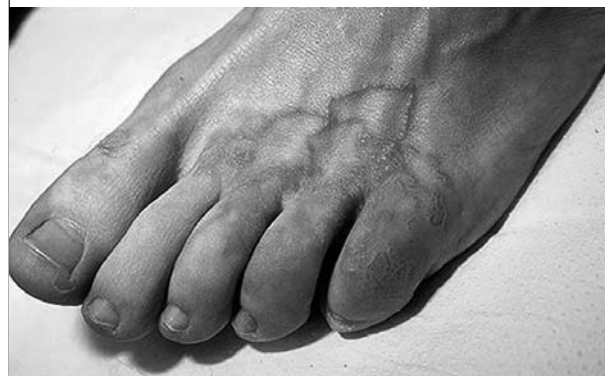Hookworm folliculitis is an uncommon clinical form of hookworm-related cutaneous larva migrans (HCLM).<sup>1</sup> It is one of the most common acquired tropical dermatoses. It is usually associated with a creeping eruption but it may also give rise to folliculitis, mostly located on the buttocks.<sup>1,3</sup> Even though the causative parasite may be similar, the response to classical treatment is less prompt. The majority of cases of HCLM are caused by cutaneous hookworm infestation. The human species is an accidental host. Typically larvae of the animal (cat or dog) hookworm *Ancylostoma braziliense* are the cause. Other animal hookworms of the *Ancylostomidae* family (*A. caninum*, *A. duodenale*) may cause similar pictures. Other parasitic causes, such as *Uncinaria stenocephala*, *Bunostomum phlebotomum*, *Strongyloides stercoralis* (larva currens), *S. procyonis*, *Gnathostoma spinigerum*, *Spirurina* spp., *Fasciola gigantica* and *Dirofilaria repens* may also cause creeping eruptions whereas *Pelodera strongyloides* has been associated with hookworm folliculitis.<sup>1</sup>

Eggs are excreted in feline or canine faeces and hatch in the soil. Contaminated soil is typically found in (sub)tropical climates. In these areas the larvae are found on sandy beaches, in sandpits and under dwellings. Infestation occurs when the filariform larvae penetrate the human skin and migrate between the stratum germinativum and stratum corneum.<sup>4,5</sup> Several days after penetration severely itchy cutaneous lesions appear. Typically HCLM clinically presents as a creeping eruption with an erythematous linear or serpiginous tract with extreme pruritis.<sup>1</sup> In other cases, many larvae may penetrate the skin simultaneously and cause multiple itchy follicular papules and pustules,

as in our patient. An eosinophilic inflammatory reaction occurs, which causes the erythematous aspect of the lesion. The histological picture only rarely reveals the causative larvae in HCLM. In hookworm folliculitis, the histological aspect is characteristic by showing an eosinophilic folliculitis due to an inflammatory reaction to the presence of larvae trapped within the follicular canal.<sup>1,6</sup> Histological confirmation, however, often fails.<sup>2</sup> Only a few cases of hookworm folliculitis have been reported in the literature and the largest series includes seven cases.<sup>1,3,7</sup> Hookworm folliculitis should be recognised as one of the less typical presentations of HCLM. Although the disease is self-limiting, many infested patients require treatment to reduce the often debilitating symptoms, and to prevent or treat superinfection. Treatment for cutaneous larva migrans consisted of local application of thiabendazole when this drug was marketed. However, systemic therapy with albendazole or ivermectin is also effective.<sup>7</sup> Nonetheless hookworm folliculitis responds less to ivermectin than creeping dermatitis.<sup>8</sup> Mebendazole is registered for treatment of (intestinal) hookworm as well. Failure to respond to the initial treatment in our patient may be explained by the differences in rate of absorption and efficiency between mebendazole and albendazole in the treatment of (H)CLM.

In summary HCLM is easily recognised if it occurs in its typical clinical form of creeping dermatitis. Hookworm folliculitis, however, is a less common clinical presentation of the same parasitic infection. Persistent itching folliculitis in a patient who has recently returned from an area where hookworm infestation is endemic should raise the suspicion of atypical hookworm folliculitis. Histological confirmation is required to make a definite diagnosis of a hookworm folliculitis in the absence of the characteristic creeping eruption. Treatment should be started based on typical clinical findings. A single oral dose of ivermectin or a three-day course of albendazole suffices as treatment in most cases.<sup>9</sup>

**Figure 2.** Illustration of typical cutaneous larva migrans (with courtesy of the ITG, Belgium)

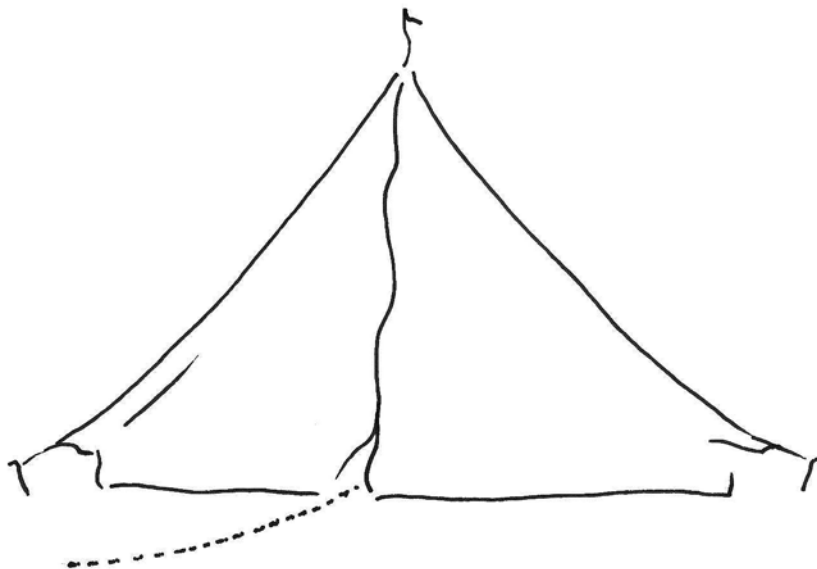


## ACKNOWLEDGEMENT

We thank Dr C.W. Ang for his contributions.

## REFERENCES

1. Caumes E, Danis M. From creeping eruption to hookworm-related cutaneous larva migrans. *Lancet Infect Dis* 2004;4(11):659-60.
2. Miller A, Walker J, Jaworski R, Launey W, Paver R. Hookworm folliculitis. *Arch Dermatol* 1991;127(4):547-9.
3. Caumes E, Ly F, Bricaire F. Cutaneous larva migrans with folliculitis: report of seven cases and review of the literature. *Br J Dermatol* 2002;146(2):314-6.
4. Freedberg I, Eisen AZ, Wolff K, Austen KF, Goldsmith LA, Katz SI (ed). *Fitzpatrick's Dermatology in General Medicine*. USA: McGraw-Hill; 1999.
5. Richey T, Gentry R, Fitzpatrick J, Morgan A. Persistent cutaneous larva migrans due to *Ancylostoma* species. *South Med J* 1996;89(6):609-11.
6. Opie K, Heenan P, Delaney T, Rohr J. Two cases of eosinophilic pustular folliculitis associated with parasitic infestations. *Australas J Dermatol* 2003;44(3):217-9.
7. Caumes E, Carriere J, Detry A, Gaxotte P, Danis M, Gentilini M. A randomized trial of ivermectin versus albendazole for the treatment of cutaneous larva migrans. *Am J Trop Med Hyg* 1993;49(5):641-4.
8. Caumes E. Treatment of cutaneous larva migrans. *Clin Infect Dis* 2000;4(30):811-14.
9. Albonico M, Smith PG, Hall A, Chwaya HM, Alawi KS, Savioli L. A randomized controlled trial comparing mebendazole and albendazole against *Ascaris*, *Trichuris* and hookworm infections. *Trans R Soc Trop Med Hyg* 1994;88(5):585-9.



Another itchy holiday