

# Embolisation of hydatid cysts in the pulmonary artery presenting with haemoptysis

O.K. Aribas<sup>1\*</sup>, F. Kanat<sup>2</sup>, E. Turk-Aribas<sup>3</sup>, I. Erayman<sup>4</sup>, T. Yuksek<sup>4</sup>

Departments of <sup>1</sup>Thoracic Surgery, <sup>2</sup>Chest Diseases, <sup>3</sup>Infectious Diseases and <sup>4</sup>Cardiovascular Surgery, Meram Medical School, Selcuk University, Cogus Cerrahisi Anabilim Dali, 42080 Meram-Konya, Turkey, <sup>\*</sup>corresponding author: tel.: +90 3322236844, fax.: +90 3322236643, e-mail: olgun@selcuk.edu.tr

## ABSTRACT

A 49-year-old female patient who had undergone surgery for hepatic echinococcosis five years previously was admitted with haemoptysis. MRI angiography showed total occlusion of the left inferior pulmonary artery. Echocardiography showed no pulmonary hypertension. The patient underwent pneumonectomy and cysts in the left pulmonary artery were observed. Pulmonary artery involvement should be considered in patients who have undergone hepatic cyst surgery if haemoptysis is the first presenting symptom, especially in endemic regions for hydatidosis.

## KEYWORDS

Hydatid disease, pneumonectomy, pulmonary arteries, pulmonary embolism

## INTRODUCTION

Hydatid disease, resulting from the larval stage of *Echinococcus granulosus* in the intermediate host, develops in the liver in 60% of cases and in the lungs in 25%. The heart is the most common site in the cardiovascular system (0.02 to 2%). Most common cardiac localisations are the left ventricle wall (60%), followed by the right ventricle (10%), pericardium (7%), atrium (6%) and interventricular septum (4%).<sup>1</sup> Pericardial complications have only been reported in 2.1% of pulmonary hydatid cysts.<sup>2</sup> Hydatid cysts may seldom develop within pulmonary arteries after ruptured cardiac or hepatic cysts. We report a patient with multiple hydatid cysts within the pulmonary arteries that necessitated left pneumonectomy. We believe that there are no previous reports of similar patients treated by lung resection in the literature.

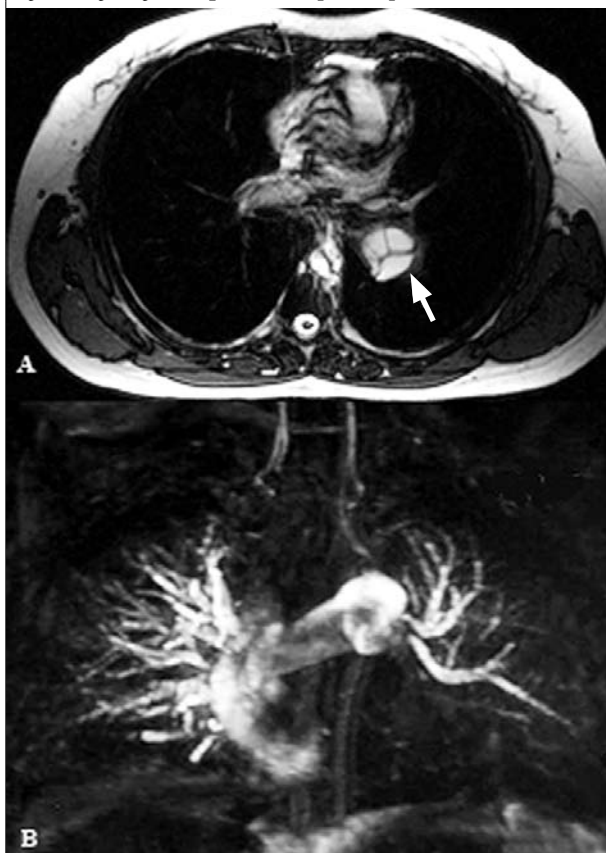## CASE REPORT

We present a 49-year-old female patient with haemoptysis. Her past history revealed surgery for a hepatic hydatid cyst five years previously, which was performed elsewhere. Physical examination was unremarkable except for rales on the left lung. Chest X-ray revealed left hilar enlargement, and a right paracardiac pulmonary nodule. Chest CT disclosed a cystic mass lesion lying within and obliterating the left main pulmonary artery, widespread tubular dilatation and peribronchial thickening in the left lower lobe bronchi and two small nodules in the right lower lobe. Chest MRI revealed septated cystic lesions in the left main pulmonary artery and MRI angiography showed an amputated left inferior pulmonary artery (*figure 1*). Ventilation-perfusion lung scan confirmed a perfusion defect in the left lower lobe. Echocardiography was normal. The patient underwent left pneumonectomy for irreversible pulmonary arterial wall and parenchymal destruction under total circulatory arrest. Numerous intact or ruptured hydatid cysts were observed on dissecting the pulmonary artery (*figure 2*). The intimal destruction was prominent in the dilated and thinned pulmonary artery wall. Albendazole treatment was given to the patient for the remaining small cysts on the right side. The patient was free of symptoms after eight months of follow-up.

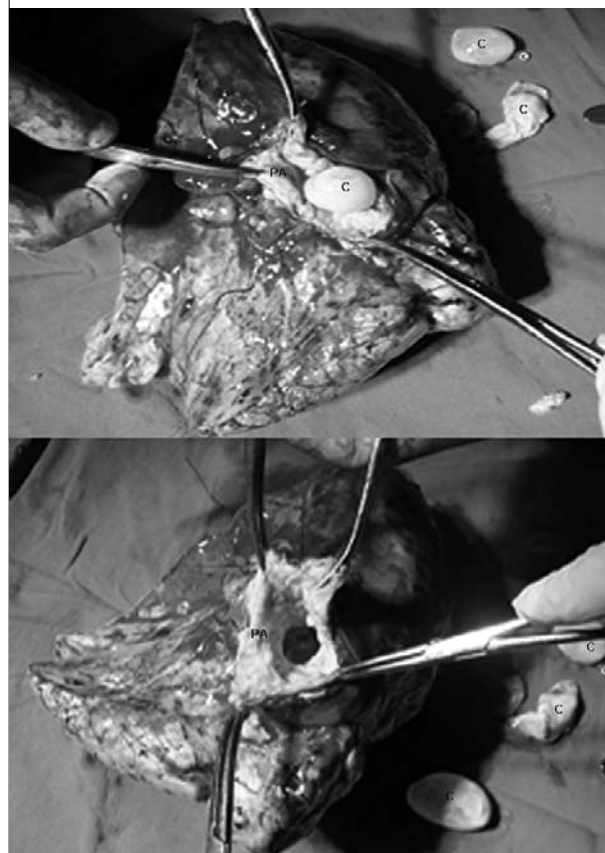
## DISCUSSION

The establishment of hydatid cysts within pulmonary arteries is usually the result of pulmonary embolisation, the source of which is either a cardiac or rarely a hepatic cyst. Cardiac cysts, especially those localised on the right side, are identified as a clinical entity because of the severe preoperative and intraoperative complications.<sup>3</sup> The rupture of right-sided cardiac cysts is responsible for the pulmonary artery localisation of hydatid cysts.<sup>4</sup> The majority of

**Figure 1:** A. Chest MRI scan showing septated cystic lesions (white arrow) in the left main pulmonary artery. B. MRI angiography showing total occlusion of the left inferior pulmonary artery.



**Figure 2:** Numerous intact or ruptured hydatid cysts (C) within the pulmonary artery (PA) after pulmonary artery dissection in resected specimen.



pulmonary hydatid cysts are secondary cysts that arise from pulmonary embolisation of ruptured hepatic cysts near the hepatic vein or the neighbouring inferior vena cava. In these cases, the rupture site is very small and even contrast cavography fails to visualise the site. If the rupture is extensive, the embolism may be massive and thus fatal. Such intraoperative rupture examples have been reported in the literature.<sup>5</sup> Wherever the primary focus, hydatid cyst embolism into the pulmonary artery is rarely encountered. In our patient, it is obvious that the primary origin is the liver. Hydatid embolism is clinically classified into three groups: 1) acute fatal cases, 2) subacute pulmonary hypertensive cases that result in death within a year after diagnosis, and 3) chronic pulmonary hypertensive cases.<sup>6</sup> Our case was totally different from those previously described in that no pulmonary hypertension was determined, although the left lower lobe parenchyma was affected and the main pulmonary artery showed fusiform dilatation due to intimal degeneration. The hydatid obstruction was entirely caused by the cysts or daughter vesicles without accompaniment of any clotting or local thrombosis.

Morbidity is due to cyst rupture with or without anaphylaxis, cyst infection, obstruction caused by progressive growth of the cyst and/or the dysfunction of involved organ. Sudden deaths have been reported among asymptomatic cases and even during hydatid surgery.<sup>5</sup> Such patients may be asymptomatic for a long time since the cyst grows slowly within pulmonary artery and thus pulmonary perfusion is maintained via the bronchial arteries. Both spiral CT and MRI angiography clearly disclose cystic occlusion of the pulmonary artery and its branches as happened in our case.<sup>4,7</sup> Surgical intervention is the primary treatment. Embolectomy and/or enucleation are often the preferred surgical options. Off-pump surgery is mandatory except for distal localisations in the pulmonary artery and its branches.<sup>17</sup> The degree of the degenerative changes in the arterial wall, proximal or distal localisations of the pulmonary artery occlusion and irreversible parenchymal changes are the factors influencing selection of the operative procedure. We were obliged to perform pneumonectomy in this patient since the hydatid emboli adherent to the artery had caused downward aneurysmatic dilatation beginning from the proximal part of left main pulmonary artery as

a result of intimal degeneration and leading to chronic pulmonary destruction. By-pass surgery was preferred to prevent hydatid dissemination to the contralateral lung. As the disease occurred after hepatic surgery, it is clear that during surgery to remove hepatic hydatid cysts located deep or within the neighbourhood of hepatic venous structures, the following measures should be taken to avoid a situation such as in our case: 1) inferior vena cava should be clamped; 2) no hepatic traction should be performed and when needed cavo-caval by-pass may be carried out; 3) interventional procedures (by gastroenterologists or radiologists) should be avoided, and 4) surgery should be performed in centres where extracorporeal surgery is possible.<sup>5</sup> Such patients should be treated with albendazole due to the disseminated hydatidosis.<sup>7</sup>

In conclusion, although it is rare, pulmonary artery involvement must be taken into consideration in patients who have undergone hepatic cyst surgery if haemoptysis is the first presenting symptom, especially in endemic regions for hydatidosis.

## REFERENCES

1. Ben-Ismaïl M, Fourati M, Bousnina A, Zouari F, Lacronique J. Hydatid cyst of the heart. Apropos of 9 cases. *Arch Mal Coeur Vaiss* 1977;70:119-27.
2. Aribas OK, Kanat F, Gormus N, Turk E. Pleural complications of hydatid disease. *J Thorac Cardiovasc Surg* 2002;123:492-7.
3. Gormus N, Yeniterzi M, Telli HH, Solak H. The clinical and surgical features of right-sided intracardiac masses due to echinococcosis. *Heart Vessels* 2004;19:121-4.
4. Odev K, Acikgozoglu S, Gormus N, Aribas OK, Kiresi DA, Solak H. Pulmonary embolism due to cardiac hydatid disease: imaging findings of unusual complication of hydatid cyst. *Eur Radiol* 2002;12:627-33.
5. Rothlin MA. Fatal intraoperative pulmonary embolism from a hepatic hydatid cyst. *Am J Gastroenterol* 1998;93:2606-7.
6. Kardaras F, Kardara D, Tselikos D, et al. Fifteen year surveillance of echinococcal heart disease from a referral hospital in Greece. *Eur Heart J* 1996;17:1265-70.
7. Yague D, Lozano MP, Lample C, Nunez ME, Sanchez F. Bilateral hydatid cyst of pulmonary arteries: MR and CT findings. *Eur Radiol* 1998;8:1170-2.