

A young man with nonhealing venous ulcers

M.G. Vloedveld¹, A.W. Venema², A.J. Smit^{1*}

Departments of ¹Internal Medicine and ²Dermatology, University Medical Centre Groningen, University of Groningen, Groningen, the Netherlands, *corresponding author: tel.: +31 (0)50-361 48 54, e-mail: a.j.smit@int.umcg.nl

ABSTRACT

A 35-year-old man presented with nonhealing ulcers at an atypical location on his left foot, caused by a combination of venous insufficiency (after deep venous thrombosis) and arterial insufficiency. The underlying cause was Buerger's disease.

CASE REPORT

A 35-year-old man was admitted to our hospital because of nonhealing ulcers of his left foot. His medical history revealed deep venous thrombosis of his left leg, 14 years ago, and recurrent thrombophlebitis of this leg. The foot ulcers, which were painful, had been present for about one year without a provoking event. Apart from oedema of this leg since the thrombosis, he had no other symptoms. He had been smoking since puberty. No relevant other signs were present on physical examination. Venous insufficiency was suspected and confirmed by venous duplex ultrasonography. However, despite compression therapy and conventional wound care, the ulcers did not heal.

On admission, two ulcers were seen on his left foot (*figure 1*), with discrete oedema of this foot. Distal pulsations were present, except for the left dorsalis pedis artery, and no other abnormalities were found. Laboratory examination (including glucose, ANA, ENA, tests for antiphospholipid antibodies and homocysteine) was normal. A biopsy of the distal part of the left foot did not show any specific abnormalities. Since venous ulcers are not usually very painful, and mostly located on the medial aspect of the ankle, additional arterial tests were performed. Ankle-brachial pressure index was normal on both sides (left: 1.26, right: 1.23). Toe-brachial pressure index was normal on the right side (0.9), but too low on the left side (0.52). Arteriography of the lower extremities showed segmental occlusions and many corkscrew collaterals, especially in the left leg (*figure 2*). A proximal source of emboli was excluded by echocardiography.

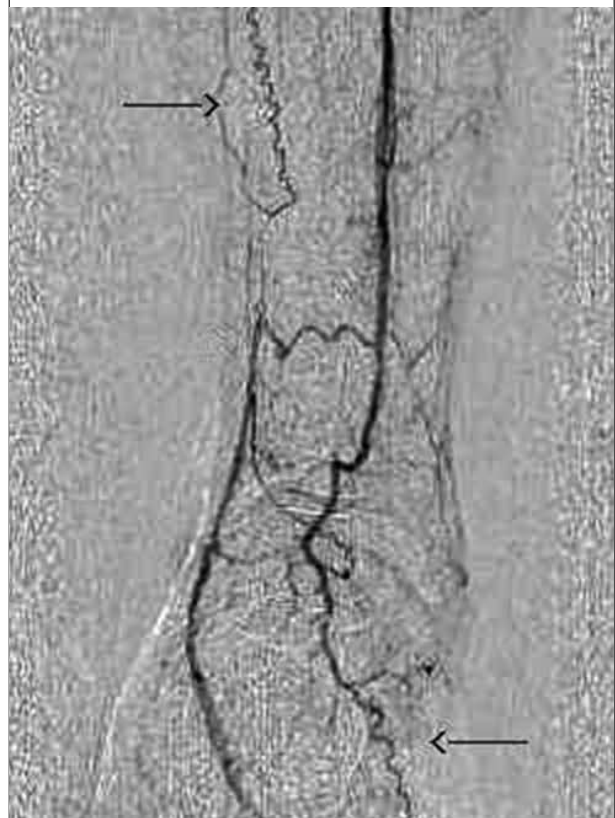
WHAT IS YOUR DIAGNOSIS?

See page 209 for the answer to this photo quiz.

Figure 1. Yellow discolouration on the left hand palm

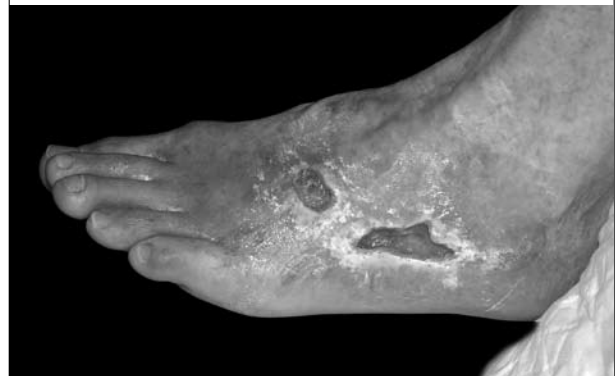

Figure 2. Angiography of the left leg, showing occlusion of the tibial posterior artery, with distal supply from the peroneal artery and some corkscrew collaterals (arrows)



ANSWER TO PHOTO QUIZ (ON PAGE 206)
A YOUNG MAN WITH NONHEALING VENOUS ULCERS

Findings were suggestive of Buerger's disease (thromboangiitis obliterans). This disease is characterised by the occurrence of segmental thrombotic occlusions of the small and medium-sized arteries in both upper and lower extremities and classically occurs in young male smokers. Not only arteries are affected, but many patients (approximately 40%) also suffer from or have a history of superficial thrombophlebitis. This thrombophlebitis can extend into the deep venous system, as is illustrated by the presented case.¹

Other diseases must be excluded, especially vasculitis and atherosclerosis. Noninvasive vascular testing may suggest arterial occlusive disease. However, since the disease is usually confined to the distal part of extremities, sometimes only toe pressures may be abnormal, as in the presented case. Arteriographic findings may be suggestive. Histopathological examination can provide definitive proof, but is often inconclusive, especially when lesions have been present for longer periods. Thus, the diagnosis is usually made using a combination of the clinical and arteriographic signs described above, in the absence of other possible causes.² Treatment consists of discontinuation of smoking and low-dose acetylsalicylic acid. In case of critical limb ischaemia intravenous iloprost (a prostaglandin analogue) may be used.³

In our patient, this regimen, in combination with compression therapy (avoiding too high compression pressures), resulted in healing of the ulcers.

DIAGNOSIS

Combination of venous and arterial insufficiency, probably both caused by Buerger's disease.

REFERENCES

1. Olin JW, Young JR, Graor RA, Ruschhaupt WF, Bartholomew JR. The changing clinical spectrum of thromboangiitis obliterans (Buerger's disease). *Circulation* 1990;82(5 Suppl):IV3-8.
2. Olin JW. Thromboangiitis obliterans (Buerger's disease). *N Engl J Med* 2000;343(12):864-9.
3. Fiessinger JN, Schafer M. Trial of iloprost versus aspirin treatment for critical limb ischaemia of thromboangiitis obliterans. The TAO Study. *Lancet* 1990;335(8689):555-7.