

Haemosuccus pancreaticus, a rare cause of upper gastrointestinal bleeding

N.B. Pronk*, W.P. Haanstra, F.G.H van der Kleij

Department of Internal Medicine, Scheper Hospital, Emmen, the Netherlands, *corresponding author, Medisch Spectrum Twente, PO Box 50000, 7500 KA Enschede, the Netherlands, tel.: +31 (0)53-487 20 00, fax: +31 (0)53-487 30 85, e-mail: pronkniels@hotmail.com

ABSTRACT

Upper gastrointestinal bleeding is most commonly caused by lesions in the oesophagus, stomach or duodenum. In a minority of cases the bleeding originates from the pancreatic duct, and is known as haemosuccus pancreaticus. In many cases it is associated with chronic pancreatitis. Diagnostic strategies and therapeutic options are discussed.

INTRODUCTION

Bleeding from the gastrointestinal tract is most commonly caused by lesions in the oesophagus, stomach or duodenum. Rarely, the focus of the bleeding originates from the pancreatic duct, 'haemosuccus pancreaticus'.¹ We describe a patient with recurrent bleeding in the gastrointestinal tract, which appeared to originate from the pancreatic duct.

CASE REPORT

A 40-year-old male was admitted to our hospital after recurrent episodes of melaena over the past 14 days. Four days before coming to the hospital he had vomited blood, which had been followed by melaena the day prior to admission. He was not suffering from nausea or heartburn, but had recurrent complaints of upper abdominal pain radiating to the back. His medical history revealed chronic pancreatitis for three years before admission. The pancreatitis was most probably caused by ongoing alcohol abuse. He had also gone through a period of aggressive, psychiatric

behaviour. During the last two years he was frequently seen with anaemia after haematemesis or episodes with melaena. No diagnosis was made by repeated gastro-duodenoscopy. During one of these bleeding episodes a radioactive labelled erythrocyte nuclear scan suggested a bleeding near the jejunum.

On physical examination his blood pressure was 100/60 mmHg, pulse rate regular at 110 beats/min and central temperature of 38.2°C. His appearance was pale and malnourished. Rectal examination showed a combination of dark red blood and melaena. Laboratory results revealed a haemoglobin of 3.2 mmol/l (normal values: 8.5-11.0), a serum urea nitrogen of 5.9 mmol/l (2.5-6.4) and creatinine of 79 µmol/l (50-100). Liver function tests, serum amylase, glucose and prothrombin time were in the normal range. The patient underwent a gastro-duodenoscopy introducing the scope beyond the duodenum into the proximal jejunum. No sign of a bleeding was seen, the duodenal ampulla was normal and did not show blood. We decided to perform a computed tomogram (CT) angiography of the upper abdomen as this was a quick and less invasive procedure in contrast to angiography according to the Seldinger technique. Spontaneous filling of the pancreatic duct was seen after intravenous contrast had been administered (*figure 1*). It was concluded that a selective angiography of the splenic artery should be made to confirm the presence of a fistula to the pancreatic duct. In that case an attempt could be made to coil the aneurysm. However, active bleeding stopped making the chance of finding a fistula small. Until present, almost a year since admission, the bleeding has not reoccurred.

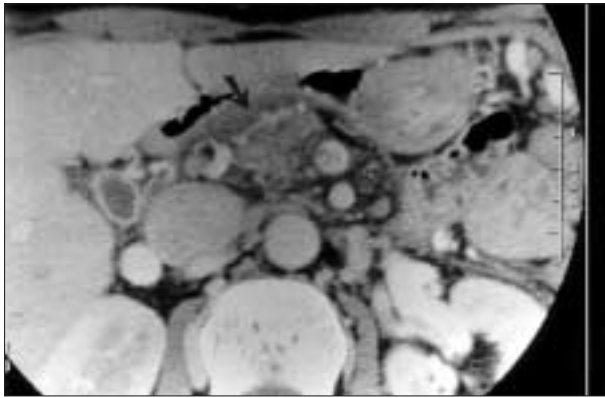


Figure 1
CT angiography; after administration of IV contrast, the pancreatic duct becomes visible (arrow)
The pancreatic head is slightly swollen and the pancreatic duct appears irregular and widened.

DISCUSSION

Haemosuccus pancreaticus, also termed Wirsungorrhaghia or pseudohaemobilia, is a rare cause of upper gastrointestinal (UGI) bleeding. It was first described by Lower and Farell in 1931 and named by Sandblom in 1970.¹ It is estimated that one in every 1500 UGI bleeds are caused by haemosuccus pancreaticus.² In most cases a history of chronic pancreatitis is present. The pancreatic inflammation is thought to lead to erosion of peripancreatic blood vessels forming an aneurysm or spurious aneurysm; secondary fistula formation from the aneurysm to the pancreatic duct causes bleeding. A second cause of bleeding is the direct erosion of a pancreatic pseudocyst into a peripancreatic artery or vein.³ It has been reported that chronic pancreatitis causes an aneurysm in adjacent arteries in 10% of cases.⁴ Rarely, an arteriosclerotic aneurysm or traumatic aneurysm, in most cases of the splenic artery, will rupture into a normal pancreatic duct.² Haemosuccus pancreaticus is often difficult to diagnose, partly because of its rarity and anatomical localisation. Also, the bleeding is often intermittent with sometimes long intervals in between.

Endoscopy is essential to rule out other causes of UGI bleeding. In rare cases, active bleeding is seen coming from the duodenal ampulla.⁵ In some cases endoscopic retrograde pancreatography shows clots in a dilated pancreatic duct.⁶ On precontrast CT, the characteristic finding of clotted blood in the pancreatic duct, known as the sentinel clot, is seldom seen.⁷ Early angiography or a CT angiography is recommended in cases where endoscopy

is not diagnostic, identifying the presence of an aneurysm or pseudoaneurysm and sometimes showing the fistula between the pancreatic duct and an artery. In contrast sometimes only filling of the pancreatic duct is present as in our case.⁷ Because the bleeding is often intermittent, active bleeding as we saw is rare. Ultrasound of the abdomen can also contribute showing signs of chronic pancreatitis or giving an indication of the size of an existing aneurysm.⁷ Treatment of haemosuccus pancreaticus in a patient with a history of chronic pancreatitis has been surgical in most reports.^{1,5} In most cases proximal arterial ligation, distal pancreatectomy and splenectomy is performed in one surgical setting. When haemorrhage is associated with a pancreatic pseudocyst, pancreatic resection is appropriate. Duodenopancreatectomy is indicated for lesions in the head of the pancreas, and subtotal pancreatic resection for those in the body or tail.² Angiographic intervention of a haemorrhage from a true aneurysm or pseudoaneurysm in haemosuccus pancreaticus, either to stabilise the patient in order to perform elective surgery or as a definitive treatment, is possible. This could particularly be an option in elderly or high-risk patients. In more recent reports experience with this method of treatment has been reported.^{5,8,9} Embolisation of the splenic artery can be complicated by (partial) splenic infarction or abscess formation. Therefore, assessment of the collateral flow should be made prior to the embolisation,⁹ although abundant collateral circulation does not always prevent this complication.¹⁰ A third therapeutic option that has been reported in the treatment of a splenic artery aneurysm is implantation of stent grafts, reducing the risk of splenic infarction or abscess formation.^{11,12} This procedure can be difficult because of a sharp angle of the origin in the celiac axis, a small diameter and tortuosity of the splenic artery, thus making it difficult to introduce currently available stent grafts.¹¹

In conclusion, upper gastrointestinal bleeding in a patient with a history of chronic pancreatitis could be caused by haemosuccus pancreaticus. If gastroduodenoscopy shows no focus for active bleeding, angiographic investigations should be undertaken to search for peripancreatic artery aneurysms. Diagnosis is difficult because of intermittent nature of the bleeding with sometimes long intervals in between. Therapeutic options consist of surgery, embolisation or stenting. A therapeutic strategy should be discussed and also depends on the treating doctor's experience, and the age and the condition of the patient. In case of recurrent bleeding in our patient, we would initially try to embolise an existing aneurysm because of the experience of the radiologist in our centre.

REFERENCES

1. Sandblom P. Gastrointestinal hemorrhage through the pancreatic duct. *Ann Surg* 1970;171:61-6.
2. Suter M, Doenz F, Chapuis G, Gillet M, Sandblom P. Haemorrhage into the pancreatic duct (Hemosuccus Pancreaticus): recognition and management. *Eur J Surg* 1995;161:887-92.
3. Camishon RC, Pello MJ, Spence RK, et al. Hemoductal pancreatitis. *Surgery* 1992;111:86-9.
4. White AF, Baum S, Buranasiri S. Aneurysms secondary to pancreatitis. *Am J Roentgenol* 1976;127:393-6.
5. Sakorafas GH, Sarr MG, Farley DR, Que FG, Andrews JC, Farnell MB. Hemosuccus pancreaticus complicating chronic pancreatitis: an obscure cause of upper gastrointestinal bleeding. *Langenbecks Arch Surg* 2000;385(2):124-8.
6. Akpınar H, Dicle O, Ellidockuz E, et al. Hemosuccus pancreaticus treated by transvascular selective arterial embolization. *Endoscopy* 1999;31:213-4.
7. Koizumi J, Inoue S, Yonekawa H, Kunieda T. Hemosuccus pancreaticus: diagnosis with CT and MRI and treatment with transcatheter embolization. *Abdom Imaging* 2002;27:77-81.
8. Stosslein F, Zimmermann L, Bulang T. Embolization treatment of bleeding complications in pancreatitis. *J Hepatobiliary Pancreat Surg* 1998;5(3):344-7.
9. Salam Ta, Lumsden AB, Martin LG, Smith III RB. Nonoperative management of visceral aneurysms and pseudoaneurysms. *Am J Surg* 1992;164:215-9.
10. Baker KS, Tisando J, Cho SR, Beachley MC. Splanchnic artery aneurysms and pseudoaneurysms: transcatheter embolization. *Radiology* 1987;163:135-9.
11. Yoon H-K, Lindh M, Uher P, Lindblad B, Ivancev K. Stent-graft repair of a splenic artery aneurysm. *Cardiovasc intervent radiol* 2001;24(3):200-3.
12. Benz CA, Jakob P, Jakobs R, Riemann JF. Hemosuccus pancreaticus - a rare case of gastrointestinal bleeding: diagnosis and interventional radiological therapy. *Endoscopy* 2000;32:428-31.

