

Is that massive effusion in the right pleural cavity?

Z-G. Zhou *, J. Yang, F. Huang

Department of Thoracic Surgery, The Third Hospital of Hebei Medical University, Shijiazhuang, China.

*Corresponding author: 1205888646@qq.com

Figure 1. X-ray revealing massive pleural effusion in the right chest

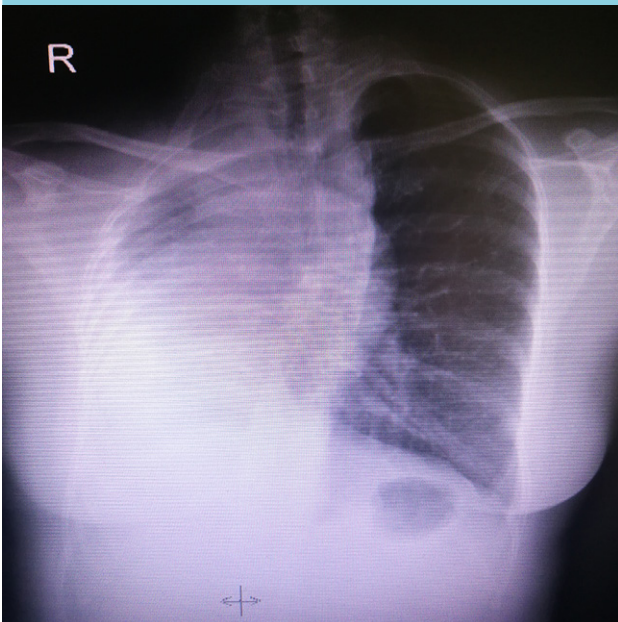
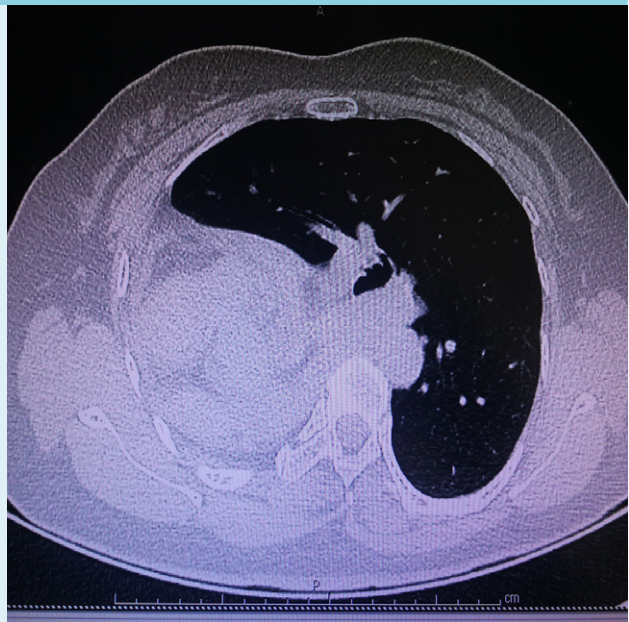

Figure 2. CT scan revealing pulmonary agenesis



CT = computed tomography

CASE REPORT

A 44-year-old woman presented to the thoracic surgery department with a one-day history of chest distress and pain in the right side of her chest. The results of the physical examination were notable for rib crowding on the right, a mild scoliosis with convexity of spinal curvature towards the left, heart sounds best heard on the right side of the chest, and low breathing sounds on the right. There was a massive hydrothorax as seen by chest X-ray (figure 1). A computed tomography (CT) scan of the thorax was made (figure 2).

WHAT IS YOUR DIAGNOSIS?

See page 378 for the answer to this photo quiz.