

# Periorbital oedema and muscle weakness

M.A. Lebbink, W.M. van der Deure\*

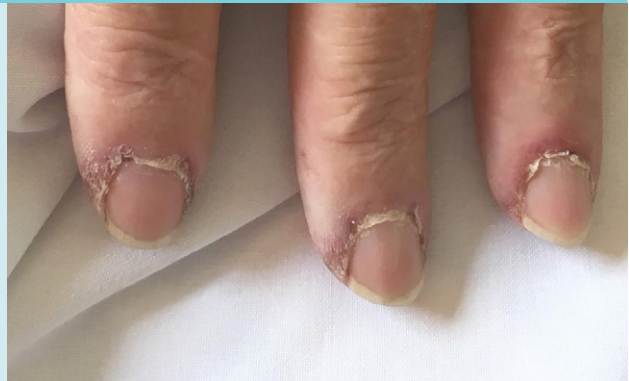
Department of Internal Medicine, Groene Hart Hospital, Gouda, the Netherlands'.

\*Corresponding author: wendy.van.der.deure@ghz.nl

Figure 1. Periorbital erythema with oedema

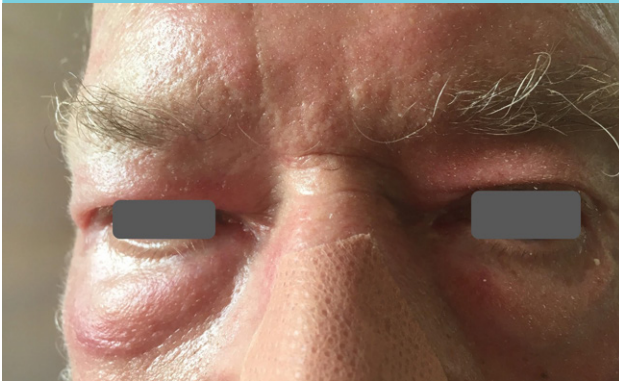

Figure 2. Cuticles



## CASE REPORT

A 75-year-old man presented with a four-day history of periorbital erythema with oedema (figure 1) and ragged cuticles with periungual erythema (figure 2). Additionally, he developed progressive symmetric muscle weakness in the upper limbs and head-neck area, including difficulty swallowing. He had no fever. Laboratory testing revealed an elevated C-reactive protein of 39 mg/ml (normal value

< 10 mg/ml), an elevated creatinine kinase of 3978 IU/l (normal value < 171 IU/l), and a lactate dehydrogenase of 511 IU/l (normal value < 248 IU/l).

## WHAT IS YOUR DIAGNOSIS?

See page 300 for the answer to this photo quiz.