

Cryptosporidiosis leading to an unsuspected diagnosis of AIDS

M.W.C.J. Schoofs^{1,4*}, E. Maartense¹, F. Eulderink², R.W. Vreede³

Departments of ¹Internal Medicine, ²Pathology and ³Microbiology, Reinier de Graaf Gasthuis, Delft, the Netherlands, ⁴Department of Epidemiology and Biostatistics, Erasmus Medical Centre, PO Box 1738, 3000 DR Rotterdam, the Netherlands, tel.: +32 (0)10-408 74 83, fax: +31 (0)10-408 93 82, e-mail: m.schoofs@erasmusmc.nl, * corresponding author

ABSTRACT

We describe a 68-year-old woman with an episode of diarrhoea, malaise and weight loss, caused by infection with *Cryptosporidium*. The diagnosis was hampered because this patient had a low risk of HIV infection, a two-year history of Crohn's disease, and a simultaneous candidal infection. An infection with *Cryptosporidium* was demonstrated with electron microscopic examination, and subsequent tests revealed positive HIV serology. AIDS was probably contracted through her husband.

INTRODUCTION

The differential diagnosis of diarrhoea is very extensive. In patients with Crohn's disease a new episode of gastrointestinal symptoms can usually be ascribed to an exacerbation. When the symptoms do not respond to adequate therapy, further investigations must be performed. We report here on a patient with previously diagnosed Crohn's disease who developed therapy-resistant diarrhoea.

CASE REPORT

A 68-year-old woman presented with a three-month history of nausea, abdominal cramps, diarrhoea without blood or mucus, malaise and a weight loss of 14 kg. Three years earlier, in 1998, Crohn's disease had been diagnosed after an episode of fever, diarrhoea and weight loss. Biopsies then showed a granulomatous colitis. Since treatment, she had been without symptoms.

At first, the new episode of gastrointestinal symptoms was attributed to an exacerbation of Crohn's disease. She was treated with mesalazine and budesonide, but the symptoms persisted. A colonoscopy showed no signs of active Crohn's disease. A gastro-duodenoscopy revealed a *Candida* oesophagitis, confirmed by histological examination and colon biopsies showed chronic active inflammation with para-aminosalicylic acid (PAS) positive particles in the crypts that were regarded as yeast forms of *Candida*. Because of further weight loss and therapy-resistant gastrointestinal symptoms, she was admitted to our hospital. She weighed 48 kg, whereas her height was 1.60 meter. Her blood pressure was 90/60 mmHg and pulse rate 80 beats/min. The abdomen was slightly distended with lively peristaltic movements. Her mouth showed *Candida* stomatitis. Physical examination showed no other abnormalities. Routine examination of repeated stool specimens showed no pathogenic bacterial or parasitic organisms. Laboratory examination showed an erythrocyte sedimentation rate of 7 mm/hour, haemoglobin 7.3 mmol/l and a leucocyte count of $3.8 \times 10^9/l$. Serum potassium (2.4 mmol/l) and albumin (20 g/l) were decreased, as were serum urea nitrogen (1.2 mmol/l) and creatinine (47 μ mol/l). Liver tests were unremarkable. X-rays of the small bowel and abdominal ultrasounds revealed no abnormalities. Gastroscopy was repeated and jejunum biopsies demonstrated PAS-positive micro-organisms on the epithelial surface of villi and crypts. These were more suggestive of *Cryptosporidia* than of yeasts, which were initially considered on account of the observed *Candida* oesophagitis. Retrospectively, the micro-organisms in the colon were similar. Subsequent electron microscopy of the biopsies confirmed the infection with *Cryptosporidium* (figure 1). At the same time, using specific staining techniques,

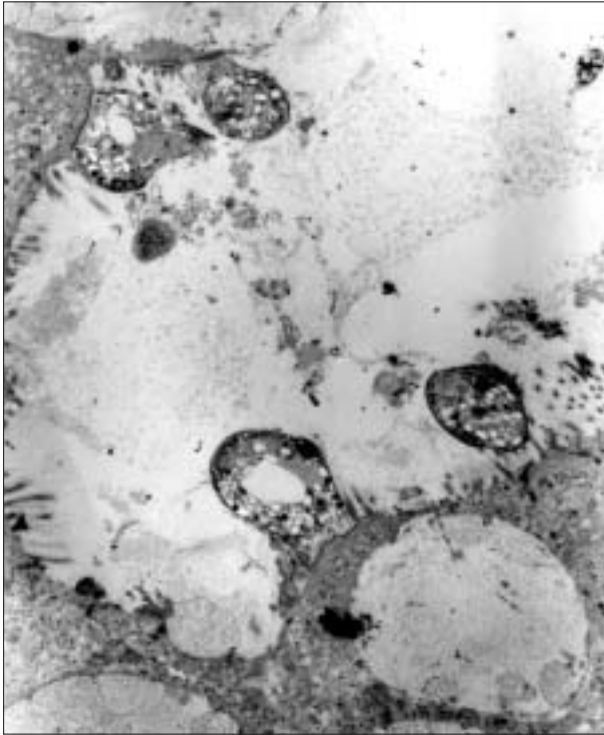


Figure 1
Electron microscopic photograph of intestinal crypt. Below and left, parts of epithelial cells with brush border; in the lumen, four schizonts of Cryptosporidium. Magnification 3000x

cryptosporidial oocysts were found in the stools. Because of the presence of opportunistic infections, a diagnosis of AIDS was considered, although this patient had a very low *a priori* risk of HIV infection. She had had no sexual relationships since her husband had died 14 years previously. She had neither a history of blood transfusions nor of intravenous drug use. However, anti-HIV antibodies were demonstrated and HIV-1 infection was confirmed by Western blot. Her husband had received several transfusions during brain tumour surgery in the period 1980 to 1985, when HIV screening on donor blood was not routinely performed in the Netherlands. It is possible that her husband was infected by a transfusion and transmitted the virus to our patient more than 14 years ago. The number of CD4+ T lymphocytes was very low: 0.01×10^6 /ml (normal $0.5-1.7 \times 10^6$ /ml). The viral load was 1.75×10^5 eq/ml. A highly active antiretroviral treatment regimen (HAART) was prescribed, which consisted of the combination zidovudine, lamivudine and indinavir. This was combined with cotrimoxazole as prophylaxis for *Pneumocystis carinii*. Symptomatic therapy with loperamide and metoclopramide helped to control the diarrhoea and after six weeks the patient was discharged. As an outpatient further improvement was observed and

finally her weight increased by 20 kg. As early as six weeks after starting HAART, HIV-RNA was below the detection limit (<500 eq/ml in that period). Fifteen months later the HAART regimen was successfully changed to the combination of zidovudine, lamivudine and abacavir. The number of CD4+ T lymphocytes had risen to 0.08×10^6 /ml.

DISCUSSION

This elderly patient was shown to have cryptosporidiosis, surprisingly as an opportunistic infection secondary to AIDS. The patient probably contracted the HIV infection through the sexual route from her late husband, who had received blood transfusions between 1980 and 1985. Two years before AIDS was detected the patient had granulomatous colitis, suggestive of Crohn's disease. Cytomegalovirus, histoplasma and atypical mycobacterial infections can mimic Crohn's disease in patients with AIDS.¹⁻⁴ Yoshida *et al.* suggest that a Crohn's-like disease secondary to an occult underlying infection can occur.⁵ Hing *et al.* reported on six HIV-positive patients with colitis, which was neither typical for ulcerative colitis nor for Crohn's disease but appeared to be a new entity.⁶ So, on one hand it is possible that this patient never had Crohn's disease, but had HIV-related colitis two years before. On the other hand, it is also possible that she did have Crohn's disease at the time of the first colonoscopy in 1998. *De novo* inflammatory bowel diseases after HIV infection have been reported,⁷⁻⁹ usually diagnosed when patients had near-normal CD4 counts.^{7,8,10,11} Our patient had no major opportunistic infections in 1998 and therefore she probably had a (near) normal CD4 count at that time. Many patients have been described in which inflammatory bowel disease went into remission when significant CD4 depression occurred.^{8,12,13} Because our patient responded well to therapy specific for Crohn's disease and because granulomas, but no *Cryptosporidia*, were found at the review of the colon biopsies of 1998, the diagnosis Crohn's disease was probably correct.

Cryptosporidium is a small parasite, easily overlooked in bowel biopsies. Because this patient was at low risk for AIDS and had a *Candida* oesophagitis, the particles in the crypts of the jejunum could easily have been misdiagnosed as the yeast form of *Candida*. However, electron microscopic examination clearly proved the micro-organisms to be *Cryptosporidia*, and this finally led to the diagnosis of AIDS.

ACKNOWLEDGEMENT

We gratefully acknowledge the critical comment on the manuscript by E.P.M. van Elzaker, MD, clinical microbiologist.

REFERENCES

1. Wajzman R, Cappell MS, Biempica L, Cho KC. Terminal ileitis associated with cytomegalovirus and the acquired immune deficiency syndrome. *Am J Gastroenterol* 1989;84:790-3.
2. Caroline DF, Hilpert PL, Russin VL. CMV colitis mimicking Crohn's disease in a patient with acquired immune deficiency syndrome (AIDS). *Can Assoc Radiol J* 1987;38:227-8.
3. Morrison YY, Rathbun RC, Huycke MM. Disseminated histoplasmosis mimicking Crohn's disease in a patient with the acquired immunodeficiency syndrome. *Am J Gastroenterol* 1994;89:1255-7.
4. Schneebaum CW, Novick DM, Chabon AB, Strutynsky N, Yancovitz SR, Freund S. Terminal ileitis associated with *Mycobacterium avium-intracellulare* infection in a homosexual man with acquired immune deficiency syndrome. *Gastroenterology* 1987;92:1127-32.
5. Yoshida EM, Owen DA. De Novo Crohn's disease in AIDS: Crohn's disease or Crohn's 'syndrome'? *J Clin Gastroenterol* 1998;26:93.
6. Hing MC, Goldschmidt C, Mathijs JM, Cunningham AL, Cooper DA. Chronic colitis associated with human immunodeficiency virus infection. *Med J Aust* 1992;156:683-7.
7. Bernstein BB, Gelb A, Tabanda-Lichauco R. Crohn's ileitis in a patient with longstanding HIV infection. *Am J Gastroenterol* 1994;89:937-9.
8. Yoshida EM, Chan NH, Herrick RA, et al. Human immunodeficiency virus infection, the acquired immunodeficiency syndrome, and inflammatory bowel disease. *J Clin Gastroenterol* 1996;23:24-8.
9. Lautenbach E, Lichtenstein GR. Human immunodeficiency virus infection and Crohn's disease: the role of the CD4 cell in inflammatory bowel disease. *J Clin Gastroenterol* 1997;25:456-9.
10. Franke M, Kruis W, Heitz W. First manifestation of ulcerative colitis in a patient with HIV infection. *Gastroenterology* 1990;98:544-5.
11. Bernstein CN, Snape WJ Jr. Active idiopathic ulcerative colitis in a patient with ongoing HIV-related immunodepression. *Am J Gastroenterol* 1991;86:907-9.
12. Dhar JM, Pidgeon ND, Burton AL. AIDS in a patient with Crohn's disease. *BMJ (Clin Res Ed)* 1984;288:1802-3.
13. James SP. Remission of Crohn's disease after human immunodeficiency virus infection. *Gastroenterology* 1988;95:1667-9.

Advertentie Thyrax