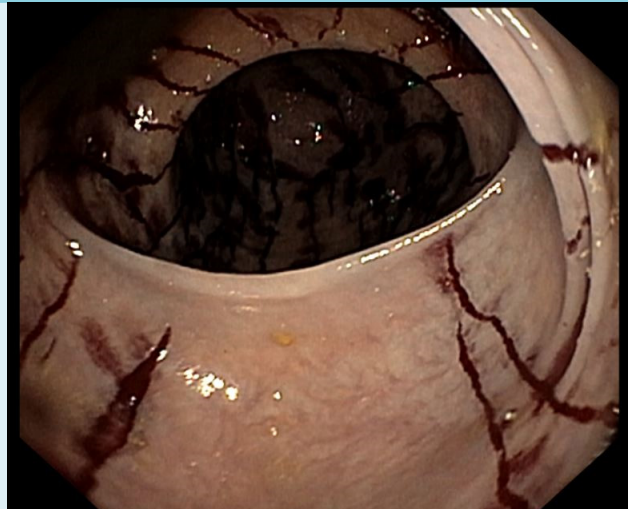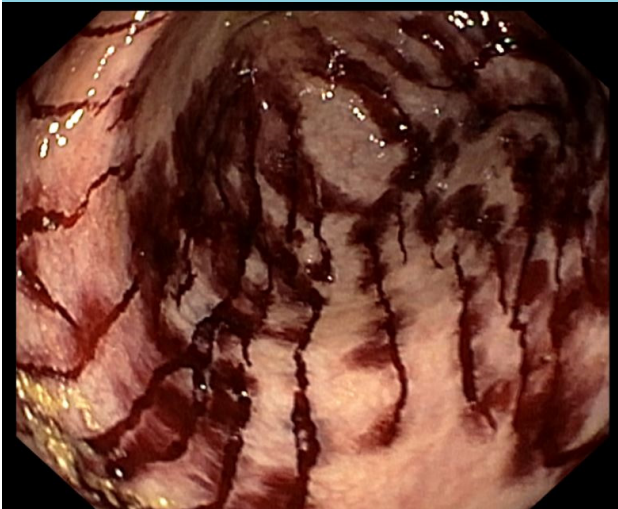


# The other cat scratch disease

Y.F.C. Kortmann\*, H.J.M. de Jonge

Department of Gastroenterology and Hepatology, Jeroen Bosch Ziekenhuis, 's Hertogenbosch, the Netherlands. \*Corresponding author email [y.kortmann@jbz.nl](mailto:y.kortmann@jbz.nl)

Figures 1 and 2. Endoscopic view in caecum



## CASE REPORT

We performed a colonoscopy on an 83-year-old female patient presenting with chronic diarrhoea. In the caecum, we observed many superficial tears and spontaneous mild bleeding.

## WHAT IS YOUR DIAGNOSIS?

See page 123 for the answer to this photo quiz.