

# Acenocoumarol as a risk factor for calciphylaxis: a feature clinicians should be aware of

E.F.E. Wenstedt<sup>1\*</sup>, C.J. Huysentruyt<sup>2</sup>, C.J.A.M. Konings<sup>1</sup>

<sup>1</sup>Department of Internal Medicine, Catharina Hospital Eindhoven, Eindhoven, the Netherlands,

<sup>2</sup>Department of Pathology, Catharina Hospital Eindhoven, Eindhoven, the Netherlands,

\*corresponding author: e-mail: elianewenstedt@live.nl

## ABSTRACT

In contrast with uraemic calciphylaxis in end-stage renal disease, causes of and risk factors for non-uraemic calciphylaxis are relatively unknown to clinicians and have yet to become fully established. This report describes a case of non-uraemic calciphylaxis, in which the use of acenocoumarol might have been a risk factor. It is important to raise awareness about this association among clinicians, as vitamin K antagonists have to be stopped for an optimal treatment of this severe condition.

## KEYWORDS

Calciphylaxis, acenocoumarol, warfarin, calcaemic uraemic arteriopathy, vitamin K antagonist, non-uraemic

## INTRODUCTION

Calciphylaxis is a rare disease that consists of calcifications in the blood vessels, which lead to secondary ischaemia and painful necrotic lesions of the skin. It is known to be associated with dialysis treated end-stage renal disease in combination with secondary hyperparathyroidism. This is called uraemic calciphylaxis, or a more recent term: calcaemic uraemic arteriopathy. If calciphylaxis occurs in earlier stages of renal disease or in patients with a normal kidney function, the term non-uraemic calciphylaxis is used. It is crucial that calciphylaxis and its risk factors are recognised, since both uraemic and non-uraemic forms have a severe prognosis with a one-year mortality of 45-80%.<sup>1</sup> In contrast with uraemic calciphylaxis, causes of and risk factors for non-uraemic calciphylaxis are relatively unknown to clinicians and have yet to become fully established. A relatively new insight is that vitamin K antagonists may play a role. This report describes a patient

### What was known on this topic?

Calciphylaxis is associated with end-stage renal disease. However, it also occurs in patients with normal renal function, known as non-uraemic calciphylaxis. The different causes of and risk factors for this disease have yet to become fully established.

### What does this add?

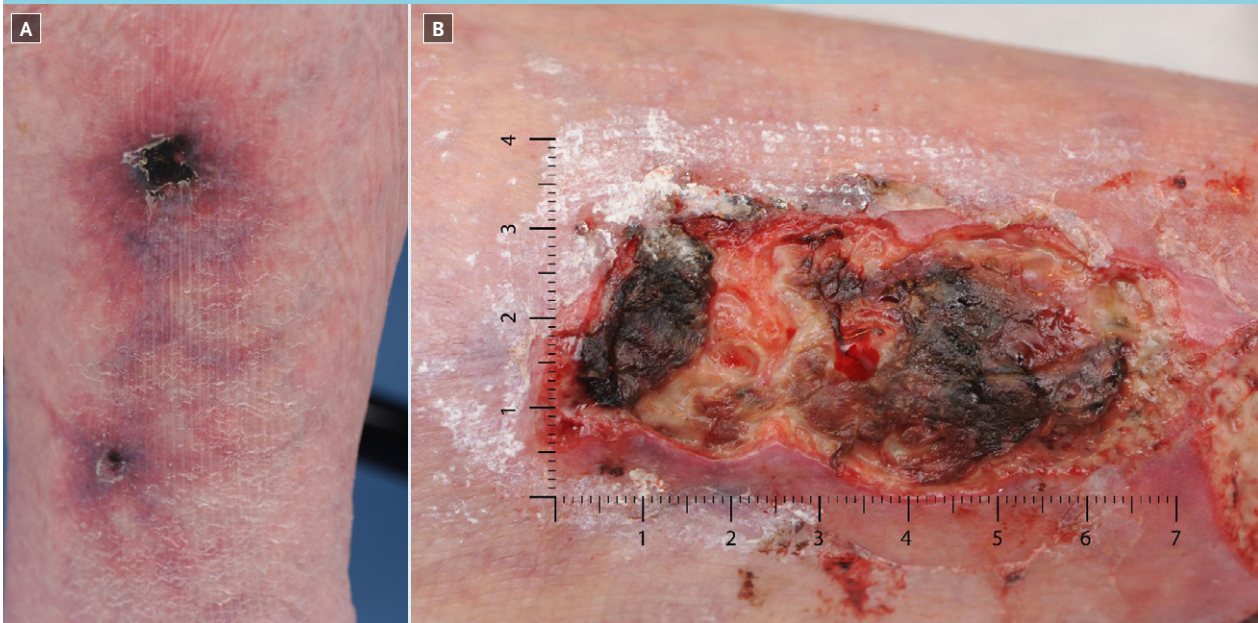This case report raises the awareness that vitamin K antagonists interfere with calcium metabolism and may play a role in calciphylaxis. Therefore, vitamin K antagonists should be stopped in order to optimise treatment.

with non-uraemic calciphylaxis in which this might have been the case.

## CASE REPORT

A 82-year-old female presented with a painful lower right extremity after a fall five weeks before. There were two necrotic lesions on her right leg, surrounded by livedoid reticularis (*figure 1a*). The medical history of this patient included obesity, diabetes mellitus, hypertension, mechanic heart valve implantation, chronic obstructive pulmonary disease, and chronic kidney disease (modification of diet in renal disease (MDRD) of around 30 ml/min). The patient had been using acenocoumarol for 5 years, and additional medication included metoprolol, simvastatin, furosemide, formoterol/ beclomethasone, tiotropium, and oxazepam. Anti-phospholipid syndrome, vasculitis, systemic lupus erythematosus, and cryoglobulinaemia were excluded. Calcium and phosphate levels were normal, and parathyroid hormone was slightly elevated. An ankle-brachial index test showed no

**Figure 1.** A. Two necrotic lesions surrounded by livedoid reticularis on the lower right leg. B. Large ulcerated lesion on the right lower leg a few weeks after initial presentation

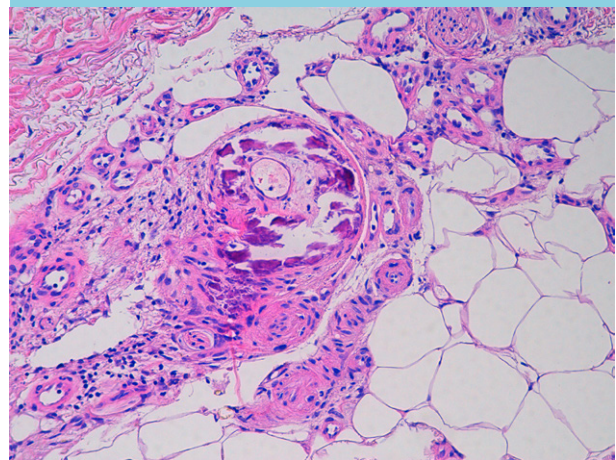


abnormalities, and a biopsy was taken. Differential diagnoses included polyarteritis nodosa, cholesterol embolisation, and calciphylaxis. Topical corticosteroid therapy and pain management were pragmatically started. Unfortunately, the biopsy was inconclusive. Meanwhile, the symptoms worsened, but the patient did not agree to a new biopsy. Oral prednisone was started, with vasculitis/polyarteritis nodosa as the main working diagnosis. A wound culture did not reveal any non-physiological flora. The symptoms continued to worsen (*figure 1b*) and a few months later the patient agreed to a new biopsy. This time the biopsy demonstrated a clear image of calciphylaxis (*figure 2*). Further laboratory evaluation showed a normal serum calcium of 2.32 mmol/l (2.10-2.55 mmol/l), a normal phosphate level of 1.04 mmol/l (0.80-1.50), a mildly increased parathyroid hormone of 10.0 pmol/l (1.6-6.9 pmol/l), and decreased vitamin D (25-OH) of 17 nmol/l (> 50 nmol/l). Creatinine level was 119  $\mu$ mol/l and the MDRD was 38 ml/min. Subsequently, supplementation of vitamin D was started, and the hyperparathyroidism was corrected by prescribing cinacalcet (mimpara). Simultaneously, acenocoumarol was replaced by a low-molecular-weight heparin (LMWH). Unfortunately, two weeks later our patient died, with cardiac failure being the most presumable cause in a multifactorial situation. No autopsy was allowed.

## DISCUSSION

A systematic review assessing the different causes of non-uraemic calciphylaxis, indicated primary hyperpara-

**Figure 2.** The skin biopsy revealed the characteristic calcifications of several small- to medium-sized arteries and arterioles. In addition to mural calcification, this particular vessel also showed intimal proliferation



thyroidism as the most common cause (28%).<sup>2</sup> However, serum parathyroid hormone in our case was only mildly elevated compared with the levels in the included cases.<sup>2</sup> Therefore, we examined whether other relevant factors might have played a role. The suggested risk factors for non-uraemic calciphylaxis are numerous, including white race, female sex, obesity, diabetes mellitus, use of a vitamin K antagonist, liver disease, malignancy, systemic corticosteroid use, and protein C and S deficiency.<sup>2,3</sup> The first five risk factors were present in our case. Of these, we found the use of a vitamin K antagonist of

particular interest, as it is the only one of the mentioned risk factors that can immediately be adjusted. Several case reports state that the use of a vitamin K antagonist was the main cause of calciphylaxis in their patient.<sup>4,6</sup> Of note, larger studies are not that unambiguous. A retrospective analysis concluded that vitamin K antagonist use was not statistically associated with calciphylaxis.<sup>7</sup> However, this analysis only made a comparison between *uraemic* calciphylaxis patients and a dialysis control group without calciphylaxis. While vitamin K antagonist use was present in 60% of the *non-uraemic* patients, this group was not compared with a control group.<sup>7</sup> In the earlier mentioned systematic review about non-uraemic calciphylaxis, vitamin K antagonist use was present in 25% of the cases.<sup>2</sup> Unfortunately, existing literature either consists of retrospective studies or analyses of case reports. Therefore, selection bias and confounding by indication cannot be ruled out, and a definite conclusion cannot be drawn. Although epidemiological studies have thus not yet elucidated the role of vitamin K antagonists in calciphylaxis, this association is increasingly receiving attention in pathophysiological studies.

### Pathophysiology

In contrast to atherosclerotic disease, in which the intima is the site of calcification, calciphylaxis involves calcification of the tunica media. The intima is not left untouched, as a process of fibrosis takes place there. Progressive calcification and endothelial dysfunction lead to thrombotic occlusion and ischaemia, which causes tissue necrosis of the skin. The process of calcification starts with the transformation of vascular smooth muscle cells (VSMCs) into osteoblast-like phenotypes. VSMCs normally produce matrix gla protein (MGP), a protein that binds calcium phosphate and thus has a strong inhibitory effect on tissue calcification. Vitamin K antagonists are thought to reduce functional MGP, as they interfere in the vitamin K carboxylation by which MGP is normally activated.<sup>8</sup> Vitamin K consists of vitamin K<sub>1</sub> and K<sub>2</sub>, and vitamin K antagonists are not selective for either one of these. Vitamin K<sub>2</sub> is involved in the inhibition of calcium deposition in blood vessels, while vitamin K<sub>1</sub> leads to the contemplated anti-thrombotic effect. Currently, there are different ongoing trials that examine the role of vitamin K in vascular calcification to a greater extent.<sup>9</sup>

### Differential diagnosis

Calciphylaxis in the presence of vitamin K antagonist use should be distinguished from warfarin skin necrosis, a condition that is clinically similar. However, warfarin skin necrosis typically occurs a few days after the start of warfarin therapy, while calciphylaxis is associated with prolonged use.<sup>10</sup> Histological findings are able to

differentiate between the two, which is important since it determines the treatment of choice. Laboratory evaluation needs to be done as well and serves two major goals: to detect potential associated risk factors and to exclude other differential diagnoses. These diagnoses include vasculitis, atherosclerotic disease, cholesterol embolisation, nephrogenic systemic fibrosis, oxalate vasculopathy, and purpura fulminans.<sup>2,11</sup> Laboratory work-up is extensively described elsewhere but mainly includes parameters for infection, hypercoagulability, and autoimmune diseases.<sup>11</sup>

### Treatment

Due to its rarity, there are no evidence-based guidelines for the treatment of both *uraemic* and *non-uraemic* calciphylaxis and a combined approach is often implemented. If vitamin K antagonists are used, they should be stopped. In warfarin skin necrosis, this is the only necessary step. However, in calciphylaxis, it is also essential to restore calcium, phosphate, and parathyroid hormone homeostasis.<sup>10,11</sup> If this treatment fails, intravenous administration of sodium thiosulfate is another option. In a similar case to ours, in which vitamin D suppletion and replacement of acenocoumarol by LMWH did not induce any improvement, sodium thiosulfate was successfully administered.<sup>12</sup> In 2011, a review of 41 case reports described a success rate for sodium thiosulfate of more than 90%, although publication bias has to be considered.<sup>13</sup> Another option that seems to be successful is hyperbaric oxygen therapy, as more than half of the patients benefited from this treatment.<sup>14</sup>

With this case report, the authors want to point out that calciphylaxis is an important differential diagnosis in patients without end-stage renal disease as well, since this disease has a severe prognosis with a high mortality. Whether vitamin K antagonists are an independent risk factor for non-uraemic calciphylaxis has yet to be determined. Pathophysiological studies provide interesting new links, but epidemiological studies lack adequate designs to rule out selection bias and confounding by indication. Nevertheless, awareness of a possible association is essential, and internists need to know they should stop these drugs for an optimal treatment.

### DISCLOSURES

All authors declare no conflict of interest. No funding or financial support was received.

REFERENCES

1. Ng AT, Peng DH. Calciphylaxis. *Dermatol Ther.* 2011;24:256-62.
2. Nigwekar SU, Wolf M, Sterns RH, Hix JK. Calciphylaxis from Nonuremic Causes: A Systematic Review. *Clin J Am Soc Nephrol.* 2008;3:1139-43.
3. Kalajian AH, Malhotra PS, Callen JP, Parker LP. Calciphylaxis With Normal Renal and Parathyroid Function. *Arch Dermatol.* 2009;145:451-8.
4. Banerjee C, Woller SC, Holm JR, Stevens SM, Lahey MJ. Atypical calciphylaxis in a patient receiving warfarin then resolving with cessation of warfarin and application of hyperbaric oxygen therapy. *Clin Appl Thromb Hemost.* 2010;16:345-50.
5. Asobie N, Wong E, Cook MG. Calciphylaxis in a diabetic patient provoked by warfarin therapy. *Clin Exp Dermatol.* 2008;33:342-4.
6. Saifan C, Saad M, El-Charabaty E, El-Sayegh S. Warfarin-induced calciphylaxis: a case report and review of literature. *Int J Gen Med.* 2013;6:665-9.
7. Weenig RH, Sewell LD, Davis MD, McCarthy JT, Pittelkow MR. Calciphylaxis: natural history, risk factor analysis, and outcome. *J Am Acad Dermatol.* 2007;56:569-79.
8. Poterucha TJ, Goldhaber SZ. Warfarin and Vascular Calcification. *Am J Med.* 2016;129:635.e1-4.
9. Caluwé R, Pyfferoen L, De Boeck K, De Vriese AS. The effects of vitamin K supplementation and vitamin K antagonists on progression of vascular calcification: ongoing randomized controlled trials. *Clin Kidney J.* 2016;9:273-9.
10. Park JE, Byeon S, Kim HK, et al. Warfarin skin necrosis mimicking calciphylaxis in a patient with secondary hyperparathyroidism undergoing peritoneal dialysis. *Kidney Res Clin Pract.* 2016;35:55-8.
11. Jeong HS, Dominguez AR. Calciphylaxis: Controversies in Pathogenesis, Diagnosis and Treatment. *Am J Med Sci.* 2016;351:217-27.
12. Garcia CP, Roson E, Peon G, Abalde MT, De La Torre C. Calciphylaxis treated with sodium thiosulfate: report of two cases. *Dermatol Online J.* 2013;19:19616.
13. Auriemma M, Carbone A, Di Liberato L, et al. Treatment of cutaneous calciphylaxis with sodium thiosulfate: two case reports and a review of the literature. *Am J Clin Dermatol.* 2011;12:339-46.
14. An J, Devaney B, Ooi KY, Ford S, Frawley G, Menahem S. Hyperbaric oxygen in the treatment of calciphylaxis: A case series and literature review. *Nephrology (Carlton).* 2015;20:444-50.