

# Spontaneous, painful nail haemorrhages and onycholysis in a patient at high altitude

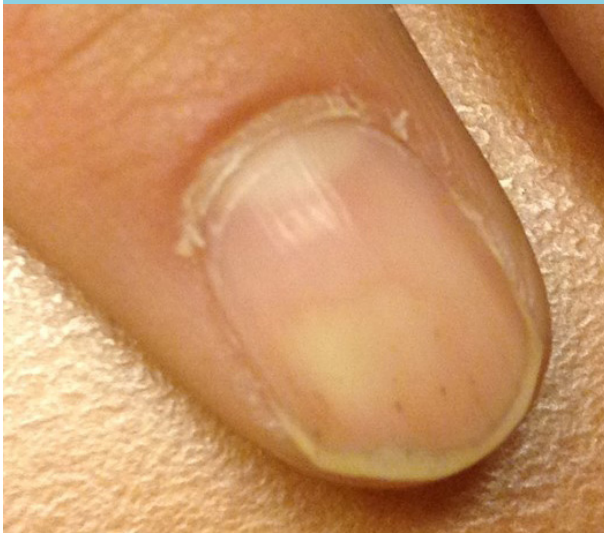
S.D. Marbus\*, M. van Vugt

Department of Internal Medicine, Division of Tropical Diseases, Academic Medical Centre, Amsterdam, the Netherlands, \*corresponding author: tel.: +31 (0)30-2742045, e-mail: sierk.marbus@rivm.nl

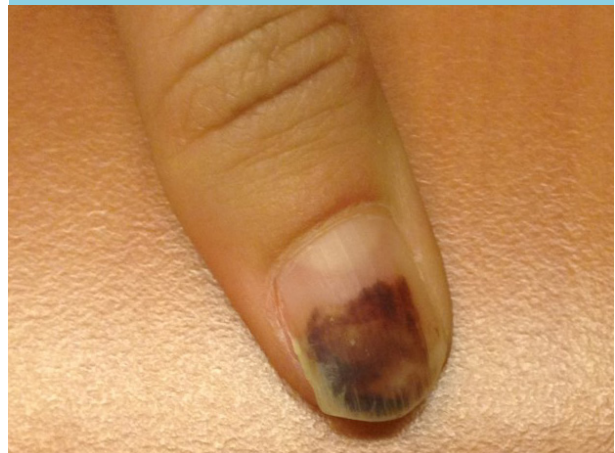
## CASE REPORT

A 23-year-old female patient presented with spontaneous appearance of nail haemorrhages on both hands after a tracking holiday in Peru and Bolivia. At altitudes above 3000 meters, she initially developed painful splinter haemorrhages (*figure 1*), followed by subungual haematoma (*figure 2*) and eventually distal onycholysis at all fingernails on both hands (*figure 3*). Remarkably, her toenails were spared. Her previous medical history included acne conglobata, for which she was recently treated with doxycycline 100 mg once daily for three months by her dermatologist. Other medication included malarone prophylaxis and ethinylestradiol/levonorgestrel. The remaining physical examination and blood analysis were within normal ranges

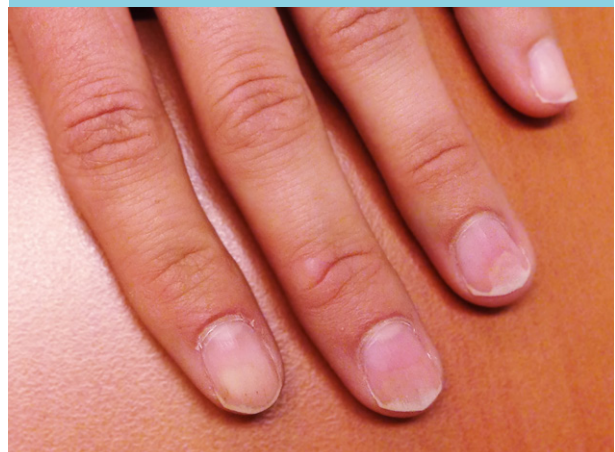**Figure 1.** Splinter haemorrhages of left fingernail



**Figure 2.** Subungual haematoma of right thumb



**Figure 3.** Distal onycholysis of left fingernails



**WHAT IS YOUR DIAGNOSIS?**

See page 273 for the answer to this photo quiz.