

Acute-onset breathlessness after a radiological procedure

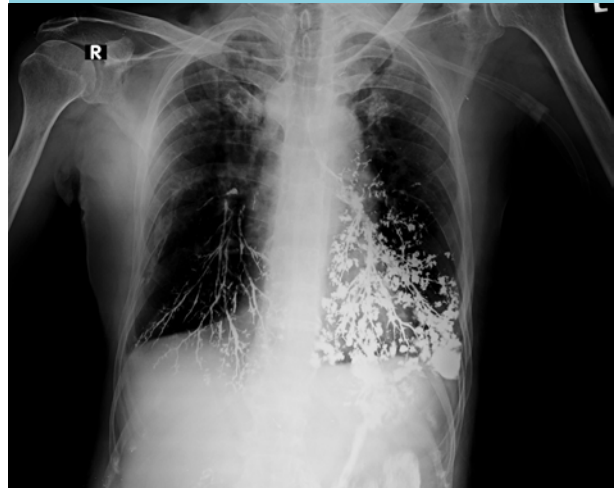
Y.K. Shejul*, R. Pendse, A. Kulkarni

Department of Medicine, BARC Hospital, Mumbai, India,

*corresponding author: tel.: +91 98 204 521 05, fax: 022 - 25506944, email: yogeshshejul@hotmail.com

A 76-year-old man with a background of chronic obstructive pulmonary disease presented with new-onset dysphagia. On examination, pooling of saliva in the pyriform fossa was noted. Systemic examination was otherwise unremarkable. He went on to have a barium swallow examination. During the procedure, he became breathless and oxygen saturation dropped to 85% on room air. Bilateral crackles and wheezing were noted on auscultation. He was transferred directly to our intensive care unit. Chest X-ray was performed immediately, which showed bilateral dense punctate foci and linear opacities in the alveoli and tracheobronchial tree, with greater involvement of the left side as compared with the right (*figure 1*). What is your diagnosis?

Figure 1. Chest X-ray showing bilateral dense punctate foci and linear opacities, with greater involvement of the left side as compared to the right



WHAT IS YOUR DIAGNOSIS?

See page 172 for the answer to this photo quiz.