

Zika virus and the current outbreak: an overview

M. Goeijenbier^{1,2}, L. Slobbe², A. van der Eijk¹, M. de Mendonça Melo², M.P.G. Koopmans¹, C.B.E.M. Reusken^{1*}

¹Department of Viroscience, Erasmus MC, the Netherlands, ²Department of Infectious Diseases, Havenziekenhuis and Institute for Tropical Diseases, Rotterdam, the Netherlands, *corresponding author: tel.: +31 (0)10-704 40 68, fax +31 (0)10-704 47 60, email: c.reusken@erasmusmc.nl

ABSTRACT

Zika virus (ZIKV), a mosquito-borne flavivirus closely related to yellow fever virus and dengue virus, is currently causing a large outbreak in the Americas. Historically, ZIKV infection was considered a sporadic, relatively mild disease characterised by fever, maculopapular rash, conjunctivitis and often arthralgia. However, current observational studies suggest that ZIKV may cause more severe neurological sequelae such as Guillain-Barre syndrome, and birth defects, mainly microcephaly, in babies of whom the mother was infected with ZIKV during pregnancy. This article provides a clinically focussed overview of ZIKV, with emphasis on the current outbreak, clinical manifestations, diagnostic tools and caveats.

KEYWORDS

Zika virus, microcephaly, flavivirus, Aedes, outbreak, Americas

BACKGROUND

In May 2015, the Pan American Health Organization (PAHO) issued an alert about possible autochthonous transmission of Zika virus (ZIKV) in Brazil, South America. Since then, the virus has spread widely in Middle and South America, and the Caribbean, affecting 29 countries and resulting in ten-thousands of probable and confirmed cases as of 22 February 2016.^{1,2} These include (former) European overseas countries and territories and due to intensive international travel, the risk of importing ZIKV to Europe has increased. On 11 December 2015 the first case of ZIKV imported from the New World was reported in the Netherlands.³ Since then, 30 cases,

imported from Suriname and some islands of the (former) overseas territories of the Netherlands, were diagnosed (as of 22 February 2016). Possible association of ZIKV with microcephaly in newborns and other neurological disorders urged the World Health Organization (WHO) to declare the outbreak of microcephaly-associated ZIKV a Public Health Emergency of International Concern on the 1 February.⁴ Co-circulation of dengue and chikungunya virus, which share overlapping clinical manifestations with ZIKV, complicates clinical diagnosis, while dengue virus, West Nile virus and yellow fever virus may cause cross-reactivity in serological diagnostic tests which severely hampers laboratory diagnosis of ZIKV infection in the outbreak region.⁵

Here, we briefly provide an overview of the current outbreak, and some characteristics of the virus, clinical manifestations and management of ZIKV infections, and finally the diagnostic tools which can be used.

EPIDEMIOLOGY

ZIKV is a member of the genus *Flavivirus*, family *Flaviviridae*. Other flaviviruses of importance to human health are dengue virus, West Nile virus, yellow fever virus, Japanese encephalitis virus and tick-borne encephalitis virus. ZIKV is most closely related to the New World flaviviruses St. Louis encephalitis virus, Rocio virus and Ilheus virus.^{5,6} ZIKV was first discovered in the Zika forest in Uganda in 1947 and incidental cases were reported for the next 60 years in both Africa and South-East Asia.⁶ In 2007, ZIKV caused an outbreak of mild disease in the Pacific, characterised by fever, rash, arthralgia and conjunctivitis in Micronesia. This was followed by an epidemic with an estimated 32,000 patients in French Polynesia in 2013-2014.⁷⁻⁹ Since then, the virus has extended its geographic distribution to

multiple countries in the Pacific Ocean and ZIKV emerged for the first time in the Americas on Easter Island, Chile in 2014.¹⁰ In May 2015, the authorities in Brazil confirmed autochthonous transmission in the northeast of the country and since then, the virus has spread rapidly in the region with ten-thousands of cases (*figure 1*). In addition, there is a ZIKV outbreak on the Cape Verde islands with approximately 7000 cases recorded since December 2015. The current outbreak in the Americas has led to an increase of travel-associated imported ZIKV cases to Europe with registered cases in Austria, Denmark, Finland, France, Germany, Ireland, Italy, Portugal, the Netherlands, Spain, Sweden, Switzerland and the United Kingdom.²

ZIKV is transmitted in a human-mosquito-human cycle involving *Aedes* mosquitoes. *Ae. aegypti* is the only species for which transmission outside Africa has been confirmed. Although competence for *Ae. albopictus*, a mosquito species established in large parts of Southern Europe and occasionally introduced into the Netherlands by trade of plants and used tires,¹¹ has been demonstrated in laboratory circumstances for the African lineage of ZIKV,¹² this mosquito species has never been implied in ZIKV epidemiology outside Africa.^{6,13,14} Blood transfusion mediated, perinatal and possible sexual transmission of ZIKV have been reported as well.^{6,15-20} The potential for transmission of ZIKV by other *Aedes* mosquitos in Europe is under investigation, but is considered to be low.

VIROLOGY

Viruses of the genus flavivirus are positive-stranded, enveloped RNA viruses with a single genome of approximately 11 kb. The ZIKV genome encodes for three structural proteins C, M and E, and seven non-structural proteins, NS1, NS2a, NS2b, NS3, NS4a, NS4b and NS5.^{6,21} Because the RNA-dependent-RNA-polymerase (NS5) is very

conserved among flaviviruses, this genomic region is often used as a target in pan-flavi molecular tests.

ZIKV belongs to the Spondweni serogroup, together with Spondweni virus which circulates in Sub-Saharan Africa and Papua New Guinea. Two lineages of ZIKV are recognised: the African lineage and the Asian lineage.⁶ The African lineage has not (yet) disseminated outside Africa. ZIKV strains circulating in the Americas are of the Asian lineage with 99.9% identity with the ZIKV strains circulating in French Polynesia in 2013-2014.²²

CLINICAL MANIFESTATIONS

Knowledge about the clinical course of ZIKV infection is based on a relatively small number of studies in comparison with other emerging pathogens. The first documented case of human ZIKV infection dates back to 1964 and describes a febrile illness that, without diagnostics proving ZIKV to be the causative agent, could easily have been caused by another arboviral infection, such as dengue or chikungunya.^{6,9} The majority of ZIKV infections seem to be asymptomatic, confirmed by data from outbreaks in Micronesia and French Polynesia in 2007 and 2013-2014, respectively, with symptoms in only 18% of patients with documented antibodies. However, overestimation of the number of asymptomatic infections may be considered, since serological cross reactivity may have occurred with other circulating flaviviruses such as dengue virus, West Nile virus and Japanese encephalitis virus.²³ Other evidence for the occurrence of asymptomatic infections came from studies in blood donors that show a significant seroprevalence.^{24,25}

After an incubation period of 3-12 days, symptomatic patients generally present with fever, arthralgia, myalgia, headache, non-purulent conjunctivitis, and maculopapular rash.^{26,27} The arthralgia is most often localised in the small joints of hands and feet and could be accompanied with joint swelling.^{6,7,9} Other manifestations include anorexia, nausea and vomiting, diarrhoea, abdominal pain, sore throat, retro-orbital pain, a burning sensation of the palms and soles and vertigo.^{6,7,9,28} In contrast to dengue virus infection, haemorrhagic complications seem rarely to be associated with ZIKV, and leukopenia and thrombocytopenia seem to only occur in a minority of ZIKV cases.^{9,28} Oedema of the extremities, noticed as swelling of especially the ankles, is considered to be quite specific for ZIKV in comparison with dengue and chikungunya virus.^{9,23} Although not much is known yet about the morbidity and mortality of the current ZIKV outbreak, it is assumed that in comparison with other arboviral infections, ZIKV is relatively mild and self-limiting. Currently, three deaths have been linked to ZIKV infection, although, the level of evidence for causality

Figure 1. Current active spread of ZIKV
Source: <http://www.cdc.gov/zika/>

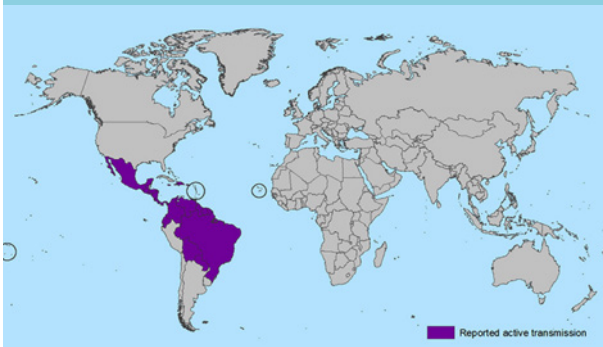


Table 1. Comparison of Zika, chikungunya and dengue virus

	Zika virus	Chikungunya	Dengue
Myalgia	++	++	++
Arthralgia	+	++	++
Oedema	++, extremities	-	-
Conjunctivitis	++	++	+ mild conjunctivitis/conjunctival injection
Haemorrhage	Described once	None	Yes, in severe cases
Leukopenia	-	++	++
Thrombocytopenia	-	++	++
Fever	+	++	++
Rash	++	++	+
Morbidity/mortality	Low, estimated to be below 1%		25% symptomatic with 2.5% mortality in hospitalised cases
Sequelae	Possible link to GBS, encephalitis and microcephaly	Long-term arthralgia up to 24 months	Link to GBS, haemophagocytosis and encephalitis
Vaccination	None	None	Experimental
Diagnostics available	PCR urine and serum, serology under development	PCR, serology	PCR, serology, antigen tests
Based on references: 9,23,28,46-49 GBS = Guillain-Barre syndrome; PCR = polymerase chain reaction.			

remains doubtful.^{9,23} In the current ZIKV outbreak, much attention has been drawn towards potential neurological complications of ZIKV infection, where the main concerns are the possible association of ZIKV infection with Guillain-Barré syndrome (GBS) and microcephaly as a neurological manifestations in newborns.²⁹⁻³¹

Both complications were observed in the outbreak in French Polynesia²⁹ as well as in the current outbreak, with Brazil reporting more than 4700 suspected cases of microcephaly since May 2015. One should bear in mind that only a minority of these 4700 cases remained linked to ZIKV infection after correction for differing criteria for microcephaly, birth weight and potential other factors predisposing to microcephaly. ZIKV RNA was identified in the amniotic fluid of two women whose foetuses had microcephaly.³⁰ The potential causality is further supported by the full genome detection of the virus in the brain of a foetus with microcephaly.³¹ Several countries reported spikes in GBS cases in January 2016.^{28-30,32,33} Recently, a confirmed imported ZIKV case developed GBS in the Netherlands (*van den Beukel et al. submitted*). The causality between ZIKV infection and GBS is not yet proven and a possible mechanism can only be hypothesised. Hypothetically, a possible underlying mechanism could be similar to that of *Campylobacter*-driven GBS, involving molecular mimicry where antibodies against the pathogen

cross react with antigens on nerve tissue and thereby damage healthy nerves.³⁴ Alternatively, the GBS-like symptoms may be caused by direct virus-induced nerve damage.

While evidence supports the potential for foetal infection with ZIKV, much remains unknown about the strength of this association, and – if confirmed – the prevalence of intra-uterine infections and subsequent complications in ZIKV-infected pregnant women. Similar to other infections during pregnancy, it is likely that effects – should they occur – differ depending on the timing of the infection, potentially ranging from miscarriage, to birth defects, to the birth of apparently healthy babies with or without some more subtle sequelae. Studies have shown that physiological skewing of the immune system during pregnancy to a more immune tolerant state may lead to delayed clearance of infection, and thus prolonged viraemia and increased risk of foetal infection. Of course, all this assumes a combination with a potential neurotropism for ZIKV which has not yet been proven in animal models. Furthermore, it remains to be seen whether specific ZIKV strains have changed in virulence or whether possible complications such as GBS and microcephaly were unnoticed in the past due to their relatively low absolute numbers. Additional studies, both epidemiological and animal models, are needed to establish the possible

association between ZIKV infection and these complications.

CLINICAL MANAGEMENT AND TREATMENT

No specific antiviral treatment is available thus, if needed, care is supportive. However, the disease is self-limiting and mainly lasts no longer than seven days in the majority of cases. Since there is no evidence yet for haemorrhagic complications in ZIKV, the use of non-steroidal anti-inflammatory drugs (NSAIDs) in case of (severe) arthralgia is not strictly contraindicated.²⁸ However, in case of uncertainty of the diagnosis and the possibility of a dengue virus infection pending the test results, NSAIDs should still be avoided. In daily practice, normal thrombocyte counts could favour the use of NSAIDs.²⁸ Where possible acetaminophen, which does not alter platelet aggregation, could be used to suppress milder symptoms.

In case of GBS, intravenous immunoglobulin might be effective, although severe GBS cases may require intensive care, including mechanical ventilation.^{29,35} Currently, the Centers for Disease Control (CDC) recommends monitoring of foetal development in pregnant women with evidence of ZIKV infection by 3-4 weekly ultrasounds. This strategy would increase the knowledge about causality of ZIKV-infected pregnant women and birth defects. However, the benefits for the mother and unborn child are limited due to the lack of treatment or intervention other than abortion.^{35,36} Currently, the Dutch National Institute for Public Health and the Environment (RIVM), advises pregnant women, when possible, to postpone non-essential travel to ZIKV outbreak areas. If travel is necessary, mosquito repellents, long sleeved clothing and an impregnated bed net should be used. When a pregnant woman has a molecular proven ZIKV infection, follow-up in a specialised perinatal care centre during the pregnancy is recommended (http://www.rivm.nl/dsresource?objectid=rivmp:304780&type=org&disposition=inline&ns_nc=1).

DIFFERENTIAL DIAGNOSIS

Since the majority of symptomatic ZIKV patients present with arthralgia, fever and rash, the differential diagnosis of suspected ZIKV includes viruses with similar clinical manifestations, like chikungunya and dengue virus.^{6,37} Based on the geographical exposure, the differential diagnosis can be broadened. For the Americas the alphaviruses Mayaro virus, Oropouche virus and equine encephalitis virus, as well as West Nile virus and La Crosse encephalitis virus may be considered. Also, malaria and

rickettsioses may be taken into account.^{28,38} The differential diagnosis can be broadened to other acute virus infections including influenza, rubella and measles, or non-viral diseases.

DIAGNOSTICS

Information on ZIKV infection kinetics is indispensable for proper interpretation of diagnostic results. The information available in literature is limited to Asian ZIKV and concerns only a few cases.³⁹ Viraemia seems low and short. ZIKV shows a peak in viral load when symptoms appear and can be detected up to 3-5 days after onset of symptoms with reverse transcription polymerase chain reaction (RT-PCR).^{32,40,41} ZIKV RNA has been detected in saliva, nasopharyngeal swabs, urine and semen as well.^{17,20,42-44} A combination of blood, urine and saliva samples is advised to increase both the sensitivity of molecular detection and the detection window. The viral load in urine seems to be higher than in blood/serum, is observed to peak 5-7 days upon onset of symptoms and has a much longer detection window (detection > 28 days post-onset of symptoms have been described) than blood, although sensitivity of detection at these time points remains to be determined.³⁹ A combination of blood and saliva sampling increased the ZIKV detection rate by 19% but did not increase the detection window.¹⁷ ZIKV specific IgM seems to appear 3-5 days and IgG 10 days after onset of illness in patients without previous flavivirus infections. Typically in flavivirus infections IgM develops within a few days upon onset of symptoms and is generally detectable up to three months. IgG develops a few days later and is typically detectable for months to years.^{5,32} More studies are needed to validate these observations.

Multiple real-time and conventional RT-PCRs specific for ZIKV or pan-flavi, and serology tests have been described in the literature or are commercially available.³⁹ All still need extensive validation in the context of both the outbreak region and areas where cases are imported. Patients in the current outbreak region will have a high level flavivirus background while travellers returning to Europe will generally have been exposed to these viruses to a far lesser extent. This is especially important for serology-based testing as extensive cross-reactivity between antibodies triggered by different flavivirus infections or vaccination exist. Furthermore, an acute ZIKV infection might boost cross-reactive antibodies due to prior flavivirus infection/vaccination. This will complicate diagnosis based on serology in the outbreak region and will require detailed knowledge on the vaccination history for Japanese encephalitis virus, tick-borne encephalitis virus and yellow fever virus when interpreting diagnostic results of returning travellers.^{5,39,45} The availability of

discriminating ZIKV serology is especially important to identify asymptomatic ZIKV infections in pregnant women due to putative teratogenic effects.

CONCLUDING REMARKS

The current outbreak of ZIKV in the Americas, including Dutch (former) overseas territories, has direct implications for infectious disease specialists, obstetricians, midwives and microbiologists in the Netherlands. Besides dengue and chikungunya virus, clinicians should also include ZIKV in their differential diagnosis of fever with rash in travellers returning from Asia, Africa, the Pacific ocean area and the Americas. Although ZIKV infections usually manifest as asymptomatic or mild, infection of women during pregnancy requires intensive follow-up due to putative correlation with neurological defects in newborns, until the link between ZIKV and microcephaly has been substantiated or rejected. Determination of asymptomatic ZIKV infection during pregnancy is complicated due to extensive cross-reactivity in serology-based testing. For diagnosis in acutely infected patients a combination of blood, urine and saliva will increase the sensitivity and window of ZIKV detection. Current ongoing international collaborative studies might give insight in these issues on short notice.

DISCLOSURES

The authors declare no conflict of interest. No funding or financial support was received.

REFERENCES

- WHO. WHO situation report: neurological syndrome and congenital anomalies, 5 february 2016: WHO; 2016 [cited 2016 0602]. Available from: http://apps.who.int/iris/bitstream/10665/204348/1/zikasitrep_5Feb2016_eng.pdf?ua=1.
- ECDC. Epidemiological update: Outbreaks of Zika virus and complications potentially linked to the Zika virus infection; 5 February 2016: ECDC; 2016 [cited 2016 0602]. Available from: http://ecdc.europa.eu/en/press/news/_layouts/forms/News_DispForm.aspx?ID=1353&List=8db7286c-fe2d-476c-9133-18ff4cb1b568&Source=http%3A%2F%2Fecdc%2Eeuropa%2Eeu%2Fen%2Fhealthtopics%2Fzika%5Fvirus%5Finfection%2FPages%2Findex%2Easpx&preview=yes&pdf=yes.
- ProMED-mail. Zika virus – Netherlands ex Suriname Archive Number: 20151213.3858300: ProMED-mail; 2015 [cited 2016 0702]. Available from: <http://www.promedmail.org/>.
- WHO. WHO statement on the first meeting of the International Health Regulations (2005) (IHR 2005) Emergency Committee on Zika virus and observed increase in neurological disorders and neonatal malformations: WHO; 2016 [cited 2016 04022016]. Available from: <http://www.who.int/mediacentre/news/statements/2016/1st-emergency-committee-zika/en/>.
- Cleton N, Koopmans M, Reimerink J, Godeke GJ, Reusken C. Come fly with me: review of clinically important arboviruses for global travelers. *J Clin Virol.* 2012;55:191-203.
- Hayes EB. Zika virus outside Africa. *Emerg Infect Dis.* 2009;15:1347-50.
- Duffy MR, Chen TH, Hancock WT, et al. Zika virus outbreak on Yap Island, Federated States of Micronesia. *N Engl J Med.* 2009;360:2536-43.
- Cao-Lormeau VM, Roche C, Teissier A, et al. Zika virus, French polynesia, South pacific, 2013. *Emerg Infect Dis.* 2014;20:1085-6.
- Loos S, Mallet HP, Leparc Goffart I, Gauthier V, Cardoso T, Herida M. Current Zika virus epidemiology and recent epidemics. *Med Mal Infect.* 2014;44:302-7.
- Tognarelli J, Ulloa S, Villagra E, et al. A report on the outbreak of Zika virus on Easter Island, South Pacific, 2014. *Arch Virol.* 2016;161:665-8.
- Scholte EJ, Dijkstra E, Blok H, et al. Accidental importation of the mosquito *Aedes albopictus* into the Netherlands: a survey of mosquito distribution and the presence of dengue virus. *Med Vet Entomol.* 2008;22:352-8.
- Wong PS, Li MZ, Chong CS, Ng LC, Tan CH. *Aedes (Stegomyia) albopictus* (Skuse): a potential vector of Zika virus in Singapore. *PLoS Negl Trop Dis.* 2013;7:e2348.
- Grard G, Caron M, Mombo IM, et al. Zika virus in Gabon (Central Africa)--2007: a new threat from *Aedes albopictus*? *PLoS Negl Trop Dis.* 2014;8:e2681.
- Diallo D, Sall AA, Diagne CT, et al. Zika virus emergence in mosquitoes in southeastern Senegal, 2011. *PLoS One.* 2014;9:e109442.
- Musso D, Nhan T, Robin E, et al. Potential for Zika virus transmission through blood transfusion demonstrated during an outbreak in French Polynesia, November 2013 to February 2014. *Euro Surveill.* 2014;19.
- Musso D, Roche C, Robin E, Nhan T, Teissier A, Cao-Lormeau VM. Potential sexual transmission of Zika virus. *Emerg Infect Dis.* 2015;21:359-61.
- Musso D, Roche C, Nhan TX, Robin E, Teissier A, Cao-Lormeau VM. Detection of Zika virus in saliva. *J Clin Virol.* 2015;68:53-5.
- Besnard M, Lastere S, Teissier A, Cao-Lormeau V, Musso D. Evidence of perinatal transmission of Zika virus, French Polynesia, December 2013 and February 2014. *Euro Surveill.* 2014;19.
- Foy BD, Kobylinski KC, Chilson Foy JL, et al. Probable non-vector-borne transmission of Zika virus, Colorado, USA. *Emerg Infect Dis.* 2011;17:880-2.
- Atkinson B, Hearn P, Afrough B, et al. Detection of Zika virus in semen *Emerg Infect Dis.* 2016;22.
- Leyssen P, De CE, Neyts J. Perspectives for the treatment of infections with Flaviviridae. *Clin Microbiol Rev.* 2000;13:67-82, table.
- Charrel R, Leparc Goffart I, Pas S, de Lamballerie X, Koopmans M, Reusken C. State of knowledge on Zika virus for an adequate laboratory response. *Bull World Health Organ.* 2016;E-pub: 10 Feb 2016.
- Gatherer D, Kohl A. Zika virus: a previously slow pandemic spreads rapidly through the Americas. *J Gen Virol.* 2016; 97:269-73.
- Musso D, Nhan T, Robin E, et al. Potential for Zika virus transmission through blood transfusion demonstrated during an outbreak in French Polynesia, November 2013 to February 2014. *Euro Surveill.* 2014;19.
- Aubry M, Finke J, Teissier A, et al. Seroprevalence of arboviruses among blood donors in French Polynesia, 2011-2013. *Int J Infect Dis.* 2015;41:11-2.
- Fauci AS, Morens DM. Zika Virus in the Americas – Yet Another Arbovirus Threat. *N Engl J Med.* 2016;374:601-4.
- Tappe D, Nachtigall S, Kapaun A, Schnitzler P, Gunther S, Schmidt-Chanasit J. Acute Zika virus infection after travel to Malaysian Borneo, September 2014. *Emerg Infect Dis.* 2015;21:911-3.
- Kelsler EA. Meet dengue's cousin, Zika. *Microbes Infect.* 2015; pii: S1286-4579(15)00259-2;doi:10.1016/j.micinf.2015.12.003 [Epub ahead of print]
- Oehler E, Watrin L, Larre P, et al. Zika virus infection complicated by Guillain-Barre syndrome--case report, French Polynesia, December 2013. *Euro Surveill.* 2014;19(9).
- Schuler-Faccini L, Ribeiro EM, Feitosa IM, et al. Possible Association Between Zika Virus Infection and Microcephaly – Brazil, 2015. *MMWR Morb Mortal Wkly Rep.* 2016;65:59-62.
- Malak J, Korva M, Tul N, et al. Zika Virus Associated with Microcephaly. *N Engl J Med.* 2016 Feb 10 [Epub ahead of print].

32. Lanciotti RS, Kosoy OL, Laven JJ, et al. Genetic and serologic properties of Zika virus associated with an epidemic, Yap State, Micronesia, 2007. *Emerg Infect Dis.* 2008;14:1232-9.
33. Ventura CV, Maia M, Bravo-Filho V, Gois AL, Belfort R, Jr. Zika virus in Brazil and macular atrophy in a child with microcephaly. *Lancet.* 2016;387:228.
34. Loshaj-Shala A, Regazzoni L, Daci A, et al. Guillain Barre syndrome (GBS): new insights in the molecular mimicry between C. jejuni and human peripheral nerve (HPN) proteins. *J Neuroimmunol.* 2015;289:168-76.
35. Lucey DR, Gostin LO. The Emerging Zika Pandemic: Enhancing Preparedness. *JAMA.* 2016 Jan 27. doi: 10.1001/jama.2016.0904. [Epub ahead of print]
36. Kmietowicz Z. Questions your patients may have about Zika virus. *BMJ.* 2016;352:i649.
37. Heang V, Yasuda CY, Sovann L, et al. Zika virus infection, Cambodia, 2010. *Emerg Infect Dis.* 2012;18:349-51.
38. Beltrame A, Angheben A, Bisoffi Z, et al. Imported Chikungunya Infection, Italy. *Emerg Infect Dis.* 2007;13:1264-6.
39. Reusken C. State of knowledge on Zika virus for an adequate laboratory response. *Bulletin.* 2016.
40. Enfissi A, Codrington J, Roosblad J, Kazanji M, Rousset D. Zika virus genome from the Americas. *Lancet.* 2016;387:227-8.
41. Campos GS, Bandeira AC, Sardi SI. Zika Virus Outbreak, Bahia, Brazil. *Emerg Infect Dis.* 2015;21:1885-6.
42. Gourinat AC, O'Connor O, Calvez E, Goarant C, Dupont-Rouzeyrol M. Detection of Zika virus in urine. *Emerg Infect Dis.* 2015;21:84-6.
43. Leung GH, Baird RW, Druce J, Anstey NM. Zika virus infection in Australia following a monkey bite in Indonesia. *Southeast Asian J Trop Med Public Health.* 2015;46:460-4.
44. Shinohara K, Kutsuna S, Takasaki T, et al. Zika fever imported from Thailand to Japan, and diagnosed by PCR in the urines. *J Travel Med.* 2016;23.
45. Cleton NB, Godeke GJ, Reimerink J, et al. Spot the difference-development of a syndrome based protein microarray for specific serological detection of multiple flavivirus infections in travelers. *PLoS Negl Trop Dis.* 2015;9:e0003580.
46. Centers for Disease Control and Prevention. Zika virus – What clinicians need to know? Clinician Outreach and Communication Activity (COCA) Call, January 26, 2016. Available at: http://emergency.cdc.gov/coca/ppt/2016/01_26_16_zika.pdf (Accessed February 1, 2016)
47. Andrew KI, Falconara B, Claudia ME, Romero-Vivasa J. Simple Prognostic Criteria Can Definitively Identify Patients Who Develop Severe Versus Non-Severe Dengue Disease, or Have Other Febrile Illnesses. *Clin Med Res.* 2011;4:33-44.
48. World Health Organization. Dengue haemorrhagic fever: diagnosis, treatment, prevention and control. Geneva: World Health Organization, 2009.
49. Karimi O, Goorhuis A, Schinkel J, et al. Thrombocytopenia and subcutaneous bleedings in a patient with Zika virus infection. *Lancet.* 2016 Feb 19. pii: S0140-6736(16)00502-X. doi: 10.1016/S0140-6736(16)00502-X. [Epub ahead of print]