

# A 22-year-old man with deep vein thrombosis of the left leg

V. Weeda<sup>1\*</sup>, J. Bosma<sup>2</sup>, W. Vasmel<sup>2</sup>, A. Wust<sup>3</sup>, R. van Nieuwenhuizen<sup>1</sup>

Departments of <sup>1</sup>Surgery, <sup>2</sup>Internal Medicine, <sup>3</sup>Radiology, Sint Lucas Andreas Hospital, Amsterdam, the Netherlands, \*corresponding author: email: v.weeda@slaz.nl

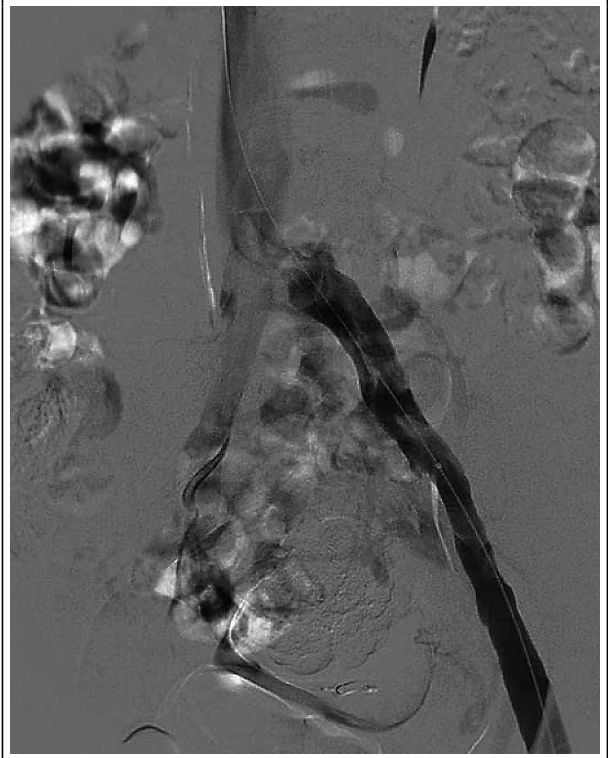
## CASE REPORT

A 22-year-old man presented to our emergency department with a two-day history of progressive swelling of the left lower extremity. He denied trauma, immobilisation, dyspnoea or chest pain. The medical history was remarkable for left-sided Perthes disease. There was no medical or family history of thromboembolic disease. Physical examination revealed marked swelling and tenderness of the left leg. Duplex ultrasonography demonstrated acute deep venous thrombosis extending from the left common iliac vein down through the veins of the calf. To evaluate a potential intra-abdominal cause, computed tomography of the abdomen was performed, which showed widening of the external and common iliac veins but did not reveal the cause of the thrombosis. After initial thrombosis treatment and thrombolysis, started to prevent post-thrombotic syndrome, a venogram was performed (*figure 1*).

## WHAT IS YOUR DIAGNOSIS?

See page 504 for the answer to this photo quiz.

**Figure 1.** Venogram



## DIAGNOSIS

The venogram disclosed compression of the left common iliac vein, suggesting the diagnosis of May-Thurner syndrome (MTS). In 1956, May and Thurner reported the presence of focal intimal thickening with formation of septa in the left common iliac vein in 22% of autopsies.<sup>1</sup> MTS, or iliac vein compression syndrome, is defined as compression of the left iliac vein against the lumbar vertebrae by the overlying right common iliac artery. It has been proposed that the pulsatile artery may cause repetitive injury to the left iliac vein, resulting in progressive intimal fibrosis and development of occlusive symptoms. A review of the literature shows that MTS is most common in female patients between the ages of 20-50 years, without clear reasons for this predilection.<sup>2</sup>

MTS is estimated to occur in 2-5% of patients undergoing evaluation for a lower extremity venous disorder, typically presenting as a large iliofemoral deep venous thrombosis or as chronic venous insufficiency.<sup>3</sup> The diagnosis of MTS is made by venous duplex ultrasound and/or computed tomography or magnetic resonance imaging of the abdomen and pelvis, which can be utilised to estimate the degree of stenosis and to investigate other anatomic variations or causes of external compression on the iliac vein.

In addition to anticoagulant treatment, endovascular management is the preferred treatment for patients with deep venous thrombosis due to MTS. This treatment modality allows for catheter-directed thrombolysis and stent placement to treat mechanical entrapment and prevent post-thrombotic syndrome.<sup>2,4,5</sup> A study evaluating iliac vein stenting in MTS patients shows primary patency rates of 88% at 12 months and 84% at 24 months of follow-up.<sup>6</sup> When endovascular therapy fails, surgical management may be indicated. Iliocaval or inferior vena cava reconstruction has primary and secondary three-year patency rates of 54% and 62%.<sup>7</sup>

Interestingly, a recent retrospective study found that the anatomic variant defining MTS exists in a significant

number of asymptomatic individuals, raising the question whether compression is the sole causal factor in symptomatic patients.<sup>8</sup> MTS should be considered in patients with left-sided deep venous thrombosis extending at the iliac level, which in such cases may be poorly responsive to anticoagulation alone. Although patency rates of thrombolysis and stent placement are low, anticoagulant treatment alone is unlikely to be successful.<sup>7</sup>

Our patient was initially treated with subcutaneously administered tinzaparin, followed by venogram with percutaneous transluminal angioplasty and thrombolysis. After two days of urokinase treatment a stent was placed in the common iliac vein. The patient was put on lifelong oral anticoagulant treatment.

## REFERENCES

1. May R, Thurner JP. The cause of the predominantly sinistral occurrence of thrombosis of the pelvic veins. *Angiology*. 1957;8:419-27.
2. O'Sullivan GJ, Semba CP, Bittner CA, et al. Endovascular management of iliac vein compression (May-Thurner) Syndrome. *J Vasc Int Rad*. 2000;11:832-6.
3. Mousa AY, AbuRahma AF. May-Thurner syndrome: update and review. *Ann Vasc Surg*. 2013;27:984-95.
4. Kibbe MR, Ujiki M, Goodwin AL, Eskandari M, Yao J, Matsumura J. Iliac vein compression in an asymptomatic patient population. *J Vasc Surg*. 2004;39:937-43.
5. Patel NH, Stookey KR, Ketcham DB, Cragg AH. Endovascular management of acute extensive iliofemoral deep venous thrombosis caused by May-Thurner syndrome. *J Vasc Interv Radiol*. 2000;11:1297-302.
6. Park JY, Ahn JH, Jeon YS, Cho SG, Kim JY, Hong KC. Iliac vein stenting as a durable option for residual stenosis after catheter-directed thrombolysis and angioplasty of iliofemoral deep vein thrombosis secondary to May-Thurner. *Phlebology*. 2013;29:461-70.
7. Brazeau NF, Harvey HB, Pinto EG, Deipolyi A, Hesketh RL, Oklu R. May-Thurner syndrome: diagnosis and management. *Vasa*. 2013;42:96-105.
8. Lamont JP, Pearl GJ, Patetsios P, et al. Prospective evaluation of endoluminal venous stents in the treatment of the May-Thurner syndrome. *Ann Vasc Surg*. 2002;16:61-4.