

A small abscess with severe complications

S.P.J. Awater^{1*}, E.H. Gisolf¹, C. Richter^{1,2}

Departments of ¹Internal Medicine and ²Infectious Diseases, Rijnstate Hospital, Arnhem, the Netherlands, *corresponding author: e-mail: sawater@rijnstate.nl

CASE REPORT

A 24-year-old Somali male, living in the Netherlands for two years, was admitted with a progressive headache and a suppurating abscess on the forehead, which had been present for six weeks.

The weeks before, this abscess had been incised twice and treatment with amoxicillin/clavulanic acid had been given (*figure 1*). However, the swelling increased in size and his condition deteriorated. He developed symptoms of nausea and vomiting, headache, drowsiness, impaired trunk balance and impaired motor function of the right arm and leg, without cough.

On physical examination he had a Glasgow Coma Scale score of E2M1V1, a temperature of 38 °C and neck stiffness. The swelling on the forehead was 3 inches in diameter, and he had a third nerve palsy. Further evaluation revealed a mildly elevated C-reactive protein (44 mg/l), a negative HIV test and normal chest X-ray.

A MRI scan of the cerebrum showed a large fluid collection in the subcutaneous tissue and the temporal muscle. A defect in the frontal bone communicated with an epidural fluid collection, causing a marked midline shift to the right. Along the left hemisphere there was meningeal thickening and enhancement (*figure 2*).

WHAT IS YOUR DIAGNOSIS?

See page 377 for the answer to this photo quiz.

Figure 1. Abscess on the forehead with small incision

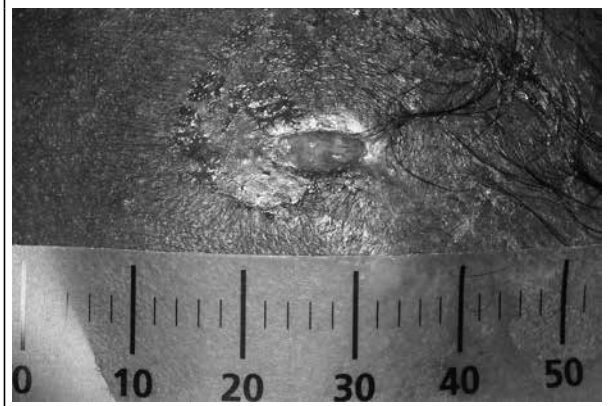
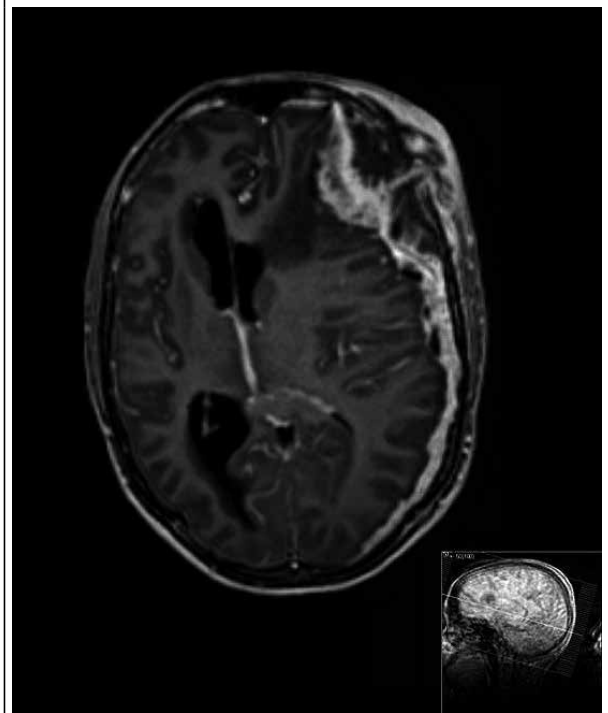


Figure 2. MRI scan (transversal plane) of the cerebrum showing a fluid collection in the subcutaneous tissue and a midline shift to the right caused by an epidural fluid collection and meningeal thickening on the left side.



DIAGNOSIS

The diagnosis of extrapulmonary tuberculosis was confirmed by a positive polymerase chain reaction and culture of the drained fluid for *Mycobacterium tuberculosis*. Our patient had an extensive tuberculosis with meningeal, epidural and bone localisation (figures 3 and 4). We started antituberculosis medication with rifampicin, pyrazinamide, ethambutol and isoniazid and in addition intravenous dexamethasone (20 mg once daily). After several days the diminished level of consciousness improved and his neurological symptoms recovered. After five weeks of therapy nearly all his symptoms had disappeared. The positive culture for *M. tuberculosis* was sensitive to all prescribed drugs.

In the Netherlands, migrants from Somalia have by far the highest annual incidence of tuberculosis (711 per 100,000) compared with all other population groups. They accounted for 18% of all diagnosed tuberculosis patients in 2012. Central nervous system tuberculosis is the most severe form of extrapulmonary tuberculosis; it accounts for about 1.5% of the annual cases of tuberculosis in the Netherlands (Mrs. E. Slump, Tuberculosis Surveillance Consultant, Royal Netherlands Tuberculosis Foundation, 2014; Personal communication by email). It is associated with a high mortality and severe neurological sequelae, particularly in multi-drug resistant (MDR) tuberculosis. In Somalia a high prevalence of MDR tuberculosis has been reported: 5.2% of the newly diagnosed pulmonary tuberculosis patients. However, in the Netherlands the proportion of MDR tuberculosis between 2000 and 2014

Figure 3. MRI scan (sagittal plane) of the cerebrum showing the epidural fluid collection and meningeal thickening

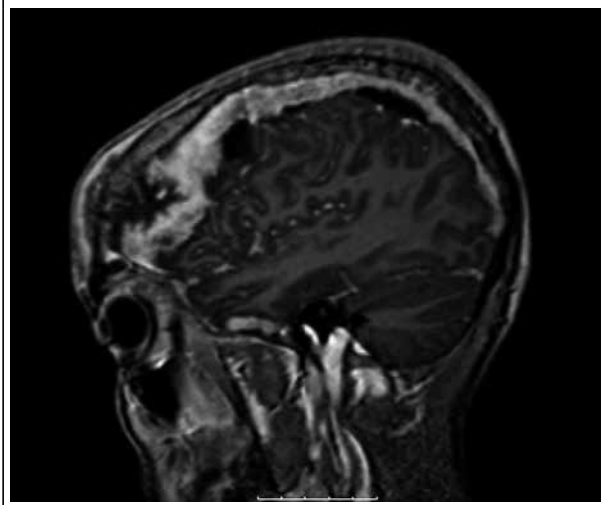
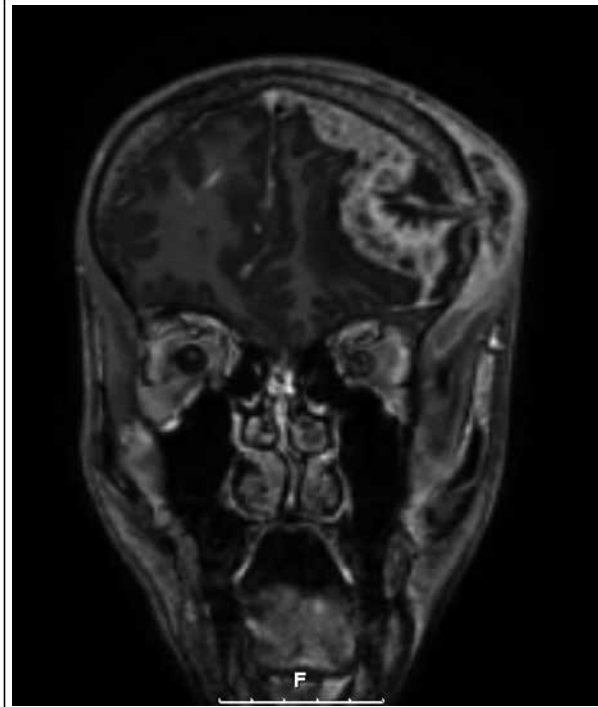


Figure 4. MRI scan (coronal plane) of the cerebrum showing the midline shift to the right caused by the epidural fluid collection



in Somalian migrants was only 1.7%, with two out of 147 patients in 2013. Rapid diagnosis and early treatment are crucial. Therefore, treatment should not be delayed and needs to be immediately started after direct auramine/Ziehl-Neelsen stain and the determination of polymerase chain reaction for *M. tuberculosis*, awaiting the results of tuberculosis culture and susceptibility testing, which usually takes several weeks.^{1,3}

In our case, we had a doctors delay of three weeks, because an incision was made and antibiotics were given without performing the appropriate diagnostic tests. This case report shows how important it is to consider tuberculosis in skin abscesses in people originating from tuberculosis endemic countries. Even a small skin lesion can have major consequences, as shown in our patient.

REFERENCES

1. Sheu JJ, Yuan RY, Yang CC. Predictors for outcome and treatment delay in patients with tuberculosis meningitis. *Am J Med Sci.* 2009;338:134-9.
2. Cárdenas G, Soto-Hernández JL. The many faces of central nervous system tuberculosis. *Arch Neurol.* 2011;68:1078.
3. Sindani I, Fitzpatrick C, Falzon D, et al. Multidrug-resistant Tuberculosis, Somalia, 2010–2011. *Emerg Infect Dis.* 2013;19:478-80.