

A 28-year-old pregnant woman with a very rare cause of jugular vein thrombosis

R. van den Broek^{1*}, M. van Balen², J. Blaauwgeers³, M. ten Wolde¹

Departments of ¹Internal Medicine, ²Gynaecology and ³Pathology, Flevoziekenhuis, Almere, the Netherlands, *corresponding author tel: +31 (0)36-8688717, e-mail: robertvandenbroek@gmail.com

ABSTRACT

During pregnancy, venous thrombosis of the distal extremities is not uncommon. However, thrombosis in the upper part of the body, such as jugular vein thrombosis, is rare. If underlying causes such as ovarian hyperstimulation syndrome (OHSS) or septic thrombophlebitis (Lemierre's syndrome) are excluded, a serous borderline ovary tumour (BOT) must be considered and MR imaging of the abdomen could be performed to find a primary tumour mass.

KEYWORDS

Cervical lymphadenopathy, jugular vein thrombosis, pregnancy, serous borderline ovarian tumour

INTRODUCTION

The risk of developing deep venous thrombosis is higher in pregnant women as compared with non-pregnant women of childbearing age.^{1,3} In the vast majority of cases, thrombosis develops in the lower extremities.^{4,5} Thrombosis in the upper extremities or in the internal jugular vein in pregnancy is a very rare complication and warrants further diagnostic work-up.⁶ Here we report a very unusual cause of jugular vein thrombosis in a 28-year-old pregnant woman who presented at our clinic.

CASE REPORT

A 32-week pregnant 28-year-old woman was referred to our hospital by her general practitioner. She was not using any medication and the current pregnancy had been unremarkable except for intrauterine growth restriction of the foetus since the first trimester. Physical

What was known on this topic?

Jugular vein thrombosis in pregnancy is rare. It is described as a result of ovarian hyperstimulation syndrome (OHSS) in pregnancies achieved with artificial reproductive technologies (ART) or as a result of Lemierre's syndrome. Jugular vein thrombosis can also be the first symptom of a serous borderline ovary tumour (BOT) due to local lymphadenopathy related to implants, but this is extremely rare.

What does this case add?

This case is the first description of a jugular vein thrombosis as first symptom of a serous BOT in a pregnant woman. If pregnancy is achieved without ART and no underlying pathology is found, serous BOT should be considered and abdominal MR imaging could be performed to confirm the diagnosis.

examination revealed a fixed elastic ill-defined mass in the right neck with several enlarged lymphatic nodes. Lymphadenopathy was not found at any other locations. An ultrasound of the mass revealed a right internal jugular vein thrombosis. As a possible underlying cause, Lemierre's syndrome was considered, as well as ovarian hyperstimulation syndrome (OHSS) and pregnancy-related thrombophilia.^{7,8} Since an indwelling catheter was not present, this common cause of upper extremity thrombosis could be excluded.⁹ Our patient was referred to the otolaryngologist. No local pathology, such as a peritonsillar abscess, was found. Pregnancy was achieved naturally and no artificial reproductive techniques (ART) were used. Laboratory findings for thrombophilia were unremarkable. Furthermore, lupus anticoagulant tests and tests for antiphospholipid syndrome were normal.

Tinzaparine 0.9 ml once daily was started. MRI of the neck showed jugular vein thrombosis with infiltration of the surrounding fat and multiple small lymphatic nodules (figure 1). A fine needle biopsy was performed showing reactive lymphocytes and an otherwise non-classifiable atypical cell, but no specific diagnosis could be made. Because of foetal growth restriction, she was admitted for daily cardiotocography (CTG) monitoring. A caesarean section was performed 17 days after first presentation because of the foetal growth restriction. During the operation a tumour of the left ovary and Fallopian tube was seen. Biopsy was performed and pathological findings showed a serous borderline ovarian tumour (BOT) (figure 2). After three days of recovery our patient was discharged from hospital. After admission to the neonatal intensive care and subsequent paediatric ward, her baby could also be discharged and is developing well. Three months after the caesarean section a laparoscopic adnectomy was performed. The pathological findings confirmed the diagnosis of serous BOT and no further treatment was indicated.

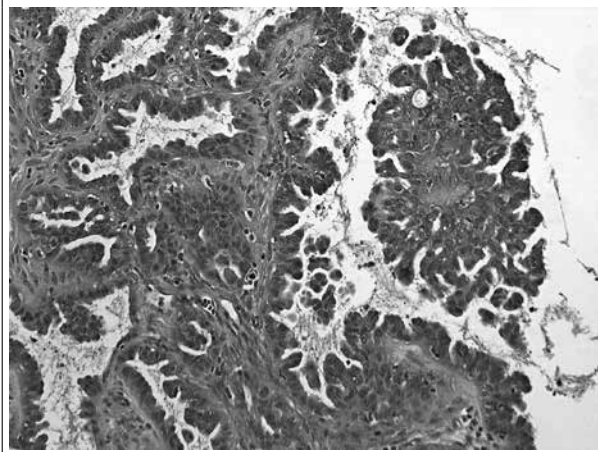
DISCUSSION

In this report we present a unique case of a pregnant woman with a jugular vein thrombosis which appeared to be the first symptom of a serous BOT. To our knowledge, this combination has never been described in literature

Figure 1. MRI showing jugular vein thrombosis with fat infiltration and multiple small lymphatic nodules

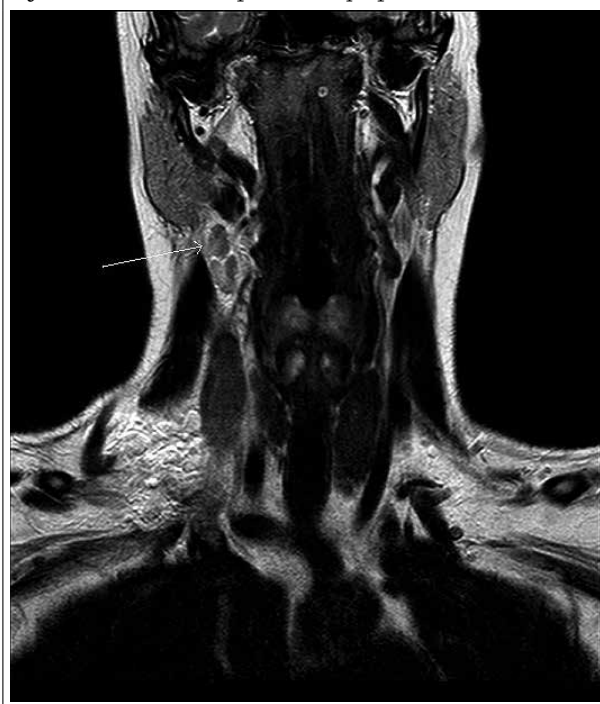

Figure 2. Biopsy of the left ovary showing serous borderline tumour of the ovary (H&E staining, 400x)



before. A literature search using the terms “jugular vein thrombosis or upper extremity thrombosis AND pregnancy” showed that jugular vein thrombosis during pregnancy is linked to either OHSS or Lemierre’s syndrome. In our patient, both were excluded shortly after initial presentation. Other causes of thrombosis such as the antiphospholipid syndrome or thrombophilia were also excluded. Thus, initially no explanation for this rare manifestation of thrombosis during pregnancy was found and the finding of a tumour mass of the left ovary during the caesarean section was essential for the diagnosis.

The relationship between serous BOT and upper extremity deep vein thrombosis has been described once before by Verbruggen *et al.* in 2006. They described three cases of non-pregnant women with cervical lymphadenopathy caused by lymph node localisation of a serous BOT.¹⁰ These so-called implants cause lymphadenopathy and subsequently blood vessel compression and thrombosis. Immunohistochemical staining of the lymphatic material and the ovarian tumour mass confirmed the association.

In our patient it was not possible to confirm this association on the available cytological material. A subsequent lymph node biopsy was not performed since removal of the BOT will result in regression of lymphadenopathy, as shown by Verbruggen. In 2002, Camatte *et al.* analysed the effect of lymphadenectomy due to implants on the overall survival in patients with serous BOT. No significant difference was found between BOT patients with and without lymph node implants. Therefore no lymphadenectomy was performed in our patient.¹¹

In our case, vaginal delivery would have obscured the primary tumour mass and the diagnosis could have been missed. To overcome this problem we recommend to perform an MRI of the abdomen in the case of unexplained jugular vein thrombosis in pregnancy. Based on the findings of the MRI further therapeutic options could be considered.¹² If MRI findings show an unusual mass an

explanation for the thrombosis is found. Next one should assess whether acute intervention is needed (malignancy is expected) or a wait-and-see policy can be followed (benignancy is expected). Because this situation is so unique each case should be evaluated separately.

We conclude that if jugular vein thrombosis in a pregnant woman is not explained by its usual causes a serous BOT should be considered and we suggest to perform abdominal MR imaging.

REFERENCES

1. Rodger M. Evidence base for the management of venous thromboembolism in pregnancy. *Hematology Am Soc Hematol Educ Program*. 2010;2010:173-80.
2. Chuniyal SD, Bates SM. Venous thromboembolism in pregnancy: diagnosis, management and prevention. *Thromb Haemost*. 2009;101:428-38.
3. Pomp ER, Lenselink AM, Rosendaal FR, Doggen CJ. Pregnancy, the postpartum period and prothrombotic defects: risk of venous thrombosis in the MEGA study. *J Thromb Haemost*. 2008 Apr;6:632-7.
4. James AH, Tapson VF, Goldhaber SZ. Thrombosis during pregnancy and the postpartum period. *Am J Obstet Gynecol*. 2005;193:216-9.
5. Ray JG, Chan WS. Deep Vein Thrombosis During Pregnancy and the Puerperium: A Meta-Analysis of the Period of Risk and the Leg of Presentation. *Obstet Gynecol Survey*. 1999;54:265-71.
6. Chan WS, Ginsberg JS. A review of upper extremity deep vein thrombosis in pregnancy: unmasking the 'ART' behind the clot. *J Thromb Haemost*. 2006;4:1673-7.
7. Salomon O, Kleinbaum Y, Heiman Z, Itzchak Y. Targeted ultrasound is the procedure of choice for detecting rudimentary branchial cysts causing jugular and subclavian vein thrombosis. *Blood Coag Fibrin*. 2010;21:726-8.
8. Bauersachs RM, Manolopoulos K, Hoppe I, Arins MJ, Schleussner E. More on: the 'ART' behind the clot: solving the mystery. *J Thromb Haemost*. 2007;5:438-9.
9. Joffe HV, Kucher N, Tapson VF, Goldhaber SZ. Upper-extremity deep vein thrombosis: a prospective registry of 592 patients. *Circulation*. 2004;110:1605-11.
10. Verbruggen MB. Serous borderline tumor of the ovary presenting with cervical lymph node involvement, a report of 3 cases. *Am J Surg Pathol*. 2006;30:739-43.
11. Camatte S, Morice P, Atallah D, et al. Lymph node disorders and prognostic value of nodal involvement in patients treated for a borderline ovarian tumor: an analysis of a series of 42 lymphadenectomies. *J Am Coll Surg*. 2002;195:332-8.
12. Aggarwal P, Kehoe S. Ovarian tumors in pregnancy: a literature review. *Eur J Obstet Gynecol Reprod Biol*. 2011;155:119-24.