

# Venous thromboembolism and prothrombotic parameters in Klippel-Trenaunay syndrome

C.E.U. Oduber<sup>1,2\*</sup>, E.J. van Beers<sup>3</sup>, P. Bresser<sup>4</sup>, C.M.A.M. van der Horst<sup>2</sup>, J.C.M. Meijers<sup>5,6</sup>, V.E.A. Gerdes<sup>5,7</sup>

<sup>1</sup>Department of Plastic, Reconstructive and Hand Surgery, Academic Medical Center, University of Amsterdam, Amsterdam, the Netherlands, <sup>2</sup>Department of Dermatology, Maastricht University Medical Centre, Maastricht, the Netherlands, <sup>3</sup>Department of Internal Medicine and Hematology, Academic Medical Center, University of Amsterdam, Amsterdam, the Netherlands, <sup>4</sup>Department of Respiratory Medicine, Academic Medical Center, University of Amsterdam and the Department of Respiratory Medicine, Onze Lieve Vrouwe Gasthuis, Amsterdam, the Netherlands, <sup>5</sup>Department of Vascular Medicine, Academic Medical Center, University of Amsterdam, Amsterdam, the Netherlands, <sup>6</sup>Department of Experimental Vascular Medicine, Academic Medical Center, University of Amsterdam, Amsterdam, the Netherlands, <sup>7</sup>Department of Internal Medicine, Slotervaart Hospital, Amsterdam, the Netherlands, \*corresponding author: tel.:+31 (0)43-3877292, fax: +31 (0)43-3877293, e-mail: ceoduber@gmail.com,

## ABSTRACT

**Background:** In Klippel-Trenaunay syndrome (KTS), a congenital combined vascular (capillary, venous and lymphatic) malformation with localised disturbed growth, venous thromboembolisms (VTEs) are frequently reported in small cohorts.

**Design and methods:** We quantified the frequency of VTE by screening a large KTS-patient cohort with duplex compression ultrasonography. Additionally, we performed a case-control study to evaluate whether coagulation alterations were related to VTE and magnitude of vascular malformations as quantified by magnetic resonance imaging (MRI).

**Results:** Twenty-nine (39%) of 75 patients had signs of current or previous VTE, including superficial venous thrombosis, six (8%) of whom had a deep venous thrombosis or a pulmonary embolism. Compared with 105 controls, 54 adult patients (both: median age 33 years) had higher plasma levels of D-dimer, medians 266 (IQR 195-366) versus 457 (IQR 270-3840)  $\mu\text{g/l}$  ( $p < 0.001$ ), respectively. They tended to have lower protein C ( $p = 0.10$ ) and free protein S ( $p = 0.07$ ) levels compared with controls. Compared with young-adult controls ( $n = 62$ ), KTS children ( $n = 21$ ) also had higher median D-dimer levels ( $p < 0.001$ ), and lower protein C ( $p = 0.003$ ) and protein S ( $p = 0.01$ ) levels. The extent of the vascular malformations on MRI was positively correlated with D-dimer plasma levels ( $r\text{-spearman} = 0.329$ ;  $p < 0.05$ ).

**Conclusions:** Otherwise healthy KTS patients had a very high rate of current or previous VTE. Very high D-dimer

levels were observed and these were related to the extent of the vascular malformation. Based on these findings we advise appropriate patient education on the signs and symptoms of thromboembolic complications in these patients, and screening for VTE in case of complaints.

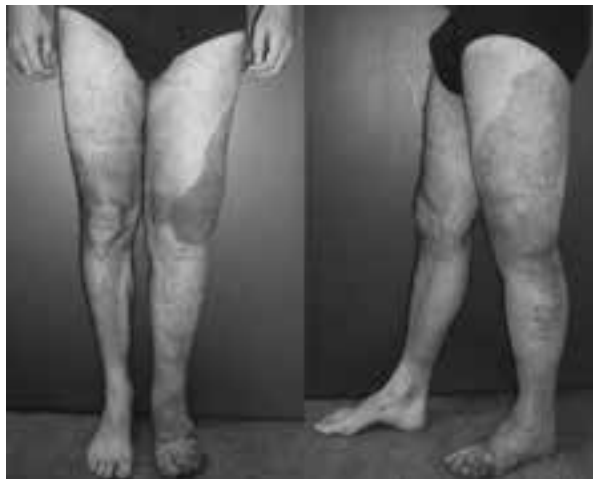## KEYWORDS

Venous thromboembolism, Klippel-Trenaunay syndrome, vascular malformation, duplex compression ultrasonography, deep venous thrombosis, D-dimer.

## INTRODUCTION

Klippel-Trenaunay syndrome (KTS) is a congenital malformation syndrome characterised by a combination of capillary, venous and lymphatic malformations with a localised disturbed growth of bone and/or soft tissue (*figure 1*).<sup>1</sup> Clinical presentation may vary from being asymptomatic to developing potentially life-threatening complications, such as deep vein thrombosis (DVT), pulmonary embolism (PE), and recurrent bleeding.<sup>2-5</sup> Although not investigated systematically, venous thromboembolism (VTE) has been reported to occur in 8-22% of KTS patients.<sup>2</sup> Despite the fact that over 30 case reports on KTS-associated pulmonary embolism have been published,<sup>2,3,5-17</sup> including alarming cases of belated

**Figure 1.** A patient with Klippel-Trenaunay syndrome affecting the left leg



Combined capillary, venous, and lymphatic malformation, with hypotrophy in the length and hypertrophy in the girth.

diagnosed recurrent pulmonary embolism or pulmonary hypertension,<sup>3,5,8-12</sup> the exact mechanism underlying the hypercoagulability in vascular malformations remains unclear. However, blood stagnation within the distorted, enlarged venous blood vessels may lead to coagulation activation,<sup>18</sup> though this has never been studied in a large KTS group.<sup>1</sup>

Therefore, the aims of the present study were to investigate the prevalence of present or previous thrombotic complications in KTS patients, to identify coagulation alterations compared with matched controls and to determine whether these changes were present at a young age.

## DESIGN AND METHODS

### Patients and procedures

All patients from a well-characterised Dutch cohort of KTS patients were asked to participate in the study and, if so, gave written informed consent. The patients were acquired from the Dutch KTS support group, and the multidisciplinary teams dedicated to vascular malformations in two Academic Medical Centres, between May 2006 and May 2007. Diagnosis of KTS was based on a combination of capillary, venous, and lymphatic malformations plus disturbed growth regulation, as previously described.<sup>19</sup> Results on the prevalence of chronic thromboembolic pulmonary hypertension in a subset of this group were published previously.<sup>20</sup> Plasma samples from two matched controls (on age, gender and use of oral contraceptives) were recruited from healthy volunteers in the AMC. Because the Medical Ethics Committee deemed it unethical to involve healthy children in this study, young

adults were used as controls for the paediatric patients. The protocol was approved by the Medical Ethics Committee of the AMC, and carried out in accordance with the principles of the Declaration of Helsinki.

### History taking, physical examination and duplex ultrasonography

Data regarding history of clinically manifest haemorrhages, and venous thromboembolism were collected. When deep venous thrombosis or pulmonary embolism was reported, we confirmed whether the diagnosis was established using an objective test (either compression ultrasonography, venography, ventilation perfusion scan or multi-slice CT). All patients were physically examined, looking for signs of haemorrhages or venous thromboembolism.

Flow characteristics, sub and clinically manifest superficial or deep venous thrombosis were obtained by duplex ultrasonography of the affected limb, performed by two experienced sonographers. With this procedure, the entire deep venous system was imaged from the groin or shoulder down to the distal system in the calf or arm. The only criterion accepted for a diagnosis of superficial or deep venous thrombosis was the finding of one or more non-compressible superficial or deep venous segments.

### Magnetic resonance imaging

Magnetic resonance imaging (MRI) studies were performed to delineate the extent of the vascular malformation in case of suspicion of multiple muscle and/or bone involvement, when disabling pain existed, before therapeutic intervention, or for other reasons. Because of the need for general anaesthesia, children ( $\leq 12$  years) were only investigated by MRI when therapeutic intervention was considered. We recorded the anatomic location of the vascular malformation, and the extent was categorised in groups of increasing severity. The least affected group of patients had slight evidence of vascular malformations on MRI scanning (muscle atrophy, alterations in fat tissue, varicose veins). The second group had only (sub) cutaneous vascular lesions. The third group had (sub) cutaneous lesions combined with lesions in another tissue compartment (muscle or osseous involvement). The patients with extensive (three or more affected muscles) disease or a combination of muscle and osseous involvement on MRI scans were included in the last group.

### Reagents and assays

Blood samples were collected into citrated tubes (Becton Dickinson, San Jose, CA), and centrifuged within 30 minutes for 20 minutes at 1700x g and 15°C, repeated for 15 minutes at 3000x g and 15°C. Plasma was stored at -80°C. Activated partial thromboplastin time (APTT) and prothrombin time were performed on a Behring

Coagulation System with reagents from the manufacturer (Siemens Healthcare Diagnostics). The fibrinogen concentration was derived from the change in optical signal during the prothrombin time determination. The plasma concentrations of prothrombin fragment 1+2 (F1+2) were measured by ELISA (Siemens Healthcare Diagnostics). D-dimer levels were determined by a quantitative ELISA method (Asserachrom® D-dimer, Diagnostica Stago, Asnières, France).

Plasmin-antiplasmin (PAP) complexes were determined with an ELISA from DRG (Marburg, Germany). The endogenous thrombin potential (ETP) was determined with a Calibrated Automated Thrombogram®. As this assay was employed to further explore the aetiology of the D-dimer elevation, it was only performed on the two subgroups of patients in the highest and lowest D-dimer tertile. The Calibrated Automated Thrombogram® assays the generation of thrombin in clotting plasma using a microtiter plate reading fluorometer (Fluoroskan Ascent, ThermoLab systems, Helsinki, Finland) and Thrombinoscope® software (Thrombinoscope BV, Maastricht, the Netherlands). The assay was carried out as described by Hemker *et al.*<sup>21</sup> and the Thrombinoscope manual. Coagulation was triggered by recalcification in the presence of 5 pM recombinant human tissue factor (Innovin®, Siemens Healthcare Diagnostics), 4 μM phospholipids, and 417 μM fluorogenic substrate Z-Gly-Gly-Arg-AMC (Bachem, Bubendorf, Switzerland). The endogenous thrombin potential (ETP) and related parameters were calculated using the Thrombinoscope software. Four parameters were derived from the thrombin generation curve: lag time, peak height, peak time and ETP (area under the curve).

### Statistical analysis

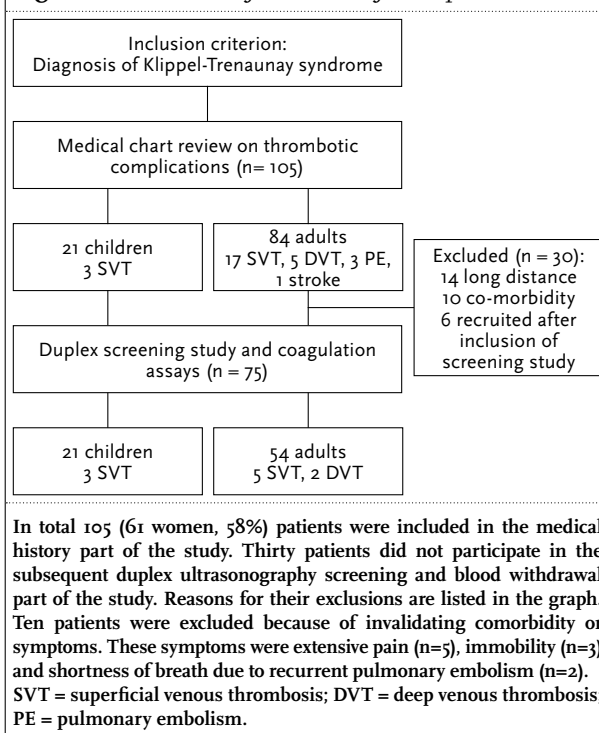
Statistical analysis was performed by using SPSS 16.0.2 (SPSS, UK). All numbers are medians with corresponding ranges, unless stated otherwise. The Mann-Whitney *U*-test was used for non-parametric numerical data. Differences between groups of categorical data were tested with the Chi-square ( $\chi^2$ ) test. To investigate whether high or low levels of coagulation parameters were more prevalent among KTS patients we calculated odds ratios (OR) for values above the 75th and 90th percentile of the control group, or 25th and 10th percentile of the control group, with their corresponding 95% confidence intervals (95% CI).

## RESULTS

### Patients

In total 105 (61 women, 58%) patients were eligible for inclusion, of which 30 patients did not participate. The reasons for exclusion are depicted in *figure 2*. The mean

**Figure 2.** Flowchart of inclusion of KTS patients



age of the non-participants was 30 years (range 5-68 years), 57% were female. Four of these patients had a history of venous thromboembolism (two had proven deep vein thrombosis, one had recurrent pulmonary embolism, and one had both), and another suffered from an ischemic stroke. Two patients, reported earlier,<sup>5</sup> died due to chronic thromboembolic pulmonary hypertension, and were therefore not amongst these 105 patients.

Data of 75 cases were available for the coagulation analyses. Characteristics of patients are listed in *table 1*. The cases were compared with 105 healthy adult controls: 63% women, with a median age of 33 (range 22-66) years.

### Venous thromboembolism: medical history and duplex ultrasonography

Medical history regarding proven venous thromboembolism revealed three patients (4%) with a previously documented deep venous thrombosis, one patient with a previous pulmonary embolism (1.3%) and 24 (32%) with previous superficial venous thrombosis. The pulmonary embolism was diagnosed in a patient who had just given birth to a child and imaging also showed a deep venous thrombosis.

A total of 70 patients underwent duplex ultrasonography. Of the five patients without ultrasonography, one was too young (<1 year), three refused and one had his affected leg amputated because of painful chronic infections. Thirty-five patients had venous anomalies: absent or hypoplastic deep venous system (n=6), hyperplastic deep

**Table 1.** Baseline clinical characteristics of all the patients

Characteristic	n=75
Age (years (range))	24 (1-77)
Female sex	44 (58.7)
Localisation	
- One upper limb	7 (9.3)
- One lower limb	51 (68)
- Both lower limbs	7 (9.3)
- All limbs, thorax and face	7 (9.3)
- Trunk	2 (2.7)
- Gluteus	1 (1.3)
Risk factors for venous thrombosis	
- Previous VTE	25 (33.3)
Superficial vein thrombosis	24 (32)
Deep vein thrombosis	3 (4)
Pulmonary embolism	1 (1.3)
- Immobilisation (walking aids)	1 (1.3)
- Recent surgery (<3 months)	0 (0)
- Oral contraceptives (women ≥18 only)	8 (17.6)
- Pregnancy	0 (0)
- Known cancer	0 (0)
Protective measures	
- Using anticoagulant medication	
Vitamin K antagonists	0 (0)
NSAIDs	7 (3.8)
Acetylic acid	4 (5.3)
- Use of therapeutic elastic stockings	42 (56)

Numbers are followed by the percentage of patients. NSAIDs, non-steroidal anti-inflammatory drugs.

venous system (n=2), double inferior caval vein (n=5), marginal lateral vein (n=12), abnormalities in great or small saphenous veins (n=16), and a double deep femoral artery (n=1).

Superficial venous thrombosis was observed in nine (12.7%) cases, while one case (1.4%) had evidence for a previously unknown superficial venous thrombosis. One patient appeared to have a current deep venous thrombosis and another patient showed an older previously unknown thrombosis in the common femoral vein, external iliac and common iliac vein.

When combining the results of duplex ultrasonography and medical history, 29 out of 75 patients with KTS (39%) had ever experienced a thromboembolic complication, six (8%) of whom had either a deep venous thrombosis or pulmonary embolism.

#### Coagulation parameters

The levels of D-dimer and PAP complexes in the adult KTS group were higher compared with those in the control group; very high D-dimer levels were observed in a number of patients (table 2). The D-dimer levels were also high in patients without signs of current superficial or deep venous thrombosis, median 407 (IQR 236-884). The odds ratio for a D-dimer value above the 75th percentile of the control group was 4.8 (95% CI 2.3-10.1) and above the 90th percentile 4.4 (95% CI 1.6-11.9). There was also a trend to lower median levels of the natural anticoagulants protein C (p=0.10) and free protein S (p=0.07) in cases compared with controls. There were significantly more cases with a protein C value below the 25th percentile of the control group (odds ratio 2.5, 95% CI 1.2-5.2), and below the 10th percentile (odds ratio 3.3, 95% CI 1.1-9.8). Comparing the children with KTS to young-adults we generally observed the same trend (table 2). The D-dimer levels were higher (p<0.001) and the median levels of protein C (p=0.003) and protein

**Table 2.** Results on markers of coagulation activation: adult cases versus adult controls and children with KTS versus young-adult controls

	Adult cases (n=54)	Adult controls (n=105)	P-value*	Child cases (n=21)	Young-adult controls (n=62)	P-value*
Age	33 (23-45)	33 (28-44)	0.32	9 (4-12)	28 (26-31)	<0.001
Sex (M:F)	20:34	39:66	0.99	11:10	26:36	0.41
Prothrombin time (sec)	12.5 (11.9-13.0)	12.4 (12.0-12.8)	0.76	12.6 (12.3-12.9)	12.5 (12.2-12.9)	0.55
Activated partial thromboplastin time (sec)	31.9 (29-34.6)	32.0 (30.1-35)	0.25	33.0 (31.4-35.6)	32.8 (30.1-35.5)	0.39
Markers of coagulation activation						
- Fibrinogen (g/l)	3.1 (2.3-3.7)	2.9 (2.4-3.4)	0.29	3.0 (2.7-3.4)	2.9 (2.4-3.3)	0.20
- Prothrombin fragment 1+2 (pmol/l)	203 (127-304)	209 (163-268)	0.76	166 (118-220)	184 (149-218)	0.38
- Von Willebrand factor (%)	97 (84-134)	100 (76-118)	0.41	87 (69-117)	97 (77-115)	0.48
- D-dimer (µg/l)	457 (270-3840)	266 (195-366)	<0.001	346 (298-771)	235 (168-338)	<0.001
- Plasmin-antiplasmin complexes (µg/l)	514 (373-758)	382 (300-476)	<0.001	405 (306-480)	384 (299-479)	0.70
Anticoagulant assays (% of normal)						
- Protein C	104 (90-123)	110 (99-130)	0.10	95 (84-107)	108 (96-124)	0.003
- Total Protein S	105 (91-122)	103 (93-123)	0.63	104 (95-118)	99 (88-118)	0.39
- Free Protein S	94 (83-105)	101 (87-111)	0.07	89 (78-96)	101 (84-110)	0.01
- Antithrombin	102 (96-108)	102 (96-108)	0.80	106 (99-110)	101 (96-107)	0.06

Numbers are medians (interquartile range). \*Mann-Whitney test or Chi-square-test when applicable.

S ( $p=0.01$ ) were lower in this group of young patients compared with young-adult controls.

#### Extent of malformations and D-dimer levels

Lesions of 40 KTS patients were examined by MRI. Of the 35 patients without an MRI scan, 20 did not have any symptoms, one had his leg amputated, 14 were too young and without a medical indication. Thirty-seven MRI scans could be evaluated. Three patients were in the least affected group on MRI. Ten patients had only (sub)cutaneous involvement on MRI. Ten patients had (sub)cutaneous involvement combined with another tissue compartment (muscles or osseous involvement). Fourteen patients had extensive disease with at least three affected muscles or a combination of muscle and osseous involvement on MRI. The median D-dimer levels in these four groups were 315  $\mu\text{g/l}$ , 364  $\mu\text{g/l}$ , 424  $\mu\text{g/l}$ , and 975  $\mu\text{g/l}$  respectively. The extent of the vascular malformations as quantified by MRI was significantly positively correlated with the D-dimer plasma levels ( $r\text{-spearman}=0.329$ ;  $p<0.05$ ).

#### High D-dimer versus low D-dimer

To further explore the striking high D-dimer results, we determined the endogenous thrombin potential. We divided KTS patients in tertiles according to plasma levels of D-dimer, and compared the highest with the lowest tertile (table 3).

PAP complexes were clearly higher in the highest tertile, while prothrombin fragment F1+2 and Von Willebrand factor were somewhat higher. Only subtle alterations in

components of the endogenous thrombin potential and in protein C levels were observed (table 3).

#### DISCUSSION

The primary aim of this study was to estimate the prevalence of venous thromboembolism in the Dutch KTS group. In total, 39% of the patients had ever experienced thromboembolic complications, including superficial thrombosis. Of all patients, 8% had either a deep venous thrombosis or a pulmonary embolism. This is extremely high compared with the incidence rate of 1.9 per 10,000 person-years in adults aged 30-34 years in the general population.<sup>22</sup> Furthermore, a considerable number of patients had clinically silent thrombosis detected by ultrasonography.

Our second aim was to identify coagulation alterations in patients with KTS compared with matched, healthy controls. We observed high, sometimes extremely high, D-dimer levels, higher PAP complexes and somewhat lower protein C levels among the adult patients compared with controls. Among the children with KTS also the free protein S was lower. The variables, fibrinogen, F1+2, Von Willebrand factor, antithrombin and total protein S, did not differ between patients and controls.

D-dimer, which is a reflection of fibrin degradation, has gained a prominent role in the diagnostic work-up of patients with suspected thromboembolism. The prothrombin fragment F1+2 directly reflects thrombin

**Table 3.** Endogenous thrombin potential and natural anticoagulants: cases in the highest D-dimer tertile versus lowest D-dimer tertile

	Highest (n=25)*	Lowest (n=25)	P- value**
D-dimer ( $\mu\text{g/l}$ )	4417 (1041-7916)	234 (210-273)	n.a.
Thrombin generation			
- ETP (nM.min)	1530 (1355-1708)	1527 (1358-1656)	0.070
- Lag time (min)	2.67 (2.33-2.95)	2.29 (2.04-2.67)	0.023
- Peak (nM)	276 (260-313)	315 (282-336)	0.016
- Peak time (min)	5.17 (4.85-5.62)	4.67 (4.22-5.33)	0.018
Anticoagulant activity assays (% of normal)			
- Protein C	100 (86-114)	104 (93-122)	0.022
- Free Protein S	94 (83-101)	85 (78-104)	0.91
- Antithrombin	101 (96-105)	106 (100-112)	0.013
Prothrombin time (sec)	12.8 (12.1-13.4)	12.3 (12-12.9)	0.24
Activated partial thromboplastin time (sec)	34.0 (31.2-35.3)	31.4 (29-33.5)	0.065
Markers of coagulation activation			
- Fibrinogen (g/l)	2.9 (2.2-3.5)	2.8 (2.5-3.4)	0.52
- Prothrombin fragment 1+2 (pmol/l)	277 (182-473)	168 (106-213)	0.001
- Von Willebrand factor (%)	105 (93-141)	84 (63-106)	0.006
- Plasmin-antiplasmin complexes ( $\mu\text{g/l}$ )	730 (438-1174)	397 (287-501)	<0.001

Numbers are medians (interquartile range). \*Cases were selected upon D-dimer level. In this table cases in the tertile with the highest plasma level of D-dimer are shown and compared to the healthy controls. \*\*Mann-Whitney test.

generation, since this fragment is generated during the conversion of prothrombin to thrombin. Consequently, F1+2 may be a more specific test for coagulation activation than D-dimer. However, large observational studies have shown that in clinical practice D-dimer is a much better predictor of thromboembolism in patients than other assays reflecting coagulation activation or fibrinolysis.<sup>23</sup> Based on the significant difference in D-dimer, PAP complexes, and protein C, our results indicate that patients with KTS have a prothrombotic state.

To further analyse the finding that a considerable amount of patients had very high D-dimer levels, we determined the capacity of their plasma to form thrombin with the so-called endogenous thrombin potential. We found only subtle alterations in components of the endogenous thrombin potential in the high D-dimer tertile. This is accompanied by a strong increase in PAP complexes and F1+2, lower protein C and a trend towards a higher APTT. This indicates that the observed changes in D-dimers and higher rate of thrombotic complications is probably not caused by an inherent increased potential to generate thrombin of patient plasma. In contrast, we suggest that the venous malformations cause disruption of blood flow thereby initiating continuous generation of thrombin with concomitant consumption of coagulation factors activation of the fibrinolytic system.<sup>24</sup> The minor increase of Von Willebrand in the highest D-dimer tertile indicates that endothelial cell activation is probably not the explanation for the high D-dimer levels.

Though the exact mechanism behind hypercoagulability in vascular malformations remains to be elucidated, blood stagnation or altered flow within the distorted, enlarged venous blood vessels may be responsible.<sup>18</sup> Insufficient calf function has been suggested as a cause, but foot volumetry in KTS compared with controls showed no significant decrease in calf function in KTS patients.<sup>2</sup> Another explanation for the higher incidence of deep venous thrombosis can be abnormalities in the venous vessel walls, although plethysmography was unable to demonstrate this.<sup>25</sup> A disturbed coagulation system has been proposed as explanation for venous thromboembolism in KTS.<sup>25</sup> Patients with other large venous malformations showed serological evidence of coagulopathy, defined by decreased fibrinogen levels, elevated D-dimer, and prolonged prothrombin times, with normal to moderately low platelet counts.<sup>26-28</sup> The results in these studies are in line with the increase in lag time, time to peak, low peak thrombin, low protein C, and strongly elevated D-dimer in our patients. The severity of the coagulopathy reported in other venous malformations seemed to be correlated with the extent of the malformation.<sup>26,28,29</sup> We also showed a correlation

between the extent of the malformation and the level of D-dimer. Mazoyer<sup>26,28</sup> proposed 'localised intravascular coagulation', or LIC, to be the cause of the coagulopathy in venous malformations. In our patients there are indications for some consumption of coagulation factors, but there is no clear consumptive coagulopathy.

This study has some limitations. First, ten patients did not participate in this study because they had high morbidity, e.g. extensive pain, recurrent pulmonary embolism, or were less ambulant because of great discrepancy in leg length and distal femur amputation due to KTS. Since most severe cases were not included, and two patients with known chronic thromboembolic pulmonary hypertension died before this study, we are certain that the incidence of deep vein thrombosis and pulmonary embolism presented in this study is not an overestimation of the prevalence of venous thromboembolism in this patient group.

Secondly, we were not allowed to recruit a matched control group for children younger than 18 years and had to compare them with young adults. However, the most important changes in plasma levels of proteins involved in coagulation cascade, i.e. D-dimer, protein C and free protein S, were not different between adults and children with KTS.

In conclusion, in this large cross-sectional cohort study of apparently healthy and young KTS patients, deep and superficial venous thrombosis is very common and a high proportion of these patients have high or extremely high D-dimer levels while there is only limited consumption of coagulation factors. Hence the presumed prothrombotic local effects in KTS are most likely down-regulated by a highly active fibrinolytic system.

Based on these findings we advise appropriate patient education on the signs and symptoms of thromboembolic complications in these patients. In case of symptoms, a low threshold for diagnostic testing for venous thromboembolism is necessary. Lifelong anticoagulation therapy should be considered in the case of a first deep venous thrombosis or pulmonary embolism, and venous thromboembolism prophylaxis should be directed to those KTS patients with hypercoagulability when they are exposed to one of the risk factors for venous thromboembolism, such as surgery, trauma or pregnancy.

## ACKNOWLEDGEMENTS

The authors would like to thank for the Academic Medical Centre, Amsterdam, the Netherlands: Wil Kopatz, Marian Weijne, Kamran Bakhtiari, Annelies Hoenderdos, Lucy

Leverink, Emilie Lijten, Esther Rust, and Marjolein Peters. From the ultrasonography department: Aart Terpstra, and Marja J.C. Pannekoek-Hekman and Maurice A.M. van Steensel for acquiring patients. We would like to thank all KTS patients for their enthusiastic participation.

## REFERENCES

1. Cohen MM, Jr. Klippel-Trenaunay syndrome. *Am J Med Genet.* 2000;93:171-5.
2. Baskerville PA, Ackroyd JS, Lea Thomas M, et al. The Klippel-Trenaunay syndrome: clinical, radiological and haemodynamic features and management. *Br J Surg.* 1985;72:232-6.
3. Jacob AG, Driscoll DJ, Shaughnessy WJ, et al. Klippel-Trenaunay syndrome: spectrum and management. *Mayo Clinic Proc.* 1998;73:28-36.
4. Samuel M, Spitz L. Klippel-Trenaunay syndrome: clinical features, complications and management in children. *Br J Surg.* 1995;82:757-61.
5. Oduber CE, Gerdes VE, van der Horst CM, et al. Vascular malformations as underlying cause of chronic thromboembolism and pulmonary hypertension. *J Plast Reconstr Aesthet Surg.* 2009;62:684-9; discussion 9.
6. Burbelko M, Kalinowski M, Wagner HJ. [Rare cause of chronic recurrent pulmonary emboli and pulmonary artery hypertension]. *Deutsche Medizinische Wochenschrift* (1946). 2006;131:811-4.
7. Karalezli A, Sevgili S, Ernam Turgut D, et al. Pulmonary embolism in a patient with Klippel-Trenaunay-Weber syndrome. *Tuberkulose ve Toraks.* 2006;54:281-7.
8. Mikula N, Jr., Gupta SM, Miller M, et al. Klippel-Trenaunay-Weber syndrome with recurrent pulmonary embolism. *Clin Nucl Med.* 1991;16:253-5.
9. Muluk SC, Ginns LC, Semigran MJ, et al. Klippel-Trenaunay syndrome with multiple pulmonary emboli--an unusual cause of progressive pulmonary dysfunction. *J Vasc Surg.* 1995;21:686-90.
10. Gianlupi A, Harper RW, Dwyre DM, et al. Recurrent pulmonary embolism associated with Klippel-Trenaunay-Weber syndrome. *Chest.* 1999;115:1199-201.
11. Huiras EE, Barnes CJ, Eichenfield LF, et al. Pulmonary thromboembolism associated with Klippel-Trenaunay syndrome. *Pediatrics.* 2005;116:e596-600.
12. Aggarwal K, Jain VK, Gupta S, et al. Klippel-Trenaunay syndrome with a life-threatening thromboembolic event. *J Dermatol.* 2003;30:236-40.
13. Fritzsche H, Hofer R, Joli I, et al. [Klippel-Trenaunay-Parkes-Weber syndrome with respiratory insufficiency due to thromboembolic vascular occlusion of the lung]. *Wiener Zeitschrift für innere Medizin und ihre Grenzgebiete.* 1972;53:368-73.
14. Awad AN, Yang DC, Girgis M, et al. Evaluation of Klippel-Trenaunay syndrome with radionuclide total body angiography. A case report. *Clin Nucl Med.* 1992;17:866-70.
15. Macleod AJ, Nichols DM, Franklin D. Pulmonary embolism in Klippel-Trenaunay syndrome of the upper limb. *J Royal Soc Med.* 1998;91:542-3.
16. D'Amico JA, Hoffman GC, Dymont PG. Klippel-Trenaunay syndrome associated with chronic disseminated intravascular coagulation and massive osteolysis. *Cleveland Clin Quart.* 1977;44:181-8.
17. Skourtis G, Lazoura O, Panoussis P, et al. Klippel-Trenaunay syndrome: an unusual cause of pulmonary embolism. *Int Angiol.* 2006;25:322-6.
18. Virchow R. Phlogose und Thrombose im Gefäßsystem. *Gesammelte Abhandlungen zur wissenschaftlichen Medizin.* Staatsdruckerei, Frankfurt; 1856:525.
19. Oduber CE, van der Horst CM, Hennekam RC. Klippel-Trenaunay syndrome: diagnostic criteria and hypothesis on etiology. *Ann Plast Surg.* 2008;60:217-23.
20. Douma RA, Oduber CE and Gerdes V, et al. Chronic pulmonary embolism in Klippel-Trenaunay syndrome. *J Am Acad Dermatol.* 2012;66:71-7
21. Hemker HC, Giesen P, Al Dieri R, et al. Calibrated automated thrombin generation measurement in clotting plasma. *Pathophysiol Haemost Thromb.* 2003;33:4-15.
22. Naess IA, Christiansen SC, Romundstad P, et al. Incidence and mortality of venous thrombosis: a population-based study. *J Thromb Haemost.* 2007;5:692-9.
23. Gibson NS, Sohne M, Gerdes VE, et al. Clinical usefulness of prothrombin fragment 1+2 in patients with suspected pulmonary embolism. *Thromb Res.* 2010;125:97-9.
24. Duchemin J, Pan-Petes B, Arnaud B, et al. Influence of coagulation factors and tissue factor concentration on the thrombin generation test in plasma. *Thromb Haemost.* 2008;99:767-73.
25. Baskerville PA. [Thromboembolic disease and congenital venous abnormalities]. *Phlebologie.* 1987;40:531-6.
26. Mazoyer E, Enjolras O, Laurian C, et al. Coagulation abnormalities associated with extensive venous malformations of the limbs: differentiation from Kasabach-Merritt syndrome. *Clin Lab Haematol.* 2002;24:243-51.
27. Enjolras O, Ciabrini D, Mazoyer E, et al. Extensive pure venous malformations in the upper or lower limb: a review of 27 cases. *J Am Acad Dermatol.* 1997;36:219-25.
28. Mazoyer E, Enjolras O, Bisdorff A, et al. Coagulation disorders in patients with venous malformation of the limbs and trunk: a case series of 118 patients. *Arch Dermatol.* 2008;144:861-7.
29. Domp Martin A, Acher A, Thibon P, et al. Association of localized intravascular coagulopathy with venous malformations. *Arch Dermatol.* 2008;144:873-7.