

# Bradykinin-receptor antagonist icatibant: possible treatment for ACE inhibitor-related angio-oedema

K. Manders<sup>1</sup>, M. van Deuren<sup>1</sup>, C. Hoedemaekers<sup>2</sup>, A. Simon<sup>1,3\*</sup>

<sup>1</sup>Department of General Internal Medicine, and N4i Centre for Immunodeficiency and Autoinflammation (NCIA), <sup>2</sup>Department of Intensive Care, Radboud University Nijmegen Medical Centre, Nijmegen, the Netherlands. <sup>3</sup>Department of General Internal Medicine, Radboud University Nijmegen Medical Centre Nijmegen, the Netherlands, \*corresponding author: a.simon@aig.umcn.nl

Dear Editor,

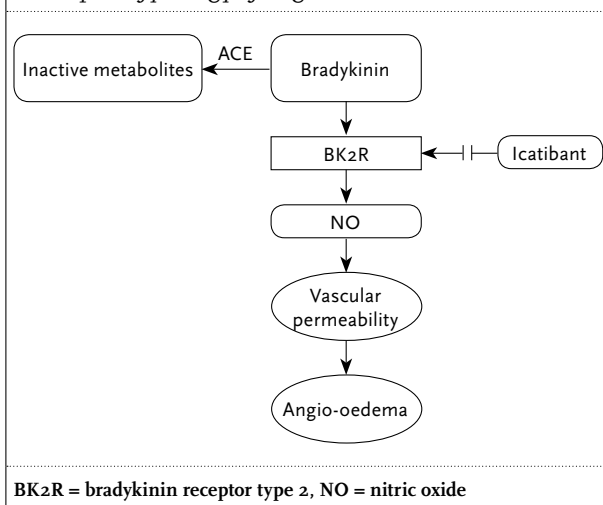
We would like to increase awareness of a new and potentially life-saving treatment option in angiotensin-converting enzyme (ACE) inhibitor-related angio-oedema. This condition can appear at any time during treatment with ACE inhibitors<sup>1</sup> and may present as life-threatening oropharyngeal oedema, which sometimes necessitates endotracheal intubation and observation in intensive care (ICU). As the angio-oedema is bradykinin and not histamine mediated (*figure 1*), the widely used treatment with prednisone and antihistamines is ineffective.<sup>1,2</sup> Therefore, the duration of oedema depends on the half-life time of the drug, among other things.

Recently icatibant, a bradykinin receptor type 2 antagonist, was introduced as treatment for C1-esterase inhibitor deficiency (hereditary angio-oedema), which is also bradykinin mediated.<sup>3,4</sup> Since then, a small number of case reports and case series on the effects of icatibant in ACE inhibitor-related angio-oedema have been published, showing rapid reduction of oedema and prevention of the need for intubation.<sup>5,7</sup> Based on these positive results, we recently treated a 45-year-old woman who presented to our emergency department with progressive swelling of the tongue for several hours with icatibant. Medication use consisted of chlorthalidone, metoprolol, methotrexate, omeprazole, simvastatin, and lisinopril, the dose of which was recently raised from 10 to 20 mg daily. Before presentation, she had already been repeatedly treated, without response, with adrenaline 0.5 mg intramuscularly (IM), DAF (Di-Adreson-F) 25 mg intravenously and clemastine 0.5 mg IM. After admission, subcutaneous icatibant 30 mg was administered. Within a few minutes, the swelling of the tongue decreased and she was able to speak and articulate more clearly. There was no need for intubation. The total duration of hospital stay was two days.

Another patient who recently presented to the emergency department with swollen tongue and gums while being treated with fosinopril (since 2009) was not treated with icatibant and had to be admitted to the ICU for endotracheal intubation for 24 hours with a total hospital stay of four days.

It is too early for definite conclusions about the efficacy of icatibant in ACE inhibitor-related angio-oedema, but two retrospective case series<sup>6,7</sup> show promising

**Figure 1.** Role of angiotensin converting enzyme (ACE) in the pathophysiology of angio-oedema



results. Our experience provides a further observation. In life-threatening cases of this complication it is worth considering using this bradykinin inhibitor. Nevertheless, prospective studies are needed, including cost-effectiveness (30 mg icatibant (1 dose) costs €1750 (Shire Netherlands, March 2012)). Larger studies should be performed in a multicentre setting, but will be complicated.

## REFERENCES

1. Agostoni A, Cicardi M, Cugno M, Zingale LC, Gioffre D, Nussberger J. Angioedema due to angiotensin-converting enzyme inhibitors. *Immunopharmacology*. 1999;44:21-5.
2. Nussberger J, Cugno M, Amstutz C, Cicardi M, Pellacani A, Agostoni A. Plasma bradykinin in angio-oedema. *Lancet*. 1998;351:1693-7.
3. Cugno M, Zanichelli A, Foini F, Caccia S, Cicardi M. C1-inhibitor deficiency and angioedema: molecular mechanisms and clinical progress. *Trends Mol Med*. 2009;15(2):69-78.
4. Landmesser U, Drexler H. Effect of angiotensin II type 1 receptor antagonism on endothelial function: role of bradykinin and nitric oxide. *J Hypertens Suppl*. 2006;24:S39-43.
5. Schmidt PW, Hirschl MM, Trautinger F. Treatment of angiotensin-converting enzyme inhibitor-related angioedema with the bradykinin B2 receptor antagonist icatibant. *J Am Acad Dermatol*. 2010;63:913-4.
6. Bas M, Greve J, Stelter K, et al. Therapeutic efficacy of icatibant in angioedema induced by angiotensin-converting enzyme inhibitors: a case series. *Ann Emerg Med*. 2010;56:278-82.
7. Gallitelli M, Alzetta M. Icatibant: a novel approach to the treatment of angioedema related to the use of angiotensin-converting enzyme inhibitors. *Am J Emerg Med*. 2011. Nov 17. [Epub ahead of print]