

Chronic hepatitis E after solid organ transplantation

A. de Niet¹, H.L. Zaaijer², I. ten Berge³, C.J. Weegink¹, H.W. Reesink¹, U. Beuers^{1*}

Departments of ¹Gastroenterology & Hepatology, ²Virology and ³Nephrology, Academic Medical Center, University of Amsterdam, Amsterdam, the Netherlands, *corresponding author: tel. +31 (0)20-5662422, fax: +31 (0)20-5669582, e-mail: u.h.beuers@amc.uva.nl

ABSTRACT

Large outbreaks of acute hepatitis E, caused by hepatitis E virus (HEV) genotypes 1 and 2, are known from developing countries with suboptimal sanitation infrastructure. An increasing incidence of HEV infections is being reported in industrialised countries, caused mainly by HEV genotypes 3 and 4, which are often found among pigs. Recent evidence suggests that in immunocompromised patients about 50% of the cases of acute hepatitis E evolve to chronic hepatitis with rapid progression to cirrhosis. Thus, HEV should be considered a cause of chronic hepatitis in immunocompromised patients, such as solid organ transplant recipients. Because an antibody response to HEV may be absent in these patients, an HEV RNA test should be carried out when serum liver tests are elevated over months. In small case series, ribavirin has been shown to represent a promising treatment option for chronic HEV infection. To increase the awareness for HEV infection in immunocompromised patients, a representative case report of an HEV-infected renal transplant recipient with chronic hepatitis E, successfully treated with ribavirin, is presented. Studies are required to determine the optimal duration of ribavirin therapy and to assess outcome for solid organ transplant recipients with chronic HEV infection.

KEYWORDS

Hepatitis E, transplantation, infection

INTRODUCTION

Hepatitis E virus (HEV) is a global pathogen that can cause epidemic, endemic, sporadic and zoonotic cases of acute hepatitis. Large outbreaks of hepatitis E are

seen in developing countries with suboptimal sanitation infrastructure. However, an increasing incidence of HEV infection is found in industrialised countries of the Western hemisphere. In the Netherlands, HEV infection is considered to be one of the three most important emerging infectious diseases: whereas less than 0.5% of the population had had contact with HEV 15 years ago, a recent survey showed that more than 15% of the population has meanwhile developed HEV antibodies as a sign of former exposure to HEV (see below). In the Western world, the course of endemic HEV infection is generally self-limiting and asymptomatic in immunocompetent individuals. In contrast, immunocompromised patients are at risk to develop chronic HEV infection with progressive liver disease as reported in various case series since 2008. Patients with haematological disorders,^{1,3} HIV infection^{4,5} and after solid organ transplantation under immunosuppressive therapy⁶⁻⁹ appear at particular risk to develop chronic hepatitis E that rapidly evolves to cirrhosis. Potentially effective therapeutic interventions by use of ribavirin in chronic hepatitis E have only recently been documented. To further raise the awareness of the community in the Western hemisphere for the risk of chronic hepatitis due to HEV infection in immunocompromised patients, but also to demonstrate the most recent development of promising therapeutic approaches, we report a case of a renal transplant patient with Bechterew's disease, who developed chronic hepatitis E, but was cured with ribavirin monotherapy.

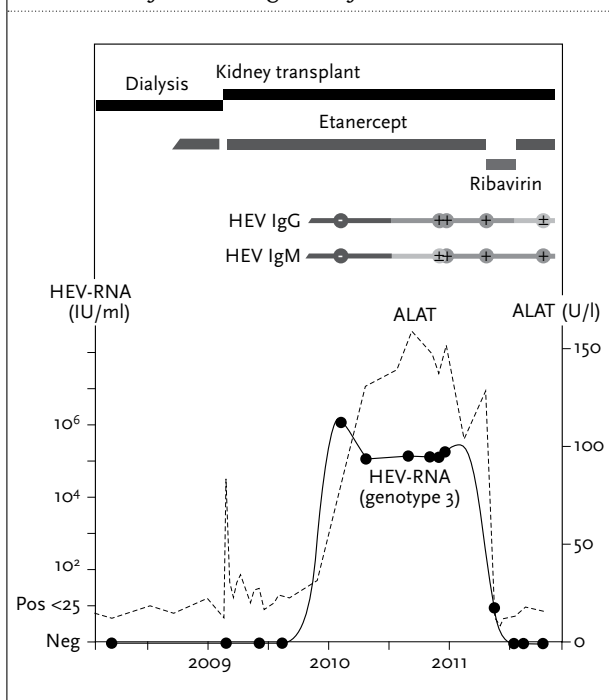
CASE REPORT

A 51-year-old bank manager was known with a medical history of arterial hypertension, hypertension-related

renal insufficiency, and Bechterew's disease. In July 2010 he received a living related kidney transplant. After transplantation, serum liver tests increased temporarily, but returned to normal levels within two weeks. His further postoperative course was uneventful. Before transplantation, serological tests for hepatitis A virus (HAV), hepatitis B virus (HBV), hepatitis C virus (HCV), cytomegalovirus (CMV), Epstein-Barr virus (EBV), and varicella zoster virus were all negative. The immunosuppressive regimen after kidney transplantation consisted of prednisolone 10 mg twice daily (bid), mycophenolate mofetil 1 g bid and tacrolimus 4 mg bid. For his Bechterew's disease, he received etanercept 25 mg twice weekly. One year after kidney transplantation alanine aminotransferase (ALAT [normal ≤ 45 U/l]: 132 U/l), aspartate aminotransferase (ASAT [≤ 40]: 65 U/l), and gamma-glutamyltransferase (γ GT [≤ 60]: 139 U/l) became elevated (figure 1). Prothrombin time and total bilirubin remained within the normal range. Ultrasound of the liver did not show any abnormalities. Serological and molecular testing, respectively, for HAV, HBV, HCV, and

CMV remained negative. Unexpectedly, serological tests for hepatitis E were positive (HEV IgM positive, HEV IgG weakly positive). Retrospective testing of former specimens revealed positive HEV RNA (genotype 3) in serum one year after transplantation onwards, coinciding with the rising serum liver tests. The patient (95 kg, 198 cm) was treated with ribavirin at a dose of 800 mg bid for three months. Maintenance immunosuppressive drug treatment was diminished (prednisolone 5 mg bid, mycophenolate mofetil 1500 mg bid and tacrolimus 500 mg bid) and etanercept was temporarily discontinued, but had to be restarted because of severe symptoms of Bechterew's disease. At the start of ribavirin therapy, creatinine clearance was >60 ml/min, haemoglobin was 7.2 mmol/l, and HEV RNA in serum was strongly positive (figure 1). No deterioration of kidney function or haemoglobin count was observed during treatment. Two months after the start of ribavirin therapy, all serum liver tests had returned to normal and HEV RNA was negative. Three and six months after the end of the ribavirin treatment, the serum liver tests remained normal and serum HEV RNA remained negative. The patient is doing well.

Figure 1. A 51-year-old patient with arterial hypertension-associated renal insufficiency and Bechterew's disease developed chronic hepatitis E one year after living-related kidney transplantation and was treated with ribavirin monotherapy for three months. His immunosuppressive medication, HEV RNA, and serum ALAT (normal ≤ 40 U/l) are documented between 2009 and early 2012. Immunosuppressive drug therapy with prednisolone, mycophenolate mofetil and tacrolimus was diminished after the diagnosis of HEV



BACKGROUND

Biology and epidemiology

HEV is a *hepevirus*,¹⁰ consisting of a capsid containing a positive-stranded RNA genome, and it is not enveloped. Phylogenetic studies have unravelled four genotypes. HEV genotype 1 and 2 infections are restricted to humans whereas genotypes 3 and 4 appear to be zoonotic, infecting various animal species such as pigs, wild boar and deer as well as humans.

Epidemiological studies revealed that genotypic distribution of HEV is area specific. Genotypes 1 and 2 are prevalent in the highly disease-endemic regions, which cover the tropical and subtropical parts of Asia, Africa and Central America.^{11,12} HEV genotype 1 and 2 infections are most commonly transmitted through faecally contaminated water via the oral route. Materno-foetal and transfusion-related transmissions have only occasionally been reported.^{13,14} Various endemic outbreaks of hepatitis E genotype 1 and 2 have been documented. Young adults are most often infected. Pregnant women are at particular risk: they have a higher disease attack rate and are much more likely to develop fulminant liver failure with fatal outcome in up to 22% (all genotype 1 infections).¹⁵ The pathophysiological mechanisms leading to fulminant liver failure after HEV infection in pregnant women are not understood, but have been attributed to pregnancy-related immunological or hormonal alterations.^{16,17}

In regions with lower HEV infection rates, such as Western Europe, the United States, and developed countries of

Asia and the Pacific region, hepatitis E was long thought to be related to travel to endemic regions. This view has recently changed since an increasing number of sporadic, autochthonous HEV infections have been reported, particularly in Western Europe. Viral strains isolated from HEV-infected patients without a history of travel to high-risk areas were classified as genotype 3 and 4. This strongly suggests a zoonotic origin. First, human HEV isolates genotype 3 and 4 appear to be the same strains that also frequently infect pigs. Secondly, interspecies transmission from human to pig and from swine to nonhuman primates has been demonstrated.^{18,19} Thirdly, molecular typing in Japan demonstrated a link between cases of hepatitis E after eating raw or undercooked pig meat and HEV strains isolated from domestic swine, wild boar and sika deer.^{20,21}

In contrast to predominant infection of young adults in the endemic areas in Asia and Africa, in Western Europe and the US mostly elderly subjects and people with coexisting illness are affected, while fulminant disease in pregnant women is not reported.¹¹ It is assumed that HEV genotype 3 is less virulent than the genotype 1 and 2 strains, which may explain the predilection of elderly and immunocompromised persons for HEV genotype 3 infection. In addition, this may explain why epidemic outbreaks with genotype 3 have not been observed so far in the Western world. Subclinical infection with HEV genotype 3 may explain the relatively high seroprevalence of anti-HEV antibodies in these areas.²² The geographical distribution of genotype 4 is limited to Asian countries and has not been associated with disease in immunocompromised patients so far.

Seroprevalence in Europe

A study in 1995 among Dutch blood donors reported a seroprevalence of 0.4%.²³ Seroprevalence in the South-West of France (according to testing of blood donors) has meanwhile dramatically increased from 16.6 to 52.5%, suggesting that the disease is highly endemic in this region.²⁴ In the UK, HEV RNA was detected in six out of 880 pools of blood donations (with 48 donations per pool), indicating a considerable rate of silent ongoing HEV infections among British blood donors.²⁵ The incidence of *de novo* HEV infections after kidney transplantation was calculated as 3.2 cases/100 person-years in a recent analysis.²² Accordingly, seroprevalence studies had previously reported anti-HEV IgG antibodies in 6 to 16% of renal transplant recipients.²⁶

CLINICAL MANIFESTATIONS

Clinical features of HEV infection differ between the hyperendemic and the low prevalence areas. Incubation

time is approximately 30 days. In hyperendemic areas the most commonly observed clinical presentation is a typical acute icteric hepatitis resembling hepatitis A and other forms of acute viral hepatitis. A pre-icteric and an icteric phase of the illness can be distinguished. The initial pre-icteric phase is characterised by fever, anorexia, distaste for food, vomiting, abdominal pain and diarrhoea. These symptoms last for about three days. The onset of the icteric phase is marked by disappearance of the prodromal symptoms. It is usually self-limiting and improves within 10 to 24 days. Hepatomegaly and splenomegaly are common during the icteric phase.^{11,27} Less frequently, liver injury is mild and can be asymptomatic or accompanied by only non-specific symptoms. Acute hepatic decompensation may be particularly seen in persons with pre-existing liver disease or with genotype 1 infections during pregnancy.

In low prevalence areas, patients with symptomatic hepatitis E genotype 3 typically are older, predominantly male with higher frequency of underlying liver disease, alcohol abuse, or an immunocompromised state. The clinical presentation is often non-specific, the spectrum ranges from asymptomatic elevation of serum transaminases to a severe icteric hepatitis. In clinical case series, jaundice was the most common symptom (68-86%) followed by asthenia, fever, joint and muscle pains and abdominal discomfort.^{11,27} Extrahepatic clinical manifestations such as pancreatitis, haematological manifestations, autoimmune and neurological disorders have infrequently been reported.¹¹

CHRONIC HEPATITIS E

Chronic hepatitis E, genotype 3, in low-endemic regions was first described in immunocompromised patients in 2008. Various case series reported chronic hepatitis E in patients who developed elevation of serum transaminases after kidney, liver and heart transplantation.^{9,26,28-30} Chronic HEV infection was also reported in patients with haematological malignancies, human immunodeficiency virus infection or those receiving anticancer chemotherapy.^{11,5,31} Symptoms in these patients are mild or unnoticed and elevation of serum transaminases may be the only sign during routine follow-up. Rapid progression of chronic hepatitis E to cirrhosis is observed in these patients. Furthermore, extrahepatic manifestations such as HEV-induced glomerulonephritis, which recovered after HEV clearance, have been observed after organ transplantation.³²

All recently described cases of chronic hepatitis E in low prevalence areas were caused by HEV genotype 3. The way of transmission of HEV genotype 3 has been a matter of intense discussion since. Apart from zoonotic infection,

other modes of transmission have been suggested in immunocompromised organ transplant recipients. Transmission of the virus from the donor organ has been reported in a liver transplant recipient who subsequently developed cirrhosis and hepatic decompensation.³³ Transmission via blood transfusions was unravelled in a number of haemodialysis patients.³⁴⁻³⁶ Although reactivation of the virus has not been observed after solid organ transplantation, as is seen in other chronic viral infections such as hepatitis B during immunosuppression, reactivation of HEV was discussed in one patient with allogenic stem cell transplantation.²

DIAGNOSIS

The diagnosis of HEV infection is based on detection of HEV IgG and IgM antibodies in blood and of HEV RNA in blood and stool. Both HEV IgM and IgG ELISA based assays are available, but have not been standardised so far. Sensitivity and specificity may vary considerably between different assays and even between batches of a given assay. HEV IgM antibodies are detectable as soon as symptoms occur. IgG antibodies may reach a sensitivity of 72% to 98% and a specificity of 78% to 96% to diagnose HEV infection in immunocompetent patients,³⁷ but are less accurate in immunocompromised individuals. HEV IgG may persist for years.

Molecular detection of HEV RNA can be achieved by PCR from serum, bile and stool. Nucleic acid testing as a diagnostic marker of HEV infection has limitations in immunocompetent patients, because the period of viral shedding is limited to only one to two weeks around the time of ALAT elevation and jaundice.¹¹ Still, HEV PCR is a crucial tool in immunocompromised patients. In these patients, the diagnosis can be easily missed as they often remain seronegative, whereas HEV RNA remains detectable during chronic infection. Furthermore, diagnostic testing for hepatitis E in transplant patients may be delayed as increased levels of serum liver tests (ALAT, ASAT) are frequently seen as a consequence of drug toxicity or are related to other hepatotropic viral infections. Histological findings in liver biopsies may vary from portal hepatitis with dense lymphocytic infiltrates, piecemeal necrosis and fibrosis to cases with severe fibrosis or cirrhosis and are not specific for hepatitis E.

TREATMENT OF CHRONIC HEPATITIS E

Acute hepatitis E is self-limiting and usually does not need any treatment. In contrast, up to 60% of immunocompromised patients⁶ develop chronic hepatitis after HEV infection (HEV RNA persistently positive, >6 months

in serum or stool) without treatment. Decreasing the number and dose of immunosuppressive drugs can be the first approach to control chronic hepatitis E in (renal) transplant recipients.³⁸ Most recently, advances have been made by the use of peg-interferon and ribavirin in chronic hepatitis E.

Peg-interferon therapy of chronic hepatitis E in transplant patients

Three case series have reported successful results with three to 12 months of peg-interferon therapy in six liver transplant recipients and in one patient on haemodialysis after kidney transplantation. Sustained viral response (SVR), defined as negative serum HEV RNA six months after cessation of therapy, was reported in five of the seven patients. In the first report, 12 months of peg-interferon therapy resulted in sustained response in two of three liver transplant recipients chronically infected with hepatitis E.³⁹ Similar results were obtained with a three-month course of peg-interferon therapy in two of three patients with HEV infection who also underwent liver transplantation.⁴⁰ In the third report three months of peg-interferon therapy also led to SVR in a patient with kidney transplant failure and haemodialysis who did not spontaneously clear HEV after withdrawal of immunosuppressive therapy.^{41,42} Of note, as the use of peg-interferon therapy could enhance allogenic immunity, it has to be given with caution in transplant patients and should be avoided in kidney transplant patients because of a high risk of acute organ rejection in these patients.⁴³

Ribavirin therapy of chronic hepatitis E in transplant recipients

Three case series have reported promising results with three months of ribavirin therapy in patients with kidney, pancreas and heart transplantation. Sustained viral response was reported in 78% of the reported cases. In the largest series, ribavirin therapy in kidney transplant recipients led to an SVR six months after cessation of therapy in four out of six patients.²⁸ The second report documented SVR in two patients with chronic hepatitis E after kidney and pancreas transplant, respectively, following three months of ribavirin therapy.⁴⁴ A third case report showed SVR after ribavirin therapy in a patient with chronic hepatitis E after heart transplantation.³⁰ The major adverse effect of ribavirin is haemolytic anaemia, which usually occurs within the first two weeks of treatment and may be reversible after dose reduction. Close monitoring of haemoglobin levels is therefore advised. Nevertheless, the otherwise good tolerability of ribavirin monotherapy makes this medication an attractive option for treatment of chronic hepatitis E after solid organ transplantation. The case reported by us above confirms this conclusion.

Therapy in patients with HIV or haematological malignancies

SVR after a combined regimen of peg-interferon and ribavirin for chronic HEV infection was reported in a case of co-infection with HIV-1 and HEV.⁴⁵ Successful treatment of chronic hepatitis E by three-month ribavirin treatment was reported for three cases with haematological malignancies.^{3,41,46} Although the afore-mentioned results are promising, only small case series are available and larger trials with longer follow-up are necessary.

PREVENTIVE STRATEGIES

In endemic areas the main measures to prevent hepatitis E are better public education regarding hygiene and provision of safe drinking water.^{11,47} In areas of zoonotic transmission, proper cooking of pig and deer meat is advised. However, it is questionable whether direct contact with HEV-positive pork meat explains the current rise in infections with endemic hepatitis E in the Western world. Other food products may also be involved, for example fruit and vegetables may be contaminated via the use of HEV-positive water.⁴⁸

Two HEV recombinant protein vaccines have been successfully developed against proteins from the highly conserved open reading frame 2 of the virus.^{49,50} The vaccines showed 96 and 100% efficacy, respectively, but they are not yet commercially available.

CONCLUSION

Hepatitis E virus (HEV) (human genotype 1 and 2) is a global pathogen that is responsible for large outbreaks of hepatitis E in developing countries. HEV (genotype 3) has been found to cause occasional autochthonous infections, also in low endemic, developed areas in Europe or the United States. In immunocompromised patients, HEV can cause chronic hepatitis with rapid progression to cirrhosis. Because the anti-HEV antibody response can be absent or delayed in immunocompromised patients, an HEV RNA test should be carried out when serum liver tests are elevated. Recent advances have been made with peg-IFN and ribavirin treatment for chronic hepatitis E. Considering the side effects of peg-IFN and its potential to induce allogenic immunity, ribavirin treatment should be the first choice for chronic hepatitis E in transplant patients. Adequate follow-up is necessary to assess the long-term outcome for immunocompromised patients with chronic HEV infection. Hepatitis E vaccines, currently under investigation, may be beneficial for patients infected with HEV genotype 1 or 2 in the near future.

ACKNOWLEDGEMENTS

We thank K.A.M.I. van Donselaar-van der Pant and F.J. Bemelman for their clinical assistance.

REFERENCES

1. Peron JM, Mansuy JM, Recher C, et al. Prolonged hepatitis E in an immunocompromised patient. *J Gastroenterol Hepatol.* 2006;21:1223-4.
2. le Coutre P, Meisel H, Hofmann J, et al. Reactivation of hepatitis E infection in a patient with acute lymphoblastic leukaemia after allogeneic stem cell transplantation. *Gut.* 2009;58:699-702.
3. Ollier L, Tieulie N, Sanderson F, et al. Chronic hepatitis after hepatitis E virus infection in a patient with non-Hodgkin lymphoma taking rituximab. *Ann Intern Med.* 2009;150:430-1.
4. Colson P, Kaba M, Moreau J, Brouqui P. Hepatitis E in an HIV-infected patient. *J Clin Virol.* 2009;45:269-71.
5. Dalton HR, Bendall RP, Keane FE, Tedder RS, Ijaz S. Persistent carriage of hepatitis E virus in patients with HIV infection. *N Engl J Med.* 2009;361:1025-7.
6. Kamar N, Selves J, Mansuy JM, et al. Hepatitis E virus and chronic hepatitis in organ-transplant recipients. *N Engl J Med.* 2008;358:811-7.
7. Gerolami R, Moal V, Picard C, Colson P. Hepatitis E virus as an emerging cause of chronic liver disease in organ transplant recipients. *J Hepatol.* 2009;50:622-4.
8. Haagsma EB, van den Berg AP, Porte RJ, et al. Chronic hepatitis E virus infection in liver transplant recipients. *Liver Transpl.* 2008;14:547-53.
9. Legrand-Abravanel F, Kamar N, et al. Characteristics of autochthonous hepatitis E virus infection in solid-organ transplant recipients in France. *J Infect Dis.* 2010;202:835-44.
10. Meng XJ. Hepatitis E virus (*hepevirus*). Mahy BWJ, van Regenmortel MHV (Eds.), *Encyclopedia of Virology* (3rd edition), vol. 5 Elsevier, Oxford (2008), pp. 377-83 ed. 2008.
11. Aggarwal R, Jameel S. Hepatitis E. *Hepatology.* 2011;54:2218-26.
12. Purcell RH, Emerson SU. Hepatitis E: an emerging awareness of an old disease. *J Hepatol.* 2008;48:494-503.
13. Khuroo MS, Kamili S, Jameel S. Vertical transmission of hepatitis E virus. *Lancet.* 1995;345:1025-6.
14. Khuroo MS, Kamili S, Yatoo GN. Hepatitis E virus infection may be transmitted through blood transfusions in an endemic area. *J Gastroenterol Hepatol.* 2004;19:778-84.
15. Bhatia V, Singhal A, Panda SK, Acharya SK. A 20-year single-center experience with acute liver failure during pregnancy: is the prognosis really worse? *Hepatology.* 2008;48:1577-85.
16. Pal R, Aggarwal R, Naik SR, Das V, Das S, Naik S. Immunological alterations in pregnant women with acute hepatitis E. *J Gastroenterol Hepatol.* 2005;20:1094-101.
17. Navaneethan U, Al MM, Shata MT. Hepatitis E and pregnancy: understanding the pathogenesis. *Liver Int.* 2008;28:1190-9.
18. Meng XJ, Halbur PG, Shapiro MS, et al. Genetic and experimental evidence for cross-species infection by swine hepatitis E virus. *J Virol.* 1998;72:9714-21.
19. Erker JC, Desai SM, Schlauder GG, Dawson GJ, Mushahwar IK. A hepatitis E virus variant from the United States: molecular characterization and transmission in cynomolgus macaques. *J Gen Virol.* 1999;80(Pt 3):681-90.
20. Rutjes SA, Lodder-Verschoor F, Lodder WJ, et al. Seroprevalence and molecular detection of hepatitis E virus in wild boar and red deer in The Netherlands. *J Virol Methods.* 2010;168:197-206.
21. Purcell RH, Emerson SU. Hidden danger: the raw facts about hepatitis E virus. *J Infect Dis.* 2010;202:819-21.

22. Mansuy JM, Legrand-Abravanel F, Calot JP, et al. High prevalence of anti-hepatitis E virus antibodies in blood donors from South West France. *J Med Virol.* 2008;80:289-93.
23. Zaaier HL, Mauser-Bunschoten EP, ten Veen JH, et al. Hepatitis E virus antibodies among patients with hemophilia, blood donors, and hepatitis patients. *J Med Virol.* 1995;46:244-6.
24. Mansuy JM, Bendall R, Legrand-Abravanel F, et al. Hepatitis E virus antibodies in blood donors, France. *Emerg Infect Dis.* 2011;17:2309-12.
25. Ijaz S, Szypulska R, Tettmar KI, Kitchen A, Tedder RS. Detection of hepatitis E virus RNA in plasma mini-pools from blood donors in England. *Vox Sang.* 2012;102:272.
26. Kamar N, Selves J, Mansuy JM, et al. Hepatitis E virus and chronic hepatitis in organ-transplant recipients. *N Engl J Med.* 2008;358:811-7.
27. Aggarwal R. Clinical presentation of hepatitis E. *Virus Res.* 2011;161:15-22.
28. Kamar N, Rostaing L, Abravanel F, et al. Ribavirin therapy inhibits viral replication on patients with chronic hepatitis E virus infection. *Gastroenterology.* 2010;139:1612-8.
29. Verhoeven Y, Bac DJ, Feith GW. [Liver cirrhosis due to hepatitis E in a kidney transplant patient]. *Ned Tijdschr Geneesk.* 2010;154:A1790.
30. Chaillon A, Sirinelli A, De Muret A, Nicand E, d'Alteroche L, Goudeau A. Sustained virologic response with ribavirin in chronic hepatitis E virus infection in heart transplantation. *J Heart Lung Transplant.* 2011;30:841-3.
31. Tamura A, Shimizu YK, Tanaka T, et al. Persistent infection of hepatitis E virus transmitted by blood transfusion in a patient with T-cell lymphoma. *Hepatol Res.* 2007;37:113-20.
32. Kamar N, Weclawiak H, Guilbeau-Frugier C, et al. Hepatitis e virus and the kidney in solid-organ transplant patients. *Transplantation.* 2012;93:617-23.
33. Schlosser B, Stein A, Neuhaus R, et al. Liver transplant from a donor with occult HEV infection induced chronic hepatitis and cirrhosis in the recipient. *J Hepatol.* 2012;56:500-2.
34. Boxall E, Herborn A, Kochethu G, Pratt G, Adams D, Ijaz S, Teo CG. Transfusion-transmitted hepatitis E in a 'nonhyperendemic' country. *Transfus Med.* 2006;16:79-83.
35. Colson P, Coze C, Gallian P, Henry M, De Micco P, Tamalet C. Transfusion-associated hepatitis E, France. *Emerg Infect Dis.* 2007;13:648-9.
36. Mansuy JM, Huynh A, Abravanel F, Recher C, Peron JM, Izopet J. Molecular evidence of patient-to-patient transmission of hepatitis E virus in a hematology ward. *Clin Infect Dis.* 2009;48:373-4.
37. Khudyakov Y, Kamili S. Serological diagnostics of hepatitis E virus infection. *Virus Res.* 2011;161:84-92.
38. Kamar N, Abravanel F, Selves J, et al. Influence of immunosuppressive therapy on the natural history of genotype 3 hepatitis-E virus infection after organ transplantation. *Transplantation.* 2010;89:353-60.
39. Haagsma EB, Riezebos-Brilman A, van den Berg AP, Porte RJ, Niesters HG. Treatment of chronic hepatitis E in liver transplant recipients with pegylated interferon alpha-2b. *Liver Transpl.* 2010;16:474-7.
40. Kamar N, Rostaing L, Abravanel F, et al. Pegylated interferon-alpha for treating chronic hepatitis E virus infection after liver transplantation. *Clin Infect Dis.* 2010;50:e30-e33.
41. Alric L, Bonnet D, Laurent G, Kamar N, Izopet J. Chronic hepatitis E virus infection: successful virologic response to pegylated interferon-alpha therapy. *Ann Intern Med.* 2010;153:135-6.
42. Kamar N, Abravanel F, Garrouste C, et al. Three-month pegylated interferon-alpha-2a therapy for chronic hepatitis E virus infection in a haemodialysis patient. *Nephrol Dial Transplant.* 2010;25:2792-5.
43. Rostaing L, Izopet J, Baron E, Duffaut M, Puel J, Durand D. Treatment of chronic hepatitis C with recombinant interferon alpha in kidney transplant recipients. *Transplantation.* 1995;59:1426-31.
44. Mallet V, Nicand E, Sultanik P, et al. Brief communication: case reports of ribavirin treatment for chronic hepatitis E. *Ann Intern Med.* 2010;153:85-9.
45. Dalton HR, Keane FE, Bendall R, Mathew J, Ijaz S. Treatment of chronic hepatitis E in a patient with HIV infection. *Ann Intern Med.* 2011;155:479-80.
46. Alric L, Bonnet D, Beynes-Rauzy O, Izopet J, Kamar N. Definitive clearance of a chronic hepatitis E virus infection with ribavirin treatment. *Am J Gastroenterol.* 2011;106:1562-3.
47. Mushahwar IK. Hepatitis E virus: molecular virology, clinical features, diagnosis, transmission, epidemiology, and prevention. *J Med Virol.* 2008;80:646-58.
48. Brassard J, Gagne MJ, Genereux M, Cote C. Detection of Human Foodborne and Zoonotic Viruses on Irrigated, Field-Grown Strawberries. *Appl Environ Microbiol.* 2012;78:3763-6.
49. Shrestha MP, Scott RM, Joshi DM, et al. Safety and efficacy of a recombinant hepatitis E vaccine. *N Engl J Med.* 2007;356:895-903.
50. Zhu FC, Zhang J, Zhang XF, et al. Efficacy and safety of a recombinant hepatitis E vaccine in healthy adults: a large-scale, randomised, double-blind placebo-controlled, phase 3 trial. *Lancet.* 2010;376:895-902.