

Recalcitrant leg ulcer due to mixed connective tissue disease

A.P. Rozin^{1*}, Y. Braun-Moscovici¹, R. Bergman², A. Balbir-Gurman¹

Departments of ¹Rheumatology and ²Dermatology, Rambam Medical Centre and Technion, Haifa, Israel, *corresponding author: tel.: 972-4-854 22 68, fax: 972-4-85429 85, e-mail: a_rozin@rambam.health.gov.il

ABSTRACT

We present a 28-year-old woman with mixed connective tissue disease (MCTD) complicated by a recalcitrant longstanding leg ulcer, which responded to complex therapy with local polydine, systemic ciprofloxacin, iloprost, enoxaparin and aspirin. Cyclophosphamide pulse therapy and corticosteroids controlled the systemic inflammation but failed to heal the leg ulcer. We considered a rationale of complex therapy for the leg ulcer on a basis of pathogenesis and complications of MCTD.

KEYWORDS

Ciprofloxacin, enoxaparin, iloprost, mixed connective tissue disease, recalcitrant leg ulcer

INTRODUCTION

Mixed connective tissue disease (MCTD) is an overlap syndrome combining features of systemic lupus erythromatosus, rheumatoid arthritis, systemic sclerosis and polymyositis, together with the presence of antibodies to U1-RNP.¹ Analysis by immunoblotting showed that the major epitopes recognised by MCTD sera are a 68kDa polypeptide bound to U1 (uridine-rich)-RNA. Skin manifestations of MCTD include Raynaud's phenomenon associated with oedema of the hands, sclerodactyly, calcinosis, telangiectasia, photosensitivity, malar rash and the rash of dermatomyositis. Chronic leg ulcers are not rare in MCTD or overlap syndromes. We describe a patient with MCTD who developed a chronic refractory leg ulcer, which responded to complex therapy.

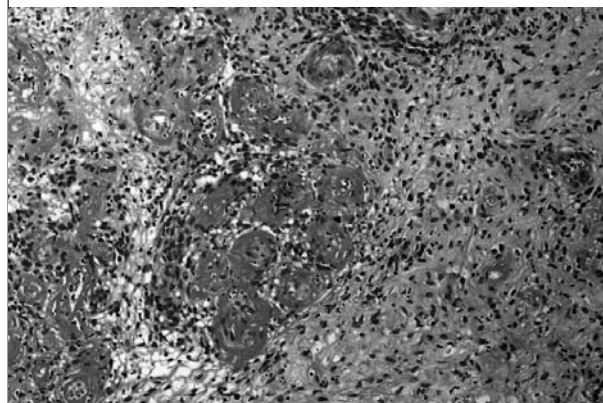
CASE REPORT

A 28-year-old woman developed fever, symmetric painful swelling of the hands, Raynaud's syndrome, telangiectasia, livedo reticularis, polyarthritis and oesophageal dysmotility in 1998. Heart, lungs and kidneys were intact. At that time she was leucopenic (3600/mm³), anaemic (haemoglobin 9.7 g/dl) with a positive Coombs test and an elevated erythrocyte sedimentation rate (80/h). Immunological analysis showed a high titre of speckle pattern antinuclear factor, positive anti-DNA and anticardiolipin antibodies, negative lupus anticoagulant, positive SS-A/Ro antigen, negative SS-B/La antigen, Smith antigen, antitopoisomerase, anticentromere antibodies, borderline low C3-C4, high serum level of rheumatoid factor (1000 IU/ml) and ribonucleoprotein at haemagglutination titre of 1:1600, and polyclonal hypergammaglobulinaemia. Tests for antineutrophil cytoplasmic antibodies, and cryoglobulins were negative. Hepatitis-B surface antigen and hepatitis-C virus were negative. Bone marrow showed nonspecific reactive changes. Gastrointestinal endoscopy, total body CT and bone scan were normal. Coagulation testing showed no mutations of prothrombin, methyltetrahydrofolate reductase, and Leiden V factor. Antithrombin III, protein C and S activity, protein C resistance, prothrombin time, international normalised ratio and partial thromboplastin time were normal. An increased level of fibrinogen (488 mg/dl, normal 160 to 400), borderline low thrombin time and a high level of factor VIII (256%, normal 55 to 150) with elevated D-dimers (2.17 mg/l, normal <0.5) were found. Echocardiography was normal except for borderline pulmonary artery pressure (30 mmHg). The clinical and laboratory findings were consistent with mixed connective tissue disease (Alarcon-Segovia and Villanreal criteria). Initially she responded to corticosteroid, hydroxychloroquine and methotrexate therapy. Two years later, the methotrexate was stopped

because of recurrent episodes of fever, and respiratory and urinary tract infections. She needed moderate to high doses of prednisone (20 to 40 mg/day) to control the fever, polyarthritis and neutropenia. In 2001 the patient developed a small skin ulcer on the right ankle. The ulcer extended despite multiple local therapies: chlorhexidine gluconate 0.5% irrigation, topical antibiotic and steroid ointments, hydrocolloid gel and dressing, calcium-sodium alginate fibres and Becaplermin gel 0.01%. Ultrasound Doppler of the leg vessels and ankle-brachial index were normal. Repeated marginal biopsies did not show vasculitis, pyoderma gangrenosum, or malignancy, but only nonspecific inflammation. Her general condition was still poor with sustained fever and active polyarthritis. The dose of prednisone was raised to 40 mg/day; the fever and synovitis resolved but she developed vertebral osteoporotic fractures. Azathioprine was added to the hydroxychloroquine and corticosteroid therapy. Four months later she developed sepsis with multiple abscesses of the abdomen and respiratory failure due to massive pneumonia resulting from severe leucopenia ($1800/\text{mm}^3$); the azathioprine treatment was stopped. The patient was critically ill, and needed long-term intensive therapy. She was treated with respiratory support, intravenous antibiotics, abscess incisions, intravenous immunoglobulins and parenteral corticosteroids. The infectious complications were cured, but her leg ulcer continued to expand and achieved 3.5 cm in diameter (figure 1). Episodes of fever, arthritis and cytopenia recurred requiring treatment with moderate doses of steroids. In the interim another marginal biopsy showed leucocytoclastic vasculitis and intimal small-vessel proliferation with thrombi (figure 2). At this point cyclophosphamide monthly pulse infusions (1 g) were started. Cyclophosphamide therapy reduced disease activity; the fever, haemoglobin and white blood cell count returned to normal, the arthritis remitted and the prednisone dose was reduced to 5 mg/day. However, the leg ulcer remained unchanged (figure 1). We decided to begin complex inpatient therapy. This therapy (known as the acronym AAVAA) included:

- 1) Antiseptic therapy consisting of local povidone iodine soap cleanser (0.75% iodine) for leg baths twice a day, each procedure lasting 30 minutes, with further iodine 1% dressing until complete wound healing.

Figure 2. A biopsy obtained from the ulcer edge of the patient with MCTD



In the deep dermis there are extensive fibrin deposits in the small blood vessel walls with intimal proliferation along with neutrophils and fibrin thrombi, which plug the blood vessels' lumina. (Haematoxylin-eosin X 400).

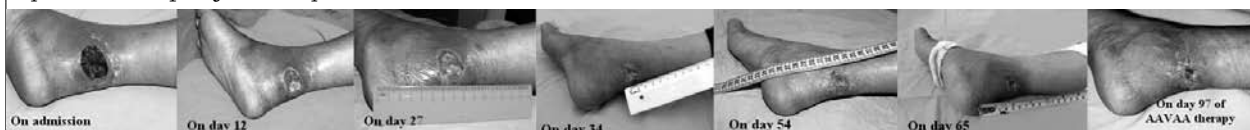- 2) Antibiotic treatment with intravenous amoxycillin+clavulenic acid according to ulcer flora susceptibility followed by oral ciprofloxacin 500 mg twice daily until complete wound healing.
- 3) Vasodilatory/vasomodulatory therapy with long-term infusion of the prostacyclin analogue ilomedin (iloprost thromethamine) (Agis) for seven weeks.
- 4) Anticoagulant therapy with low-molecular-weight heparin enoxaparin: clexane (Aventis Pharma) 40 mg/day subcutaneous for two months.
- 5) Antiaggregant therapy with aspirin 100 mg/day.

AAVAA therapy brought about complete healing of the ulcer leg (figure 1) after three months, which had been refractory to therapies for three years. The characteristic dynamics of wound contraction were followed (figure 3). No systemic, local or scar complications were observed during and after AAVAA therapy.

DISCUSSION

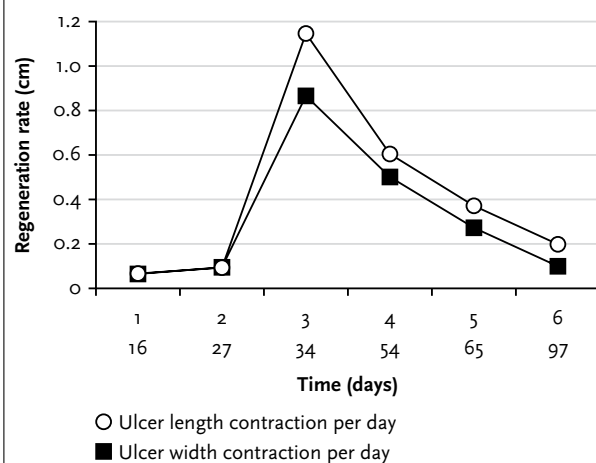
Vascular, infectious and tumour-associated causes, pyoderma gangrenosum and pressure sores must be

Figure 1. Large leg ulcer (3.5 x 2.5 cm) associated with MCTD that had been refractory to multiple local and systemic therapies for three years



Complex antiseptic, antibiotic, vasodilatory, anticoagulant and antiaggregant (AAVAA) therapy was administered and achieved complete relief of the inflammation and ulcer healing in three months.

Figure 3. Three periods of ulcer healing during AAVAA therapy



The first one (27 days) was of very slow regeneration and associated with treatment of the affecting factors interfering with normal regeneration: infection, inflammation, vascular damage and thrombosis. The second period (27-54 days) was associated with rapid wound regeneration with a peak on the 34th day, which was followed by the third period (54-97 days) of slower healing due to the phenomenon of contact cell inhibition. Regeneration rate = contraction of the wound length/day and the wound width/day.

considered in patients with cutaneous ulceration and autoimmune disease. Ulcerations secondary to ischaemia may result from vasospasm (Raynaud's phenomenon), vascular thrombosis (antiphospholipid syndrome or paraproteinaemia) and vascular necrosis (necrotising venulitis or arteritis). Besides malignancy with typical morphology and histology all the above-mentioned influences might be involved in the aetiology of the leg ulcer in our patient.

The image of MCTD as a benign rheumatic disease with a favourable response to therapy is currently under revision. Serious vascular disease with thrombotic complications, pulmonary hypertension and heart failure are common and result in significant morbidity and mortality.² We observed a rare form of severe vascular disease due to MCTD complicated by a recalcitrant leg ulcer, which only responded to complex therapy. The rationale for this complex therapy for the leg ulcer was as follows.

The need to treat local infection with effective local and systemic antibiotic long-term therapy according to microbial susceptibility up to complete wound healing, Wound infection might be responsible for the unhealed ulcer and be an origin for microbial dissemination through this 'open gate'.

Microvascular impairments of MCTD with intimal proliferation, medial hypertrophy, affecting small and medium-sized vessels with occlusion³ and hypercoagulation abnormalities (D-dimers, high factor VIII, elevated

fibrinogen, anticardiolipin antibodies) found in our patient justified therapy with anticoagulant enoxaparin, aspirin and iloprost. An angiographic study reported a high prevalence of medium-sized vessel occlusions in patients with MCTD.⁴ The anticoagulant therapy has been reported to be beneficial in MCTD associated with arterial thrombosis,⁵ pulmonary hypertension,⁶ Budd-Chiari syndrome⁷ and acute right cardiac failure due to pulmonary thromboembolism.⁸ For the first time we report effective anticoagulant (enoxaparin), aspirin and iloprost therapy for MCTD complicated by a recalcitrant leg ulcer. A number of double-blind placebo-controlled studies of iloprost infusion given intravenously have shown benefit in Raynaud's syndrome.^{9,10} In addition to its vasodilatory and antiplatelet effects, iloprost has been shown to downregulate lymphocyte adhesion to the endothelium.¹¹ When compared with nifedipine, it was found to have the same effect on reducing the frequency of the vasospastic attacks, but was more effective in healing digital ulcers and appeared to produce fewer adverse effects. Iloprost is the first choice for patients with critical ischaemia or ulceration. It can produce benefit lasting for between six weeks and six months in most patients.

The necessary prerequisite of successful treatment was immunosuppressive therapy for vasculitis with cyclophosphamide pulses, corticosteroids and hydroxychloroquine; however, although this therapy controlled the systemic disease, it did not result in wound healing. Besides its antibiotic properties, ciprofloxacin was reported as an activator of interleukin-3 production, granulocyte-macrophage colony-stimulating factor and haemopoiesis,¹²⁻¹⁵ which are important for wound healing, and as inhibitor of antiphospholipid antibodies.¹⁶ A high dose of ciprofloxacin has been reported to inhibit tumour necrosis factor- α production, lymphocyte blast transformation and synthesis of immunoglobulins.^{17,18} By understanding the mechanisms that act to delay healing, chronic wound healing becomes a true science rather than a clinical art.¹⁹

REFERENCES

1. Mukerji B, Hardin JB. Undifferentiated, overlapping and mixed connective tissue diseases. *Am J Med Sci* 1993;305:114-9.
2. Burdt MA, Hoffman RW, Deutscher SL, et al. Long-term outcome in mixed connective tissue disease: longitudinal clinical and serologic findings. *Arthritis Rheum* 1999;42:899-909.
3. Singsen BH, Swanson VL, Bernstein BH, et al. A histologic evaluation of mixed connective tissue disease in childhood. *Am J Med* 1980;68:710.
4. Peller JS, Gabor GT, Porter JM, Bennett RM. Angiographic findings in mixed connective tissue disease. Correlation with fingernail capillary photomicroscopy and digital pletismography findings. *Arthritis Rheum* 28;768:1985.
5. Jackson J, McDonald M, Casey E, et al. Mixed connective tissue disease with arterial thrombosis, antiphospholipid antibodies and heparin induced thrombocytopenia. *J Rheumatol* 1990;17:1523-4.

6. Hainaut P, Lavenne E, Magy JM, Lebacqz EG. Circulating lupus type anticoagulant and pulmonary hypertension associated with mixed connective tissue disease. *Clin Rheumatol* 1986;5:96-101.
7. Cosnes J, Robert A, Levy VG, Darnis F. Budd-Chiari syndrome in a patient with mixed connective-tissue disease. *Dig Dis Sci* 1980;25:467-9.
8. Ueda Y, Yamauchi Y, Makizumi K, et al. Successful treatment of acute right cardiac failure due to pulmonary thromboembolism in mixed connective tissue disease. *Jpn J Med* 1991;30:568-72.
9. Rademaker M, Thomas RHM, Provost G, et al. Prolonged increase in digital blood flow following iloprost infusion in patients with systemic sclerosis. *Postgrad Med J* 1987;63:617-20.
10. Wigley FM, Wise RA, Seibold JR, et al. Intravenous iloprost infusion in patients with Raynaud phenomenon secondary to systemic sclerosis. *Ann Intern Med* 1994;120:199-206.
11. Della Bella S, Molteni M, Mocellin C, et al. Novel mode of action of iloprost: in vitro down-regulation of endothelial cell adhesion molecules. *Prostaglandins Other Lipid Mediat* 2001;65:73-83.
12. Shalit I. Immunological aspects of new quinolones. *Eur J Clin Microbiol Infect Dis* 1991;10:262-6.
13. Kletter Y, Riklis I, Shalit I, et al. Enhanced repopulation of murine hematopoietic organs in sublethally irradiated mice after treatment with ciprofloxacin. *Blood* 1991;75:1685-91.
14. Riesbeck K, Sigvardson M, Leanderson T, et al. Superinduction of cytokine gene transcription by ciprofloxacin. *J Immunol* 1994;153:343-51.
15. Kletter Y, Singer A, Nagle A, et al. Ciprofloxacin enhances hematopoiesis and peritoneal neutrophil function in lethally irradiated, bone marrow-transplanted mice. *Exp Hematol* 1994;22:360-5.
16. Blank M, George J, Fishman P, et al. Ciprofloxacin immunomodulation of experimental antiphospholipid syndrome associated with elevation of interleukin-3 and granulocyte-macrophage colony-stimulating factor expression. *Arthritis Rheum* 1998;41:224-32.
17. Riesbeck K, Forsgren A. Selective enhancement of synthesis of IL-2 in lymphocytes in the presence of ciprofloxacin. *Eur J Clin Microbiol Infect Dis* 1990;9:409-17.
18. Jimenez-Valera M, Sampedro A, Moreno E, et al. Modification of immune response in mice by ciprofloxacin. *Antimicrob Agents Chemother* 1995;39:150-4.
19. Clark M, Price PE. Is wound healing a true science or a clinical art? *Lancet* 2004;364:1388-9.