

Rituximab in the treatment of relapsing idiopathic thrombocytopenic purpura

N.P. Riksen*, J.J. Keuning, G. Vreugdenhil

Department of Haematology, Maxima Medical Centre, PO Box 7777, 5500 MB Veldhoven, the Netherlands, * corresponding author: Department of Pharmacology-Toxicology, University Medical Centre St Radboud, PO Box 9101, 6500 HB Nijmegen, the Netherlands, tel.: +31 (0)24-361 36 91, fax: +31 (0)24-361 42 14, e-mail: N.Riksen@aig.umcn.nl

ABSTRACT

About 25 to 30% of patients with idiopathic thrombocytopenic purpura (ITP) are resistant to standard treatment with steroids and splenectomy. In these patients with chronic refractory ITP, there is no proven algorithm for standard care. Recently, the chimeric anti-CD20 monoclonal antibody rituximab was considered as an alternative treatment option in this patient group. We present a patient with frequently relapsing ITP after treatment with prednisone, splenectomy and high-dose dexamethasone. Since he experienced increasing side effects due to the steroids, he was treated with rituximab 375 mg/m², once weekly for four weeks, resulting in a complete long-lasting response (follow-up seven months).

INTRODUCTION

Idiopathic thrombocytopenic purpura (ITP, also known as immune thrombocytopenic purpura) is an acquired disorder, characterised by low platelet counts and mucocutaneous bleeding. The pathogenesis is presumed to be related to platelet-specific autoantibodies which, after binding to platelet antigens, cause accelerated clearance of platelets by the mononuclear phagocyte system.¹ The diagnosis of ITP remains one of exclusion of other causes of thrombocytopenia. Treatment of ITP is aimed at prevention of serious bleeding complications. Glucocorticoid treatment is the initial treatment of choice in patients with platelet counts less than 30 × 10⁹/l.² The incidence of continuous remission ranges from 5 to over 30%.¹ In patients who fail to achieve a safe platelet count on prednisone, splenectomy

is considered to be the next treatment. A significant number of patients fail to respond to splenectomy or suffer a relapse. The percentage of patients with this chronic refractory ITP ranges from 8 to 30-40%.^{1,3} For these patients, there is no proven algorithm for standard care.⁴ The advice of the American Society of Haematology is to refrain from therapy with platelet counts over 30 × 10⁹/l and without bleeding symptoms because of the very small risk of bleeding complications in these patients.³ In patients with platelet counts less than 30 × 10⁹/l treatment options include removal of an accessory spleen, high-dose dexamethasone, cyclophosphamide, azathioprine, vinca alkaloids and danazol. All these agents have, at best, response rates in the range of 40 to 50%, but sustained-remission rates are usually well below 20%,⁵ with frequent and often serious side effects.

Recently, the chimeric monoclonal anti-CD20 antibody rituximab (Mabthera®), which depletes B lymphocytes, was studied as an alternative treatment option in patients with chronic refractory or chronic relapsing ITP.⁵⁻¹² In this case report, we describe a patient with chronic relapsing ITP who showed a complete remission on treatment with rituximab.

CASE REPORT

In 1994 a 50-year-old man was referred to our clinic with petechiae and easy bruising. His medical history revealed coxarthrosis since 1992. He had no other signs of haemorrhagic diathesis, such as epistaxis, haematuria or gastrointestinal blood loss. There were no systemic signs,

such as fever or weight loss. He had no history of recent infection and was not taking any medication. Physical examination revealed an obese, vital man with multiple, nonpalpable purpura on the arms and legs. Liver and spleen were not palpable, nor were there any palpable lymph nodes. He had a thrombocytopenia of $12 \times 10^9/l$ with otherwise normal blood counts, a normal peripheral blood smear and bone marrow examination. Antiplatelet antibodies were detected by direct immunofluorescence testing. The diagnosis of ITP was made and he was treated initially with prednisone (1 mg/kg), which was tapered and stopped after six weeks. He showed a rapid increase in platelet count to around $100 \times 10^9/l$, lasting ten months. He also developed diabetes mellitus for which treatment with glibenclamide was started. Then platelet counts decreased to $12 \times 10^9/l$ and pulsed high-dose dexamethasone (40 mg daily for four days every month, for a period of four months) was initiated resulting in a complete response (CR) for 1.5 years (figure 1). In 1998 splenectomy was performed because of frequent relapses, resulting in a rapid response lasting for only three months. The presence of an accessory spleen was ruled out by CT and radionuclear scanning. The following period was characterised by multiple relapses of severe, but otherwise asymptomatic thrombocytopenia, with persistent good responses on pulsed high-dose dexamethasone. However, during this period of treatment, he suffered from weight gain, insomnia and deterioration of his diabetes mellitus. In 2001 the frequency of relapses increased. In August 2002 treatment was initiated with rituximab ($375 \text{ mg}/\text{m}^2$ once weekly for four weeks).

After the second antibody infusion, there was a rapid normalisation of the platelet count with a CR (platelet count around $200 \times 10^9/l$) up to present (figure 1). He did not experience any side effects. One month after the start of rituximab treatment, antiplatelet antibodies were still present.

DISCUSSION

We report here successful treatment of a 50-year-old male patient suffering from ITP with the B lymphocyte-depleting monoclonal antibody rituximab.

A significant number of patients with ITP do not respond to treatment with glucocorticoids and splenectomy. These chronic refractory patients with platelet counts less than $30 \times 10^9/l$ are shown to have a significantly increased morbidity and mortality due to bleeding^{3,13} and side effects of treatment.³ In this patient group it is very important to consider both the risk of bleeding and the risk of therapy-related complications, which can be severe, especially concerning long-term immunosuppression.¹⁴ Most bleeding complications occur with platelet counts $<10 \times 10^9/l$, so in this situation treatment is recommended.^{2,4,14} For platelet counts between 10 and $30 \times 10^9/l$, the decision regarding optimal treatment, or refraining from treatment, should be based on an individual estimation of the bleeding risk, based on factors such as bleeding signs, lifestyle and age.¹⁴ If treatment is deemed necessary, many treatment options exist, but often with disappointing results and considerable side effects.

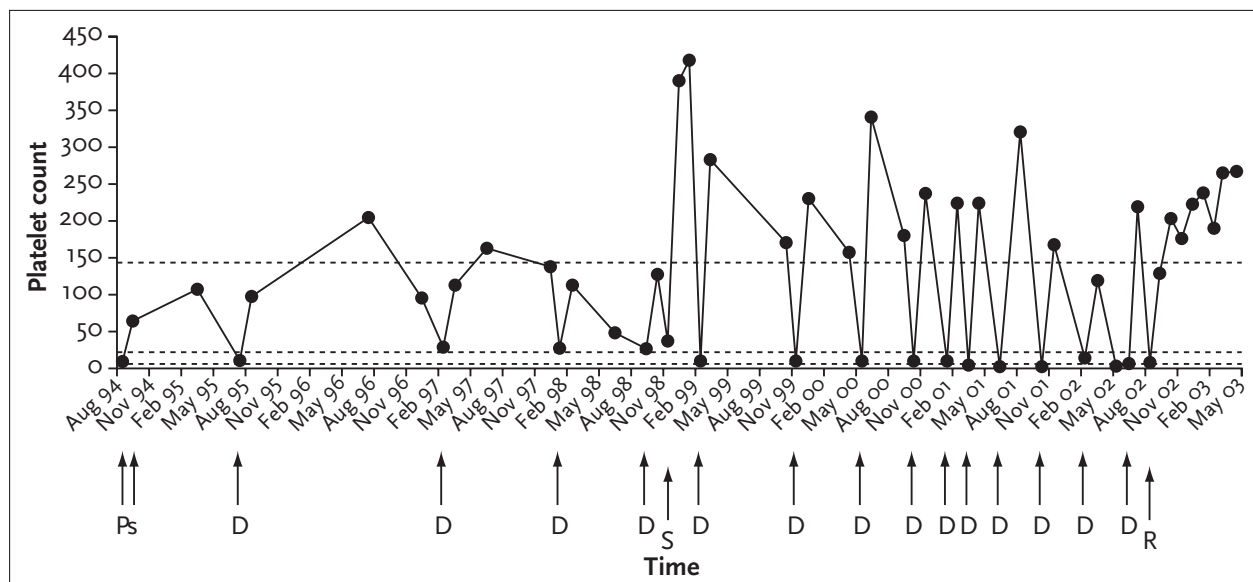


Figure 1

Schematic representation of the platelet count in the period from August 1994 until April 2003 (since August 2002 the patient is in complete remission)

P = prednisone 1 mg/kg, s = stop prednisone, D = high-dose dexamethasone, S = splenectomy, R = rituximab. Dotted horizontal lines indicate platelet counts of 10, 30 and $150 \times 10^9/l$.

Recently, the anti-CD20 monoclonal antibody rituximab was proposed as alternative treatment option in this patient group. Rituximab was originally used in the treatment of relapsed, low-grade B cell non-Hodgkin's lymphoma (NHL), where it showed good responses.¹⁵ The good responses and mild toxicity recently led to the use of rituximab in ITP, with the aim of B-cell depletion and interfering with the production of autoantibodies. Stasi *et al.* administered rituximab to 25 patients with ITP previously resistant to at least two lines of treatment, with platelet counts less than $20 \times 10^9/l$ or with significant bleeding. Overall response rate was 52% with five patients achieving a complete remission (CR), five a partial remission (PR) and three a minor response, with response duration ranging from 2 to 108+ weeks.⁵ Recently, they added seven more patients, with four CRs and two PRs.¹¹ Giagounidis *et al.*⁸ used rituximab in 12 patients with platelet counts less than $20 \times 10^9/l$ and unsuccessful corticosteroid treatment and splenectomy. Overall response rate was 75% with 41% CRs and 17% PRs. In CR patients, response duration varied from 68 to 455+ days.⁸ Perotta *et al.* treated ten patients with chronic ITP and recorded 5 CRs, with a response duration from 1 to 14+ months.⁹ Saleh *et al.*, in a dose-finding study, observed a response (2 CRs, 1 PR) in three of nine patients treated with the highest dose of 375 mg/m².¹⁰ In abstract form, Cooper *et al.* described 57 patients with refractory ITP treated with rituximab, with an overall response rate of 72% and complete lasting responses in 28%.⁷ In all these studies rituximab was well tolerated and side effects were typically brief and of mild intensity. As in previous studies concerning NHL, adverse events were predominantly infusion-related and generally consisted of mild (grades 1 and 2 according to the National Cancer Institute criteria), symptoms of fever, chills, rigor, rash, nausea and, rarely, mild respiratory symptoms and hypotension.^{5,8,15} In our patient, no side effects were noted. The mechanism of action of rituximab in autoimmune diseases has not yet been elucidated. The rationale for its use rests on the assumption that depletion of B cells leads to a reduction in autoantibody production. Indeed, rapid depletion of circulating B cells, usually after the first gift of rituximab, is observed in all studies, with a complete recovery within 12 months.^{5,8} However, despite universal B-cell depletion, some patients respond to rituximab and others do not. Platelet-associated autoantibodies decrease to normal in most, but not all patients with a long-lasting response, but normalisation is also reported in some nonresponding patients.^{5,16} Two different time patterns of response to rituximab can be identified: early responders, with a rapid rise in the platelet count after the first or second antibody infusion, and late responders with a reaction between week 6 and 10.^{8,11} It is speculated that the early response is mediated by a mechanism of Fc-receptor saturation of mononuclear phagocytes by opsonised B

cells and that decreased antiplatelet antibody production accounts for the late response.¹¹

This case report illustrates that rituximab may also be effective in steroid-responsive frequently relapsing ITP, and that rituximab might actually be a much less toxic treatment in chronic relapsing ITP than other alternatives. Follow-up in our patient is only seven months. However, because this period is at least twice as long as previous treatment intervals, and considering the serious and increasing adverse events from dexamethasone, treatment with rituximab resulted in a substantial improvement in quality of life in our patient. However, one has to be cautious with experimental treatment in patients with nonmalignant diseases. Prospective studies on long-term effectiveness and side effects of rituximab and comparison with standard treatment options for chronic ITP are warranted. In the near future, a prospective Dutch study on the role of rituximab in ITP will be commenced, most likely coordinated by the Dutch HOVON group (Huijgens and Vreugdenhil; personal communication).

NOTE

N.P. Riksen is a recipient of an AGIKO fellowship of the Netherlands Organisation for Scientific Research (ZonMw).

REFERENCES

1. Cines DB, Blanchette VS. Immune thrombocytopenic purpura. *New Engl J Med* 2002;346:995-1008.
2. George JN, Woolf SH, Raskob GE, et al. Idiopathic thrombocytopenic purpura: a practice guideline developed by explicit methods for the American Society of Hematology. *Blood* 1996;88:3-40.
3. Portielje JEA, Westendorp RGJ, Kluin-Nelemans HC, Brand A. Morbidity and mortality in adults with idiopathic thrombocytopenic purpura. *Blood* 2001;97:2549-54.
4. George JN, Kojouri K, Perdue JJ, Vesely SK. Management of patients with chronic, refractory idiopathic thrombocytopenic purpura. *Semin Hematol* 2000;37:290-8.
5. Stasi R, Pagano A, Stipa E, Amadori S. Rituximab chimeric anti-CD20 monoclonal antibody treatment for adults with chronic idiopathic thrombocytopenic purpura. *Blood* 2001;98:952-7.
6. Aggarwal A, Catlett JP. Rituximab: an anti-CD20 antibody for the treatment of chronic refractory thrombocytopenic purpura. *South Med J* 2002;95:1209-12.
7. Cooper N, Stasi R, Feuerstein M, Bussell JB. Transient B cell depletion with rituximab, an anti CD20 monoclonal antibody, resulted in lasting complete responses in 16 of 57 adults with refractory immune thrombocytopenic purpura. Abstract of the 44th Annual Meeting of the American Society of Hematology, 2002.
8. Giagounidis AAN, Anhof J, Schneider P, et al. Treatment of relapsed idiopathic thrombocytopenic purpura with the anti-CD20 monoclonal antibody rituximab: a pilot study. *Eur J Haematol* 2002;69:95-100.

9. Perotta A, Sunneberg TA, Scott J, et al. Rituxan® in the treatment of chronic idiopathic thrombocytopenia purpura (ITP). *Blood* 1999;94:A49 [abstract].
10. Saleh MN, Gutheil J, Moore M, et al. A pilot study of the anti-CD20 monoclonal antibody rituximab in patients with refractory immune thrombocytopenia. *Semin Oncol* 2000;27(suppl 12):99-103.
11. Stasi R, Stipa E, Forte V, Meo P, Amadori S. Variable patterns of response to rituximab in adults with chronic idiopathic thrombocytopenic purpura. *Blood* 2002;99:3872-3.
12. Zaja F, Iacona I, Masolini P, et al. B-cell depletion with rituximab as treatment for immune hemolytic anemia and chronic thrombocytopenia. *Haematologica* 2002;87:189-95.
13. Cohen YC, Djulbegovic B, Shamai-Lubovitz O, Mozes B. The bleeding risk and natural history of idiopathic thrombocytopenic purpura in patients with persistent low platelet counts. *Arch Intern Med* 2000;160:1630-8.
14. Lechner K, Rintelen C, Weltermann A, Kyrle PA, Pabinger I. The risk of bleeding and the risk of overtreatment in immune thrombocytopenic purpura. *Hematol J* 2002;3(suppl 2):162-5.
15. Maloney DG, Grillo-Lopez AJ, White CA, et al. IDEC-C2B8 (rituximab) anti-CD20 monoclonal antibody therapy in patients with relapsed low-grade non-Hodgkin's lymphoma. *Blood* 1997;90:2188-95.
16. Cooper N, Feuerstein M, McFarland J, Milligan L, Cunningham-Rundles S, Bussel JB. Investigating the mechanism of action of rituximab, an anti-CD20 monoclonal antibody in adults with immune thrombocytopenic purpura. Abstract of the 44th Annual Meeting of the American Society of Hematology, 2002.