

# Hypomagnesaemia due to use of proton pump inhibitors – a review

M.T. Kuipers<sup>1</sup>, H.D. Thang<sup>2</sup>, A.B. Arntzenius<sup>1\*</sup>

Departments of <sup>1</sup>Internal Medicine and <sup>2</sup>Nephrology, Spaarne Hospital, Hoofddorp, the Netherlands,  
\*corresponding author: tel.: +31 (0)23-890 71 44, fax: +31 (0)23-890 89 89,  
e-mail: ABArntzenius@spaarneziekenhuis.nl

## ABSTRACT

Magnesium homeostasis is essential for many intracellular processes and depends on the balance of intestinal absorption and renal excretion. Hypomagnesaemia may arise from various disorders.

We review the literature on hypomagnesaemia due to the use of proton pump inhibitors, as illustrated by a case of a 76-year-old woman with muscle cramps and lethargy caused by hypomagnesaemia and hypocalcaemia with a low parathyroid hormone level while using esomeprazole, a proton pump inhibitor (PPI). After oral magnesium repletion both abnormalities resolved. Fractional magnesium excretion was low, excluding excessive renal loss. A causal relation with PPI use was supported by the recurrence of hypomagnesaemia after rechallenge. In the past decade our understanding of transcellular magnesium transport was enhanced by the discovery of several gene mutations i.e. transient receptor potential melastin (TRPM) 6 and 7. In this light we discuss the possible aetiology of proton pump inhibitor related hypomagnesaemia.

## KEYWORDS

Hypocalcaemia, hypomagnesaemia, proton pump inhibitors, TRPM6, TRPM7

## INTRODUCTION

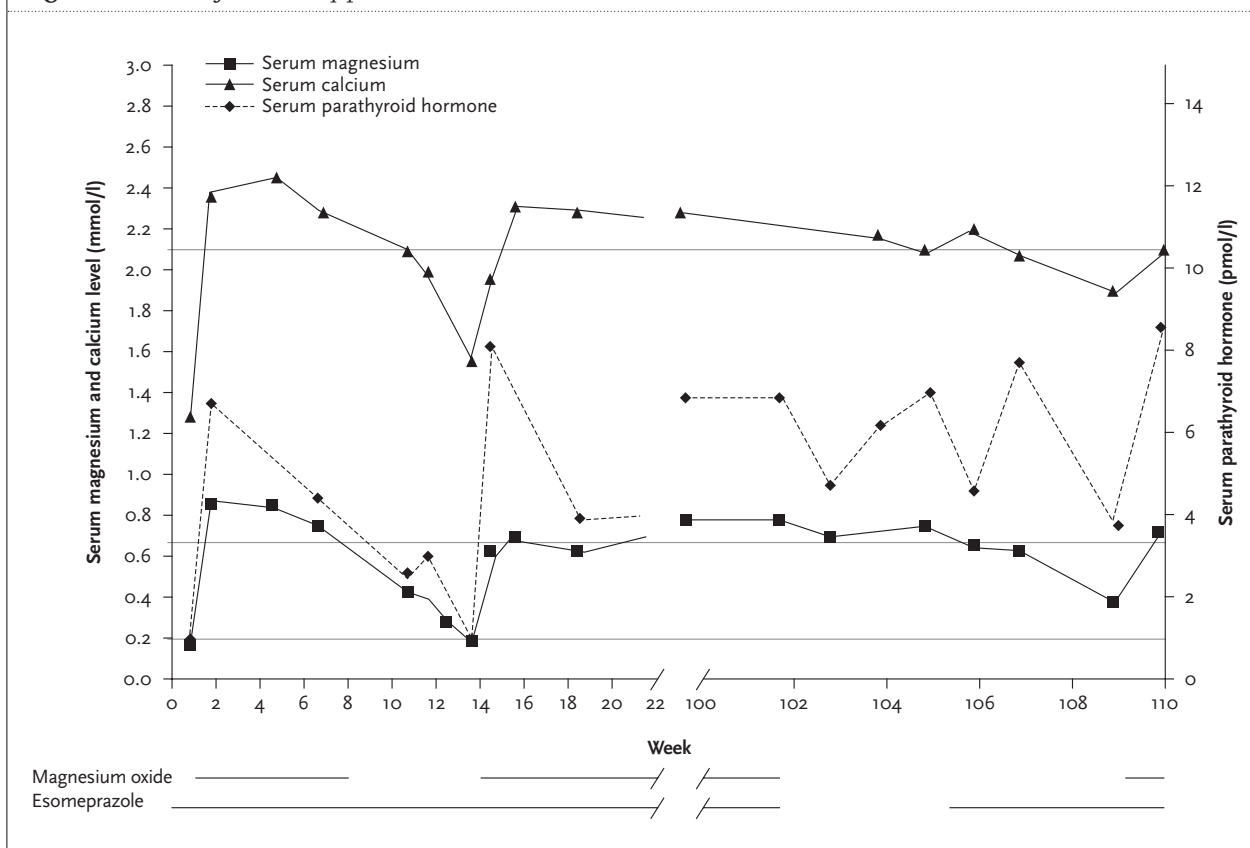
Magnesium is implicated in many biochemical and physiological processes in our body as an essential cation. Although homeostasis of magnesium is tightly regulated by a dynamic interplay of intestinal absorption, exchange with bone and renal excretion, hypermagnesaemia and hypomagnesaemia occur. Hypomagnesaemia may arise from various disorders and can cause tetany,

convulsions, cardiac arrhythmias, hypoparathyroidism and hypocalcaemia. Recently three case reports described six adults with hypomagnesaemia and hypocalcaemia which resolved after withdrawal of the proton pump inhibitor.<sup>1,3</sup> In this case we present another patient with severe hypomagnesaemia due to extra renal magnesium loss associated with the use of esomeprazole.

## CASE REPORT

A 76-year-old woman presented at our emergency department with lethargy and muscle cramps in the abdomen and extremities. Her medical history included an appendectomy, diverticulosis, gastro-oesophageal reflux symptoms, sliding diaphragmatic hernia, benign paroxysmal positional vertigo and ischaemic heart disease. There was no history of other gastrointestinal operations, chronic alcoholism or use of laxatives. She did not complain of nausea, vomiting or diarrhoea. For one year she had been taking esomeprazole (40 mg/day) because of the indication for aspirin and the history of reflux symptoms. Her other medications were aspirin, diltiazem, oxazepam, psyllium fibres and simvastatin. Physical examination showed no abnormalities, Trousseau's and Chvostek's signs were negative. On admission the laboratory findings showed hypocalcaemia (1.26 mmol/l), hypomagnesaemia (0.18 mmol/l), hypokalaemia (3.2 mmol/l) and a low parathyroid hormone (0.9 pmol/l). Her serum vitamin D<sub>3</sub> level was normal. There was neither alkalosis nor acidosis. We started intravenous calcium and magnesium supplementation. In three days the calcium, potassium, magnesium and parathyroid hormone (PTH) level normalised and her symptoms slowly resolved (*figure 1*). We interpreted these results as severe hypomagnesaemia with secondary hypoparathyroidism. After 11 days she was discharged

Figure 1. Course of laboratory parameters over time



with oral magnesium supplements (magnesium oxide 500 mg three times daily). Two months later the magnesium was discontinued. Within four weeks a dramatic drop in the serum magnesium and calcium followed. The fractional magnesium excretion was 0.69% (table 1). This suggests a total body magnesium deficiency due to extra renal magnesium wasting. About two years later we challenged the notion that proton pump inhibitors can cause hypomagnesaemia by impairing the intestinal magnesium uptake. We discontinued the magnesium supplements and the esomeprazole. The serum magnesium and calcium level did not change in four weeks. Because of increasing symptoms of gastro-oesophageal reflux we let her resume the esomeprazole. Within four weeks the serum magnesium level dropped to 0.4 mmol/l. The pattern we observed in our patient fits nicely with the theory of proton pump inhibitor induced intestinal magnesium loss that was suggested in three recent publications on similar case histories.<sup>1-3</sup>

## DISCUSSION

We describe an adult patient presenting with severe hypomagnesaemia and hypocalcaemia while using

a proton pump inhibitor. Discontinuation of her treatment with magnesium supplements resulted in hypomagnesaemia and hypocalcaemia. We also documented that during withdrawal of magnesium supplements and esomeprazole the electrolyte balance did not change. There are several disorders which may cause hypomagnesaemia. In recent years several genes were shown to be involved in renal magnesium and to some extent intestinal magnesium transport. FXD2 gene mutation causes autosomal dominant renal wasting with hypocalciuria due to mutations in the  $\gamma$  subunit of Na,K-ATPase at the basolateral membrane of the distal convoluted tubule (DCT). SLC12A3 gene mutation causes Gitelman's syndrome due to a problem in the Na,K-2Cl<sup>-</sup> co-transporter. Mutations in genes encoding claudin 16 and claudin 19, structural proteins found as part of the tight junction between cells of the thick ascending limb of Henle's loop, cause familial hypomagnesaemia syndrome with hypercalciuria and nephrocalcinosis. Groenestege *et al.* showed that EGF plays an important role in renal magnesium regulation.<sup>4</sup> Pro-EGF is a membrane protein expressed at high levels in the luminal and low levels in the basolateral membranes of the DCT. P1070L mutation in the EGF gene prevents EGF secretion, especially in the basolateral space. This reduces TRPM6 activity, the key

channel that allows magnesium reabsorption. Therefore EGF antagonists i.e. gefitinib, cetuximab, erlotinib and panitumumab induce hypomagnesaemia.

In this case there was no SLC12A3 gene mutation. Renal conservation of magnesium and calcium during esomeprazole use was normal (table 1), which was also described earlier by Epstein *et al.* and Shabajee *et al.*<sup>2,3</sup> This suggests that the problem did not arise in the kidney.

Gastrointestinal causes are diarrhoea, short bowel syndrome, fistula, a magnesium free diet and very rarely a malabsorption syndrome. The average daily diet contains approximately 360 mg (=15 mmol) magnesium.<sup>5</sup> About 24 to 75% of this ingested magnesium is absorbed, depending on dietary contents and body stores. In a normal secreting stomach the high H<sup>+</sup> concentration is competing with the metal ions for the ligand binding sites in food and so liberating the metals.<sup>6</sup> Gastric acid suppression therapy with proton pump inhibitors causes low gastric hydrochloric acid secretion. Theoretically we can assume that the absorption of magnesium falls in hypochlorhydric subjects but evidence for magnesium malabsorption in proton pump inhibitor users is lacking. Limited studies show conflicting conclusions.<sup>6</sup> The intestinal magnesium absorption occurs in two ways: in a passive paracellular manner and in an active saturable transcellular manner. About 90% of the absorption happens passively and linear with the dietary magnesium content.<sup>7</sup> Free magnesium follows its concentration gradient and flows down the paracellular pathway. The fact that treatment with oral magnesium supplements is effective suggests a normal passive paracellular pathway and a problem in the active transcellular route. The active transcellular pathway has become clearer since the identification of

TRPM6 and TRPM7. These channels conduct divalent cations (magnesium and calcium) into the cell following the transmembrane electrochemical gradient.<sup>7</sup> TRPM6 is expressed along the entire gastrointestinal tract, in the kidney (predominantly in the DCT), in testis and lung tissue, TRPM7 is omnipresent in tissues. A mutation in TRPM6 was found responsible for primary hypomagnesaemia with secondary hypocalcaemia (HSH). This rare autosomal recessive disorder was first described by Paunier and colleagues in 1968.<sup>8</sup> Patients present in early infancy with diarrhoea, tetany and/or convulsions. Premature stop mutations, exon deletions, frame shifts and inserted splice sites are the identified mutations and lead to loss of function of the TRPM6 channel. This disease, together with the expression pattern of TRPM6, showed us that TRPM6 is responsible for the absorption of magnesium renally and in the intestines.<sup>9</sup> There are several hormonal and other factors that have an influence on TRPM6/7 expressions and their magnesium transport. Li *et al.* showed that the TRPM6/7 channel activity is potentiated by external protons.<sup>10</sup> In another *in vitro* study they demonstrated that glutamates in the pore-forming region of TRPM6/7 are responsible for the divalent selectivity and pH sensitivity. Mutations in these negatively charged amino acids produced dramatic changes in the channel function with a decreased calcium and magnesium permeation. Proton pump inhibitor users lack intestinal protons, i.e. they have a more alkalic intraluminal pH. To our knowledge clinical manifestations have not been described in heterozygotic mutations in TRPM6/7. Could it be that variants in TRPM6/7 may predispose to the side effect of proton pump inhibitors as described in this article? The effect of proton pump

**Table 1.** Electrolyte balance and other biochemical data at admittance, during and after magnesium supplements and esomeprazole

	Normal value	Day 1	3 months*	6 months	2 years and 1 month**	2 years and 2 months***
Serum magnesium	0.65-1.05 mmol/l	0.18	0.39	0.67	0.74	0.4
Serum calcium	2.10-2.60 mmol/l	1.26	1.99	2.18	2.09	1.85
Serum potassium	3.5-5.0 mmol/l	3.3	4.1	4.6	4.1	3.7
Serum albumin	35-55 g/l	40.9	44.3	n.d.	n.d.	n.d.
Serum creatinine	50-100 umol/l	91	108	n.d.	112	99
Serum vitamin D3	30-130 nmol/l	39	n.d.	58	n.d.	n.d.
Serum parathyroid hormone	1.0-7.5 pmol/l	0.9	3	3.9	7.0	4.6
Urinary magnesium	3.0-5.0 mmol/24 h	n.d.	0.11	n.d.	n.d.	n.d.
Urinary calcium	1.25-10 mmol/24 h	n.d.	0.08	n.d.	n.d.	n.d.
Urinary creatinine	10-12 mmol/24 h	n.d.	6.4	n.d.	n.d.	n.d.
Urinary volume	ml/24 h	n.d.	1600	n.d.	n.d.	n.d.

n.d. = not determined. \*Three weeks after stopping magnesium supplements with continuing esomeprazole. \*\*Plasma magnesium still remains normal four weeks after stopping magnesium supplements and esomeprazole. \*\*\*Plasma magnesium drops dramatically four weeks after resuming esomeprazole without magnesium supplements.

inhibitors on TRPM6/7 has not yet been determined, so this field still remains an active area of research.

While awaiting additional studies, we suggest that magnesium loss in proton-pump inhibitor users should be considered in the differential diagnosis of hypomagnesaemia of any age. This newly recognised side effect may not even be extremely rare once prescribers become aware of its existence.

## REFERENCES

1. Cundy T, Dissanayake A. Severe hypomagnesaemia in long-term users of proton-pump inhibitors. *Clin Endocrinol (Oxf)*. 2008;69(2):338-41.
2. Epstein M, McGrath S, Law F. Proton-pump inhibitors and hypomagnesemic hypoparathyroidism. *N Engl J Med*. 2006;26:355(17):1834-6.
3. Shabajee N, Lamb EJ, Sturgess I, Sumathipala RW. Omeprazole and refractory hypomagnesaemia. *BMJ*. 2008;10:337:a425.
4. Groenestege WM, Thebault S, van der Wijst J, et al. Impaired basolateral sorting of pro-EGF causes isolated recessive renal hypomagnesemia. *J Clin Invest*. 2007;117(8):2260-7.
5. Todd Alexander R, Hoederop JG, Bindels RJ. Molecular Determinants of Magnesium Homeostasis: insight from human disease. *J Am Soc Nephrol*. 2008;19:1451-8.
6. Evenepoel P. Alteration in digestion and absorption of nutrients during profound acid suppression. *Best Pract Res Clin Gastroenterol*. 2001;15(3):539-51.
7. Quamme G. Recent developments in intestinal magnesium absorption. *Curr Opin Gastroenterol*. 2008;24:230-5.
8. Paunier L, Radde IC, Kooh SW, Conen PE, Fraser D. Primary hypomagnesemia with secondary hypocalcemia in an infant. *Pediatrics*. 1968;41:385-402.
9. Schlingmann KP, Waldegger S, Konrad M, Chubanov V, Gudermann T. TRPM6 and 7 Gatekeepers of human magnesium metabolism. *Biochim Biophys Acta*. 2007;1772(8):813-21.
10. Li M, Jiang J, Yue L. Functional characterization of homo- and heteromeric channel kinases TRPM6 and TRPM7. *J Gen Physiol*. 2006;127(5):525-37.
11. Li M, Du J, Jiang J, et al. Molecular determinants of Mg and Ca permeability and pH sensitivity in TRPM6 and TRPM7. *J Biol Chem*. 2007;282(35):25817-30.