

# Goitre and hearing impairment in a patient with Pendred syndrome

L.I. Arwert\*, J.M. Sepers

Department of Internal Medicine and Endocrinology, Medical Centre Alkmaar, Wilhelminalaan 12, 1815 JD Alkmaar, the Netherlands, \*corresponding author: tel.: +31 (0)72-548 44 44, fax: +31 (0)72-548 21 65, e-mail: l.i.arwert@mca.nl

## ABSTRACT

A case is described here of a young euthyroid woman with a goitre and hearing impairment. Perchlorate discharge test showed increased washout of iodine. Genetic analysis confirmed the diagnosis of Pendred syndrome as a mutation in the *Pds* gene was found. The patient was treated with potassium iodine orally. During follow-up there were no symptoms of hyperthyroidism and the size of the goitre decreased.

## KEYWORDS

Deafness, goitre, Pendred syndrome, thyroid dysfunction

## INTRODUCTION

The classical triad of Pendred syndrome is congenital sensorineural hearing impairment, goitre and impaired iodine organification with an abnormal perchlorate discharge test. Pendred syndrome is the most common diagnosis in syndromal hearing impairment with an incidence of 7.5 to 10 per 100,000 people. Magnetic resonance imaging of the inner ear shows malformations of the vestibular aqueduct and endolymphatic sac. The prevalence of Pendred syndrome in the Netherlands and the optimal therapy is unknown. This autosomal recessive syndrome is not often seen by the internal medicine specialist.

## CASE REPORT

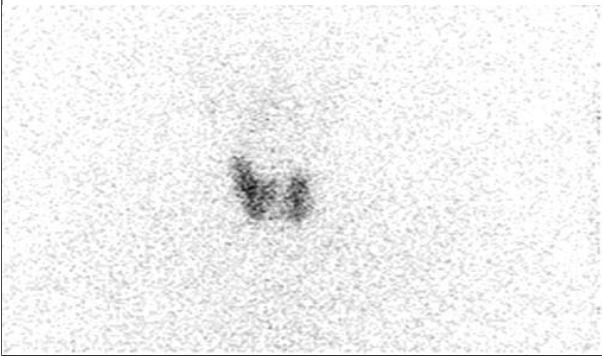
A 30-year-old woman visited our outpatient clinic because of a visible goitre. She reported hearing impairment since childhood. Overall she felt well. Her menses were regular and there were no symptoms of thyroid dysfunction.

When she was 14 years old she had a thyroid operation (excision of part of the goitre) in another hospital because of enlarging of a goitre with cosmetic complaints. She was euthyroid at that time and using a Kocher's incision two cystic nodules were removed. Pathological examination showed two dysplastic nodules of follicular thyroid tissue. The follicles were full of colloid. No necrosis, inflammation or malignancy were seen. Her mother also had a goitre, but no hearing problems. She has a healthy daughter aged 2 years. There were no other family members with thyroid diseases or hearing problems.

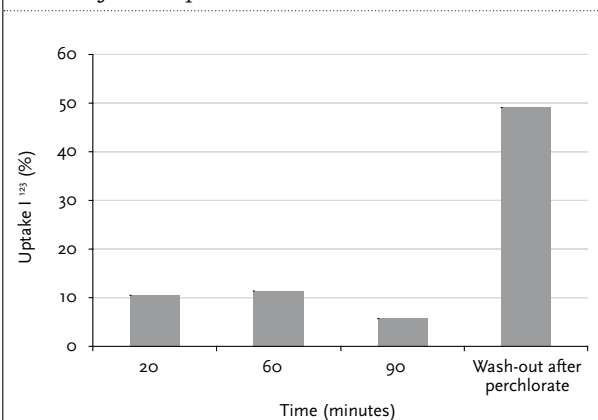
Physical examination showed a woman with a scar in her neck from the previous thyroid operation. Her body mass index was 20 kg/m<sup>2</sup> and she had no signs of hypothyroidism or hyperthyroidism. She had a visible goitre. The thyroid was enlarged and felt weak with multiple palpable nodules (thyroid diameter 8 x 6.5 cm). Laboratory tests showed a free thyroxine (T<sub>4</sub>) level of 9.9 pmol/l (normal value 9 to 20 pmol/l) and a thyroid-stimulating hormone level of 2.5 mU/l (normal value 0.15 to 5.0 mU/l).

An X-ray of the trachea showed mild narrowing of the trachea at the level of the first thoracic vertebra with mild impression from the left side. An ultrasound of the thyroid showed multiple nodules in the left and right part of the thyroid (diameters 2.6, 2.3, 1.6 and 1.3 cm). A thyroid scintigraphy with 3.8 MBq of I<sup>123</sup> was performed with imaging at 20, 60 and 90 minutes after administration of the iodine. This showed an enlarged thyroid with homogeneous uptake (figures 1 and 2). Sixty minutes after the iodine administration, 600 mg of perchlorate was administered and the washout was measured (perchlorate discharge test). Both the uptake and washout were increased. Increased discharge points to an organification defect as in Pendred syndrome, as is mentioned below in the discussion.

**Figure 1.** Thyroid scintigraphy after iodine-123 showed homogeneous uptake



**Figure 2.** Uptake measured during 20, 60 and 90 minutes follow-up



After 60 minutes 600 mg of perchlorate was administered. A washout above 10% is suggestive of Pendred syndrome.

Molecular genetic testing showed two pathogenic mutations in the Pendred gene (SLC26A4). There was a mutation in exon 6 c.707T>C (Leu236Pro) and in intron 8 c.1001+1G>A. This confirmed the diagnosis of Pendred syndrome. She was treated with oral potassium iodine 2 mg twice daily. Two years later she was doing well and had no symptoms. She was taking oral potassium chloride, and her thyroid levels were within the normal range and the size of the goitre decreased.

## DISCUSSION

Pendred syndrome was clinically recognised and concisely described in 1896 by the English general practitioner Vaughan Pendred (1869-1946).<sup>1</sup> A century later in 1997 Coyle and colleagues discovered the gene for Pendred syndrome.<sup>2</sup> This gene is located on the long arm of

chromosome 7. Until now, more than 80 mutations in the *Pds* gene have been described, mostly missense mutations, but also truncations.

Pendred syndrome is an autosomal recessive disease on the base of a mutation of the *PD* gene (*Pds*), region SLC26A4. The *Pds* gene encodes 12 exons which forms a protein called pendrine. This protein acts as a chloride-iodine co-transporter and is expressed in the thyroid, inner ear and kidney. This transporter is closely related to a number of sulphate transporters. Pendrine functions as an ion transporter, located on the apical membrane of the thyrocytes. This transporter is responsible for the transport of iodine out of the cell into the colloid where iodination of thyroglobulin occurs. In the absence of the transporter, iodine is taken up normally by the thyrocyte, but is not efficiently bound to thyroglobulin in the colloid. A mutation of the pendrine gene gives less transport of iodine to the exocytic vesicles, in which thyroid hormone is formed, and results in impaired organification of thyroglobulin. Goitre is the most variable symptom in Pendred syndrome and is caused by impaired thyroxin production because of an organification defect. Goitre prevalence is dependent of the daily iodine intake and is, for example, seldom seen in Japan, where the daily iodine intake is high. Most patients have normal thyroid levels, but some have signs of subclinical or clinical hypothyroidism. In the kidneys, pendrine is expressed in the cortical collecting ducts and acts as a chloride-bicarbonate exchanger. However, no metabolic changes (acidosis or alkalosis) are described in patients with Pendred syndrome. Pendrine is expressed in the inner ear for regulation of the endolymphatic fluid composition. The pathophysiological mechanism of the hearing impairment is unclear. In mice knocked out for the *Pds* gene an abnormal endolymphatic duct and sac dilatation are described on the 15th embryonic day, but these mice have no goitre.<sup>3</sup> Magnetic resonance imaging can show dysplasia of the cochlea and vestibular aqueduct in patients with Pendred syndrome (Mondini deformity). The perchlorate discharge test is used to diagnose Pendred syndrome. The sensitivity of this test is unknown and the test is not specific. Patients have to follow an iodine-restricted diet for two weeks. For the test iodine (I<sup>123</sup>) is given orally followed by 600 mg perchlorate intravenously after which the discharge is measured. Perchlorate inhibits NIS function (sodium iodine symporter) eliminating the iodine gradient which is required for maintaining the iodine in the gland. The exit (washout/discharge) of more than 10% of the thyroidal radioiodine within two hours of administration of the perchlorate suggests on organification defect as in Pendred syndrome. The rationale for treatment with potassium iodine is that extra iodine may compensate for the insufficient iodine handling of the thyroid in Pendred syndrome.

## CONCLUSION

In this case report we describe the history of a young woman with goitre and hearing impairment with an impaired perchlorate washout test. Genetic testing confirmed the diagnosis of Pendred syndrome with a mutation in the *Pds* gene. She underwent surgery in childhood that was perhaps unnecessary and is now treated with potassium iodine. After starting the therapy the goitre decreased in size.

## REFERENCES

1. Pendred V. Deaf-mutism and goiter. *Lancet* 11 1896:532.
2. Coyle B, Coffrey R, Armour JAL, et al. Pendred syndrome (goitre and sensorineural hearing loss) maps to chromosome 7 in the region containing the nonsyndromic deafness gene *DFNB4*. *Nat Genet* 1996;12:421-3.
3. Everett LA, Belyantseva IA, Noben-Trauth K, et al. Targeted disruption of mouse *PDS* provides insight about the inner-ear defects encountered in Pendred syndrome. *Hum Mol Genet* 2001;10:153-61.