

Papillary thyroid carcinoma in a patient with sarcoidosis treated with minocycline

N.A. Bruins¹, J.E. Oswald¹, H. Morreau², J. Kievit³, S. Pavel⁴, A.H.M. Smelt^{1*}

Departments of ¹General Internal Medicine and Endocrinology, ²Pathology, ³Surgery and ⁴Dermatology, Leiden University Medical Centre, Leiden, the Netherlands, *corresponding author: tel.: +31 (0)71-526 35 42, fax: +31 (0)71-524 81 40, e-mail: ahmsmelt@lumc.nl

ABSTRACT

Long-term treatment with minocycline is occasionally associated with the development of black thyroid syndrome in which thyroid cancer is frequently found. Here, we report a patient with cutaneous, pulmonary and thyroid sarcoidosis who developed papillary thyroid carcinoma in the presence of a black thyroid syndrome after being treated with minocycline for 2.5 years.

KEYWORDS

Black thyroid, minocycline, papillary thyroid carcinoma, sarcoid reaction, sarcoidosis

INTRODUCTION

Long-term treatment with minocycline is occasionally associated with the development of black thyroid syndrome, first described in humans in 1976.¹ Fourteen years later an association between this syndrome and thyroid cancer was made. To date eight cases of thyroid carcinoma have been found in 29 cases with black thyroid syndrome.²⁻⁹

Minocycline is commonly used in the treatment of severe acne. Recently patients with cutaneous sarcoidosis have been effectively treated with minocycline.¹⁰

We describe a patient with cutaneous, pulmonary and thyroid sarcoidosis, who developed a papillary carcinoma during minocycline therapy.

CASE REPORT

A 35-year-old female with a medical history of cutaneous and pulmonary sarcoidosis visited the outpatient clinic with a swelling in her neck. Initially the sarcoid

skin lesions were treated with isotretinoin and long-wave (UVA1) therapy. When this treatment proved to be inadequate, minocycline (200 mg/day) was started. She had been treated for a period of 2.5 years when a papillary thyroid carcinoma was diagnosed. The first time our patient detected the swelling in her neck was after seven months of minocycline therapy. Ultrasound repeatedly showed a nodule in the left lobe of the thyroid. Cytological examination of fine needle aspirates did not show any signs of malignancy until two years later, when multiple papillary cell groups suspect for papillary thyroid carcinoma were detected. Thyroid function was within normal limits throughout (FT₄ 13.2 to 17.6 pmol/l and TSH 0.84 to 1.64 mU/l). Minocycline therapy was stopped and a total thyroidectomy performed.

The total thyroidectomy specimen weighing 29 g had a greyish-white appearance. In the left lobe an encapsulated tumour was found measuring 2.7 x 1.8 x 2.6 cm. Light microscopy revealed a tumour encapsulated by fibrous tissue. The tumour cells showed nuclear clearing and nuclear grooves (*figure 1*). No pigmentation was seen in the tumour.

The surrounding nonneoplastic thyroid parenchyma contained intracytoplasmic dark-brown pigmented granules (*figure 2*). In the thyroid, especially surrounding the tumour, sarcoid granulomas were seen (*figure 3*).

DISCUSSION

Minocycline is a broad-spectrum antibiotic, commonly used in the treatment of severe acne. Recently it has been shown to also be effective in the treatment of cutaneous sarcoidosis.¹⁰

The most relevant side effects of minocycline are dizziness, nausea, diarrhoea, hyperpigmentation of the

Figure 1. Papillary carcinoma cells of the thyroid, demonstrating nuclear clearing and nuclear grooves (haematoxylin and eosin stain; original magnification, 200x)

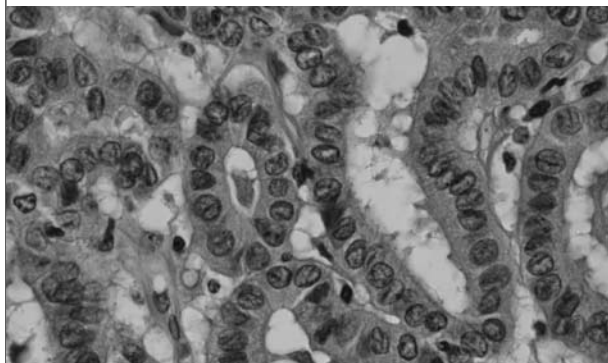


Figure 2. Intracytoplasmic pigment granules in nonneoplastic thyroid (haematoxylin and eosin stain; original magnification, 100x)

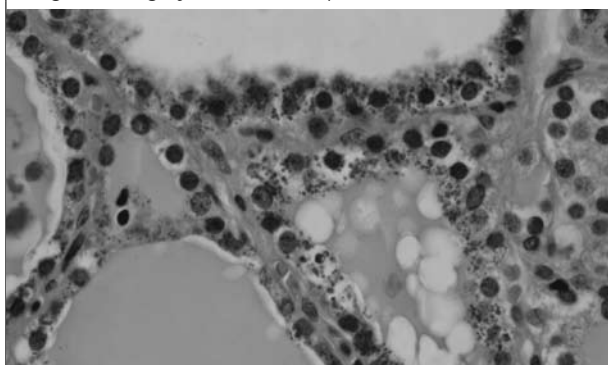
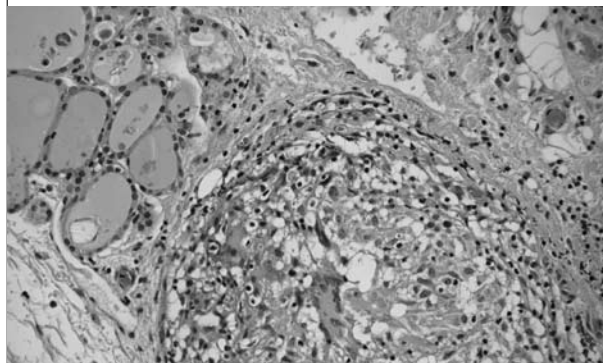


Figure 3. Sarcoid granuloma with epithelioid cells and Langhans giant cells (haematoxylin and eosin stain; original magnification, 50x)



skin and a macroscopic black discoloration of the thyroid gland, designated 'black thyroid syndrome'. This black discoloration of the thyroid is almost pathognomonic for the use of minocycline. Other causes such as haemochromatosis, ochronosis and cystic fibrosis have to be excluded. The mechanism of the pigment deposition that causes the black colouring of the thyroid gland is

still subject of debate. The most favoured opinion is that pigment is formed by oxidation of minocycline by thyroid peroxidase. Thyroid peroxidase is the key enzyme in the synthesis of T₄ and T₃ and therefore essential for normal thyroid function.¹¹

A total of 30 cases of black thyroid associated with the use of minocycline have been identified thus far, including the one we report here. Of these 30 cases, eight exhibit thyroid papillary carcinoma,²⁻⁹ and one case follicular carcinoma (*table 1*).⁸ The duration of minocycline therapy was usually one or more years before the malignancy was discovered.

A causal relationship between minocycline-induced black thyroid and malignancy has never been proven. Many case reports describe an association, however Hecht *et al.* describe seven cases with black thyroid with no malignancies.²⁻⁹ Our patient first noticed a swelling in her neck after seven months of minocycline therapy. A malignancy could not be found until 2.5 years later.

The incidence of thyroid carcinoma in the general population is approximately 3/100,000. In the 30 described cases of black thyroid syndrome nine malignancies exist, which gives a frequency of 3/10. This high frequency is

Table 1. Thyroid carcinoma during/after minocycline therapy

Reference	Age	Sex	Thyroid function	Minocycline therapy in years	Presentation
Onya <i>et al.</i> ²	29	M	N	1	Incidental
Landas <i>et al.</i> ³	27	M	N	2.5	Metastatic neck mass
Pastolero <i>et al.</i> ⁴	27	F	N	1	Metastatic neck mass
Pastolero <i>et al.</i> ⁴	43	F	N	Not known	Neck swelling
Rhagavan <i>et al.</i> ⁵	18	M	N	>2	Neck swelling
Birkedal <i>et al.</i> ⁶	27	F	N	>2	Nodule
Thompson <i>et al.</i> ⁷	44	F	N	Not known	Cold nodule
Jennings <i>et al.</i> ⁸	36	F	N	Not known	Neck swelling [‡]
Bruins <i>et al.</i>	35	F	N	2.5	Neck swelling

[‡]Follicular carcinoma; N = normal.

indicative of a possible association; however, this result may also be due to selection.

Sarcoidosis is a chronic systemic granulomatous disease. The lungs, skin, eyes and liver are mostly affected. Rarely the thyroid gland is involved.¹² Other thyroid diseases, such as Hashimoto's thyroiditis and Graves' disease are known to be associated with systemic sarcoidosis.¹³ One case report describes a possible association between systemic sarcoidosis and papillary cancer¹⁴ and in another case report a patient is described with systemic sarcoidosis, Graves' disease, thyroid sarcoid granuloma and papillary carcinoma.¹⁵ It remains unclear if there is a causative relationship between sarcoidosis of the thyroid and the development of papillary carcinoma.

The same is true for the association between sarcoid reaction and malignancy. In approximately 4% of cancer patients sarcoid reaction occurs. The malignancy is usually localised in lung, breast or uterus. We found only seven cases that describe the combination of sarcoid reaction of the thyroid gland and papillary carcinoma.^{16,17} Six of these cases were Japanese. To our knowledge this is the first report of a patient who used minocycline for sarcoid skin lesions and subsequently developed a black thyroid and papillary thyroid cancer in a thyroid that was also affected by sarcoidosis. Treatment of sarcoid skin lesions with minocycline is relatively new. Possibly patients with sarcoidosis are at more risk of developing thyroid carcinoma when using minocycline. Maybe when more patients are treated an association will become clear.

In summary, we describe a patient with sarcoidosis and minocycline therapy who developed a black thyroid and papillary carcinoma. It is still unclear if there is an association between sarcoidosis and thyroid cancer. The minocycline therapy is possibly the trigger for developing malignancy. When minocycline is used in patients, close monitoring for the development of a thyroid swelling is mandatory.

REFERENCES

1. Attwood HD, Dennet X. A Black Thyroid and Minocycline Treatment. *Br Med J* 1976;2:1109-10.
2. Onya JN, Arick Forrest L, Forsthoefel K. Papillary carcinoma associated with black thyroid gland. *Am J Otolaryngol* 1996;17:299-302.
3. Landas SK, Marsh WL, Schuller DE, Rao MK, Wajda KJ. Non-pigmented papillary carcinoma in a black thyroid gland. *Arch Otolaryngol Head Neck Surg* 1990;116:735-7.
4. Pastoloro GC, Asa SL. Drug-related pigmentation of the thyroid associated with papillary carcinoma. *Arch Pathol Lab Med* 1994;118:79-83.
5. Rhagavan R, Snyder WH, Sharma S. Pathologic quiz case: Tumor in pigmented thyroid gland in a young man. *Arch Pathol Lab Med* 2004;128:355-6.
6. Birkedal C, Tapscott WJ, Giadrosich K, Spence RK, Sperling D. Minocycline-induced black thyroid gland: Medical curiosity or a marker for papillary cancer? *Curr Surg* 2001;58:470-1.
7. Thompson AD, Pasieka JL, Kneafsey P, DiFrancesco LM. Hypopigmentation of a papillary carcinoma arising in a black thyroid. *Mod Pathol* 1999;12:1181-5.
8. Jennings TA, Sheehan CE, Chodos RB, Figge J. Follicular carcinoma associated with minocycline-induced black thyroid. *Endocr Pathol* 1996;7:345-8.
9. Hecht DA, Wenig BM, Sessions RB. Black thyroid: A collaborative series. *Otolaryngol-Head Neck Surg* 1999;121:293-6.
10. Bachelez H, Senet P, Cadranet J, Kaoukhov A, Dubertret L. The use of tetracyclines for the treatment of sarcoidosis. *Arch Dermatol* 2001;137: 69-73.
11. Taurog A, Dorris ML, Doerge DR. Minocycline and the thyroid: Antithyroid effects of the drug and the role of thyroid peroxidase in minocycline-induced black pigmentation of the gland. *Thyroid* 1996;6:211-9.
12. Vailati A, Marena C, Aristia L, et al. Sarcoidosis of the thyroid: Report of a case and a review of the literature. *Sarcoidosis* 1993;10:66-8.
13. Papadopoulos K, Hörnblad I, Liljebladh H, Hallengren B. High frequency of endocrine immunity in patients with sarcoidosis. *Eur J Endocrinol* 1996;134:331-6.
14. Middleton WG, deSouza FM, Gardiner GW. Papillary carcinoma of the thyroid associated with sarcoidosis. *J Otolaryngol* 1985;14:241-4.
15. Zimmerman-Belsing T, Christensen L, Hansen HS, Kirkegaard J, Blichert-Toft M, Feldt-Rasmussen U. A case of sarcoidosis and sarcoid granuloma, papillary carcinoma and Graves' disease in the thyroid gland. *Thyroid* 2000;10:275-8.
16. Yamauchi M, Inoue D, Fukunaga Y, Kakudo K, Koshiyama H. A case of sarcoid reaction associated with papillary thyroid carcinoma. *Thyroid* 1997;7:901-3.
17. Komatsu M, Itoh N, Yazawa M, Kobayashi S, Inoue K, Kuroda T. Sarcoid reaction in thyroid diseases: Report of a case of thyroid carcinoma demonstrating sarcoid reaction in regional lymph nodes. *Endocr J* 1997;44:69-70.