

Successful management of chronic myeloid leukaemia with leucapheresis during a twin pregnancy

R. Klaasen^{1*}, P. de Jong², P.W. Wijermans¹

Departments of ¹Haematology, ²Obstetrics and Gynaecology, Haga Hospital, Leyweg 275, 2545 CH The Hague, the Netherlands, *corresponding author: tel.: +31 (0)70-359 25 56, fax: +31 (0)70- 359 22 09, e-mail: ruthklaasen@casema.nl.

ABSTRACT

We present a 36-year-old woman in whom chronic myeloid leukaemia (CML) was diagnosed during a twin pregnancy. Because of hyperleucocytosis, we started leucapheresis also with the goal of gaining time for discussing treatment options. As this strategy was so effective and our patient was reluctant to take medication, we decided to continue this treatment.

KEYWORDS

CML, pregnancy, leucapheresis

INTRODUCTION

Fortunately, chronic myeloid leukaemia (CML) rarely occurs in pregnant women. Pregnancy does not appear to affect the natural course of CML.¹ Various treatment modalities have been used in the management of this disease during pregnancy. This case report describes the successful use of leucapheresis in a patient with CML during a twin pregnancy. In the discussion we describe possible treatment strategies and explain why we choose this treatment in our patient.

CASE REPORT

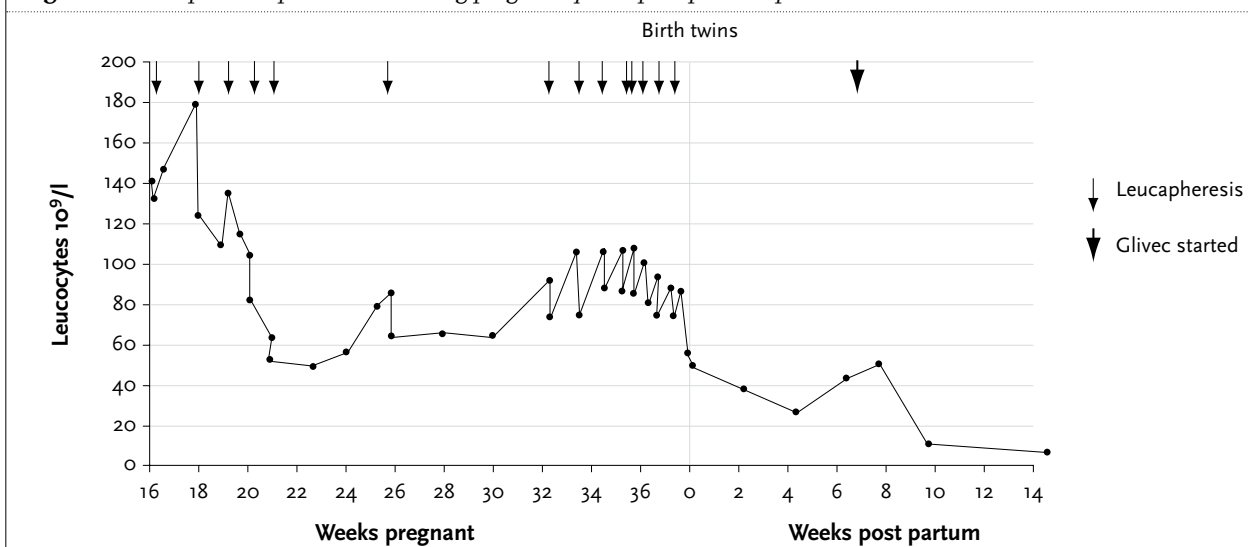
A 36-year-old gravida 3 para 2 was referred to our clinic because a raised white blood cell count was noted after an amniotic fluid puncture. At that moment she was 16 weeks pregnant of dizygote twins. She complained of headache, fatigue and dyspnoea on effort which she had attributed to her pregnancy. Physical examination revealed

splenomegaly and a uterus in conformity with a 16-week twin pregnancy.

Her haematological profile showed a white blood cell count of $140 \times 10^9/l$, haemoglobin of 7.1 mmol/l and platelets of $262 \times 10^9/l$. The differential count was 54% neutrophils, 10% bands, 4% metamyelocytes, 8% myelocytes, 8% promyelocytes, 7% myeloblasts, 1% eosinophils and 0% basophils, 7% lymphocytes and 1% monocytes. A bone marrow aspiration revealed 5% blasts and hypercellularity. Multiple small one nucleus megakaryocytes were seen. Conventional cytogenetic studies showed the presence of the Philadelphia chromosome. Reverse transcriptase polymerase chain reaction confirmed the presence of a head to tail fusion of the breakpoint cluster region (BCR) on chromosome 22 with the Abelson murine leukaemia virus gene (ABL) located on chromosome 9 as well in blood as in bone marrow obtained by aspiration.

Because of the high white blood cell count, the dyspnoea and unknown influence of a high blood cell count on the blood supply of the placenta we started treatment immediately. To gain time to discuss the different treatment options we started leucapheresis. Our patient was very reluctant to take medication, especially chemotherapy, and leucapheresis was well tolerated and very effective, so we decided to continue this therapy. We discussed the risks of only symptomatic treatment with the patient and her partner. Termination of pregnancy was considered but has never been a real option because our patient was already 16 weeks pregnant. All the symptoms disappeared when the leucocyte count dropped below $100 \times 10^9/l$. Elo-haes, normally used for a better separation of cells, was not used because the effect on unborn babies is not known. Sodium citrate was used as anticoagulation. After every pheresis fluid replacement was carried out with fresh frozen plasma and physiological saline. Overall, 14

Figure 1. Leucapheresis procedures during pregnancy and post-partum period



leucapheresis procedures were needed (figure 1). During the 30th week of gestation the leucocyte count rose to over $100 \times 10^9/l$. Simultaneously, the symptoms of our patient reappeared. Again, these symptoms disappeared after restarting leucapheresis. To prevent haemodynamic problems the volume of the pheresis was reduced each time towards the end of the pregnancy and so the frequency of pheresis was increased. At a gestational age of 36 weeks and 5 days a caesarean section was carried out because of breech presentation of both babies. Two girls with a birth weight of 2690 and 2640 g were born. They had normal apgar scores and a normal acid-base equilibrium. One of the babies has a club foot which was contributed to mechanical problems in utero. After delivery we initially planned to start treatment with imatinib and cytarabine according the HOVON protocol. Our patient refused this proposal and was treated with only imatinib. One year later a three log reduction in the BCR-ABL clone was noticed. Both children are developing normally.

DISCUSSION

When our patient presented at 16 weeks' gestation, she had significant hyperleucocytosis. Although the leucocyte count was not high enough to meet the criteria for leucostasis, we were concerned because of potential microvascular complications, especially placental blood flow. To gain time for discussing treatment options we started leucapheresis.

There are several treatment options for CML. For a few years now, imatinib has been the treatment of choice. Little is known about possible teratogenic effects in humans. Imatinib is teratogenic in rats, but not in rabbits, and impaired spermatogenesis occurred in rats, dogs and monkeys.

Hensley and Ford described three patients in clinical trials who became pregnant and proceeded to term.² Two patients delivered normal infants. One baby had a hypospadias. Anecdotal reports may suffer from reporting bias.

The chemotherapeutic agents hydroxyurea and cytarabine have both been used in pregnant women with different haematological malignancies. Theoretically, these drugs may be hazardous for foetal development. However, there are several reports that using chemotherapy from the second trimester does not result in malformations.^{3,4} On the other hand, a few studies report fine congenital abnormalities of the joints when using cytarabine during pregnancy.⁵

Alpha-interferon appeared to be a safer alternative as it has no known effects on DNA and, being a large molecule, is assumed not to cross the placenta barrier to any great extent. Very low levels of IFN- α in newborns compared with maternal levels confirmed this hypothesis.⁶ Alpha-interferon has not been associated with teratogenicity in either animal studies or in humans receiving the drug during pregnancy. One newborn of a mother treated with α -interferon during pregnancy was born with severe thrombocytopenia probably due to α -interferon.⁷

Therefore, α -interferon with or without low-dose cytarabine was one of the treatment options and hydroxyurea was a good alternative. Although leucapheresis has the advantage that exposure to potentially teratogenic agents can be avoided, the overall time to progression is not prolonged. Especially for our patient with a high Sokal index of 1.4, this could be a disadvantage. Haemodynamic instability is one of the complications of leucapheresis and it is imaginable that in pregnant patients this risk is even greater. In PubMed we found eight case reports of pregnant women treated with leucapheresis for different haematological malignancies and none of them mention problems of haemodynamic instability.⁸⁻¹⁵ All these mothers delivered healthy babies.

Because our patient was very reluctant to take medication during her pregnancy and leucapheresis was very effective, we decided to continue this strategy. Two healthy babies were born and the mother showed a three log reduction in the BCR-ABL clone one year following imatinib treatment, which has a very good prognosis.¹⁶ This is the second report of a successful outcome of leucapheresis during a twin pregnancy with CML.

REFERENCES

1. Sheehy WT. An evaluation of the effect of pregnancy on chronic granulocytic leukaemia. *Am J Obstet Gynecol* 1958;75:788.
2. Hensley ML, Ford JM. Imatinib treatment: specific issues related to safety, fertility and pregnancy. *Semin Hematol* 2003;40(suppl2):21-5.
3. Fadilah SA, Ahmad-Zailani H, Soon-Keng C, Norlaila M. Successful treatment of chronic myeloid leukemia during pregnancy with hydroxyurea. *Leukemia* 2002;16:1202-3.
4. Williams SF, Schilsky RL. Antineoplastic drugs administered during pregnancy. *Semin Oncol* 2000;6:618-22.
5. Erdogan D, Kadioglu D, Peker T. Demonstration of congenital anomalies in the joints of the forelimbs and hindlimbs caused by several pharmacological agents. *Anat Histol Embryol* 1996;25:263-7.
6. Haggstrom J, Adransson M, Hybbinette T, Harnby E, Thorbert G. Two cases of CML treated with alpha-interferon during second and third trimester of pregnancy with analysis of the drug in the new-born immediately postpartum. *Eur J Haematol* 1996;57:101-2.
7. Mubarak AA, Kakil IR, Awidi A, et al. Normal outcome of pregnancy in chronic myeloid leukemia with interferon-alpha in 1st trimester: report of 3 cases and a review of the literature. *Am J Hematol* 2002;69:115-8.
8. Strobl FJ, Voelkerding KV, Smith EP. Management of chronic myeloid leukemia during pregnancy with leukapheresis. *J Clin Apheresis* 1999;14:42-4.
9. Bazarbashi MS, Smith MR, Karanes C, Zielinski I, Bishop CR. Successful management of Ph chromosome chronic myelogenous leukemia with leukapheresis during pregnancy. *Am J Hematology* 1991;38:235-7.
10. Fitzgerald D, Rowe JM, Heal J. Leukapheresis for control of chronic myelogenous leukemia during pregnancy. *Am J Hematol* 1986;22:213-8.
11. Ali R, Ozkalemkas F, Ozkocaman V, et al. Successful pregnancy and delivery in a patient with chronic myelogenous leukaemia (CML) and management of CML with leukapheresis during pregnancy, a case report and review of the literature. *Jpn J Clin Oncol* 2004;34:215-7.
12. Broccia G, Casula P, Andria M. Chronic myelocytic leukemia in pregnancy: report of a case treated with leukapheresis. *Tumori* 1984;70:371-4.
13. Caplan SN, Coco FV, Berkman EM. Management of CML in pregnancy by cell pheresis. *Transfusion* 1978;18:120-4.
14. Ali R, Ozakalemkas F, Ozocaman V, et al. Successful labor in the course of chronic lymphocytic leukemia (CLL) and management of CLL during pregnancy with leukapheresis. *Ann Hematol* 2004;83:61-3.
15. Fitzgerald JM, Macann SR. The combination of hydroxyurea and leukapheresis in the treatment of CML in pregnancy. *Clin Lab Haematol* 1993;15:63-5.
16. Press RD, Love Z, Tronnes AA, et al. BCR-ABL mRNA levels at and after the time of a complete cytogenetic response (CCR) predict the duration of CCR in imatinib mesylate-treated patients with CML. *Blood* 2006;107:4250-6.