

An elderly man with swelling and discolouration of the earlobe

F.S. Kleijwegt^{*1}, C. van Krimpen², L.M. Faber¹

¹Department of Internal Medicine, Rode Kruis Hospital, Beverwijk, the Netherlands,

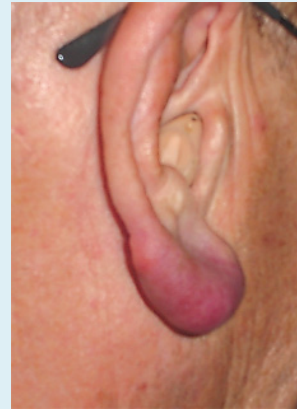
²Department of Pathology, Kennemer Gasthuis, Haarlem, the Netherlands,

*corresponding author: email: f.s.kleijwegt@amc.uva.nl

CASE REPORT

In 2006, an 83-year-old Caucasian male presented himself to the outpatient clinic with cosmetic complaints of an increasingly purple-coloured right earlobe, which had developed over the last few months. His medical history consisted of hearing loss on both sides since 1993, without a clear ENT focus. Intoxication showed no smoking and moderate alcohol consumption (2 units/day). The patient was not on regular medication and had no allergies. The swelling was not painful and he had no weight loss, fever or night sweats. He otherwise felt well and had no other complaints. Upon physical examination it was found that the swelling was purple-red, non-tender and that it felt rubbery. There were no palpable lymph nodes and no hepatosplenomegaly. The neurological exam was unremarkable. A biopsy was performed in the surgery department.

Figure 1a. Swelling and discolouration of the earlobe



WHAT IS YOUR DIAGNOSIS?

See page 256 for the answer to this photo quiz.