

# A patient with cutaneous lesions after liver transplantation

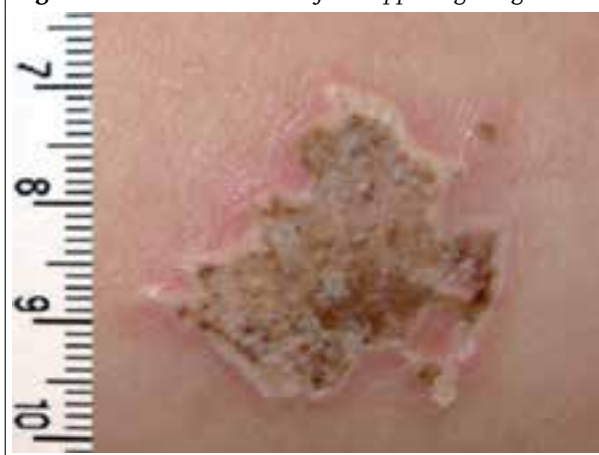M. Olde Bekkink<sup>1\*</sup>, G.F.H. Diercks<sup>2</sup>, A.P. van den Berg<sup>3</sup>, C.J. Tack<sup>1</sup>

<sup>1</sup>Department of Internal Medicine, Radboud University Nijmegen Medical Centre, Nijmegen, the Netherlands, Department of <sup>2</sup>Pathology and <sup>3</sup>Internal Medicine, University Medical Centre Groningen, University of Groningen, Groningen, the Netherlands, \*corresponding author: tel: + 31 (0)24-3619854, fax: +31 (0)24-3541734, e-mail: M.OldeBekkink@aig.umcn.nl

## CASE REPORT

A 28-year-old woman was acutely admitted to our hospital because of sudden onset of high fever, chills and abdominal pain. Her past medical history revealed a metabolic disorder complicated by liver cirrhosis, for which she had received a liver transplantation three months earlier. The patient was on immunosuppressants, antiviral medication and *Pneumocystis jiroveci* pneumonia (PJP) prophylaxis. The transplantation was complicated by postoperative bleeding for which coiling of the splenic and gastroduodenal arteries was performed. Antithrombotic prophylaxis consisted of subcutaneous nadroparin. On physical examination at admission, the patient was acutely ill, had high fever, low blood pressure and severe tachycardia. In addition, multiple lesions were seen on the upper legs. The lesions were non-painful, firm and measured up to 2.5 cm in size, with an erythematous, yellow border (*figure 1*). Laboratory investigation revealed: corrected calcium 2.39 (2.20-2.65 mmol/l), phosphate 1.15 (0.80-1.40 mmol/l), creatinine 123 µmol/l (45-90 µmol/l), C-reactive protein 61 mg/l (< 10 mg/l) and leucocyte count  $0.9 \times 10^9/l$  ( $4-11 \times 10^9/l$ ). The patient was treated with volume replacement and broad-spectrum antibiotics.

Figure 1. Cutaneous lesion of the upper right leg



Over 12 hours her condition stabilised and she gradually recovered. The skin lesions remained unchanged.

## WHAT IS YOUR DIAGNOSIS?

See page 36 for the answer to this photo quiz.

## DIAGNOSIS

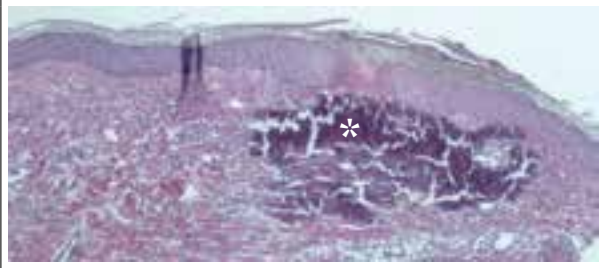
The diagnosis is calcinosis cutis due to nadroparin injections: a rare non-immunological side effect of an extensively used therapy. The fever was caused by *Staphylococcus aureus* splenic abscess and sepsis. Calcinosis cutis is caused by abnormal cutaneous deposits of calcium and phosphate salts. On physical examination variable presentations can be seen including erythema, blebs, yellow borders, ulcerated plaques and subcutaneous nodules.<sup>1</sup> Histopathological examination showed a dermal deposition of calcium salts (*figure 2*). These calcium deposits cause skin inflammation. Four different types of calcinosis cutis can be identified: dystrophic, metastatic, iatrogenic and idiopathic calcinosis.<sup>2</sup> Dystrophic calcinosis occurs in previously damaged tissue. Metastatic calcinosis develops as a result of hypercalcaemia or hyperphosphataemia caused by renal failure. Iatrogenic calcinosis includes calcinosis due to electromyographic or electroencephalographic electrode components; and after extravasation of intravenously applied calcium gluconate or calcium chloride.<sup>2</sup> The mechanism of

calcinosis cutis in the current case is multifactorial. Predisposing factors include high phosphate levels and renal failure around the period of the liver transplantation (metastatic). Precipitating factors include local trauma due to subcutaneous injections (dystrophic), and local elevation of calcium concentrations due to calcium salts contained in nadroparin (iatrogenic).<sup>3</sup> Calcinosis cutis due to, for example, subcutaneous morphine has not been reported until now, suggesting the calcium content of nadroparin plays an essential role in the pathogenesis. The combination of high calcium-phosphate levels including local deposition of calcium leads to an accumulation of the solubility product at the injection site.

Calcinosis cutis is a rare adverse reaction; however, because it is poorly recognised, the condition might be under-diagnosed. Treatment includes discontinuation of nadroparin. Generally, spontaneous recovery occurs in several weeks to months. In high-risk patients, such as in those with renal failure, the use of dalteparin, a non-calcium containing low-molecular-weight heparin, is advised.

Conclusion: calcinosis cutis due to calcium-containing low molecular weight heparin.

**Figure 2.** Calcinosis cutis: dermal deposition of calcium salts (\*), recognisable by the intense basophilic staining. Haematoxylin-eosin staining (x10)



## REFERENCES

1. Giorgini S, Martinelli C, Massi D, Lumini A, Mannucci M, Giglioli L. Iatrogenic calcinosis cutis following nadroparin injection. *Int J Dermatol*. 2005;44:855-7.
2. Eich D, Scharffetter-Kochanek K, Weihrauch J, Krieg T, Hunzelmann N. Calcinosis of the cutis and subcutis: an unusual nonimmunologic adverse reaction to subcutaneous injections of low-molecular-weight calcium-containing heparins. *J Am Acad Dermatol*. 2004;50:210-4.
3. van Haren FM, Ruiten DJ, Hilbrands LB. Nadroparin-induced Calcinosis cutis in renal transplant recipients. *Nephron*. 2001;87:279-82.