

# An unusual cause of hyperandrogenism

M. Wendker-van Wattum<sup>1</sup>, R.S.M.E. Wouters<sup>2</sup>, J.E. van der Wal<sup>3</sup>, A.W.J.M. Glaudemans<sup>4</sup>, B.H.R. Wolffenbuttel<sup>5\*</sup>

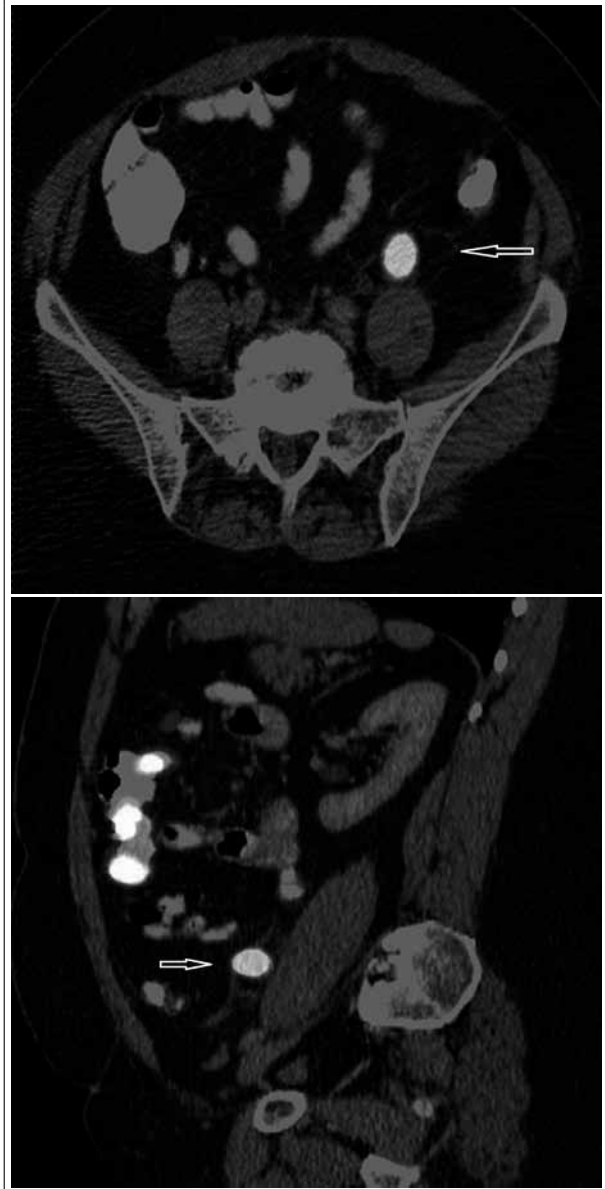
<sup>1</sup>Department of Internal Medicine, Deventer Hospital, the Netherlands, <sup>2</sup>Department of Internal Medicine, Scheper Hospital Emmen, the Netherlands, <sup>3</sup>Department of Pathology, University Medical Center Groningen and University of Groningen, Martini Hospital Groningen, the Netherlands, Departments of <sup>4</sup>Nuclear Medicine, <sup>5</sup>Endocrinology, University Medical Center Groningen and University of Groningen, the Netherlands, \*corresponding author: tel.: +31 (0)50 3613962, fax: +31 (0)50 3619392, e-mail: bwo@umcg.nl

## CASE REPORT

A 66-year-old woman was referred with complaints of increased libido and clitoral hypertrophy. Her medical history showed a caesarean section, and 19 years before, in 1992, she was diagnosed with cancer of the left breast (T<sub>3</sub>N<sub>3</sub>M<sub>0</sub> adenocarcinoma). For this she underwent mastectomy, followed by chemotherapy.

She complained of an increase in libido in the last 18 months as well as an increase in facial hair. She had noted clitoral hypertrophy, which had been present for 1.5 years. Physical examination revealed a masculine, overweight woman. The abdomen showed a few dark hairs on the linea alba, but no other signs of hirsutism. At inspection the clitoral hypertrophy was evident. Further physical examination was unremarkable. There were no clinical signs of Cushing's syndrome. Routine laboratory results were unremarkable. The specific laboratory results showed a serum testosterone level of 24.6 nmol/l (normal 0.2 to 3.0 nmol/l), dehydroepiandrosterone sulphate (DHEAS) of 2.9 µmol/l (normal 1.3 to 3.9 µmol/l) and androstenedione was 7.4 nmol/l (normal 0.0 to 5.4 nmol/l). Computed tomography of the abdomen showed no abnormalities in the adrenal region, but a 2 cm large lesion in the region of the left ovary was reported. Bilateral ovariectomy was advised and performed. The surgical procedure was uneventful, but the ovaries were not enlarged. Pathological examination showed normal ovarian tissue. After surgery, all clinical signs persisted and testosterone level remained elevated. Therefore additional investigations were performed. A five-day dexamethasone suppression test showed a cortisol suppression to <55 nmol/l, but no suppression of the androgens. Single photon emission computer tomography (SPECT) with <sup>131</sup>I-6β-iodomethyl-19-norcholesterol was performed, which revealed a lesion located in the mesosigmoid shown in figures 1 and 2.

**Figure 1 and 2.** Three days after injection of <sup>131</sup>I-6β-iodomethyl-19-norcholesterol there is a hotspot shown on the SPECT in the lower abdomen



## WHAT IS YOUR DIAGNOSIS?

See page 45 for the answer to this photo quiz.

## DISCUSSION

A SPECT with  $^{131}\text{I}$ -6 $\beta$ -iodomethyl-19-norcholesterol demonstrated a left-sided lesion, which appeared on the fusion CT to be located in the mesosigmoid, ventral of the iliopsoas muscle. The lesion was metabolically active, which was suggestive of ectopic steroid-producing tissue. After removal of this ectopic adenoma, all symptoms resolved and the androgen levels normalised. Pathological examination revealed that the lesion was an adenoma of ectopic adrenal tissue.

Virilising adrenal tumours are a rare cause of hyperandrogenism, and they are typically associated with high serum levels of DHEAS. However, testosterone-secreting adrenal adenomas with normal levels of DHEAS and androstenedione have been described in a few cases, showing a hormone profile that is similar to that of virilising ovarian tumours.<sup>1</sup>

Ectopic adrenal tissue is usually found in close proximity to the adrenal glands, and along the path of descent or in association with the gonads.<sup>2</sup> However, adrenal tissue has been found in other locations such as the liver, uterus, gallbladder and even the central nervous system, and usually produces cortisol.

To our knowledge there are two reported cases of strictly androgen-producing ectopic adrenal masses, one case localised in the thorax<sup>3</sup> and one case behind the iliopsoas muscle.<sup>4</sup> Initially the hormonal profile and CT scan suggested an ovarian origin. In this case a SPECT with  $^{131}\text{I}$ -6 $\beta$ -iodomethyl-19-norcholesterol revealed the real location. Therefore one should consider this investigation when the location of the androgen-producing tumour is unclear or when the ovaries are excluded from the differential diagnosis.

## REFERENCES

1. Ehrman DA. Hirsutism and virilisation. In: Fauci AS, Kasper DL, Longo DL, et al., editors. *Harrison's Principles of internal medicine*. 17th edition. New York, McGraw-Hill 2008.p. 301-4.
2. Soeverijns G, Peene P, Keuleers H, Vanbockrijk M. Ectopic localization of adrenal cortex. *Eur Radiol*. 2000;10:1165-8.
3. Medeiros LJ, anasti J, Gardner KL, Pass HI, Nieman LK. Virilizing adrenal cortical neoplasm arising ectopically in the thorax. *J Clin Endocrinol Metab*. 1992;75:1522-5.
4. Mavroudis K, Aloumanis K, Papapetrou PD, Voros D, Spanos I. Virilization caused by an ectopic adrenal tumor located behind the iliopsoas muscle. *Fertil Steril*. 2007; 87:1468.e13-6.